





# Visual dilation and curettage for the fertility-sparing treatment of atypical endometrial hyperplasia/endometrial intra-epithelial neoplasia: an easy to perform in-office technique

Paolo Casadio,<sup>1</sup> Antonio Raffone ,<sup>2,3</sup> Paolo Salucci ,<sup>3</sup> Diego Raimondo,<sup>1</sup> Renato Seracchioli,<sup>1,3</sup> Jose Carugno,<sup>4</sup> Attilio Di Spiezio Sardo<sup>2</sup>

For numbered affiliations see end of article.

## Correspondence to

Dr Paolo Salucci, Alma Mater Studiorum Università di Bologna, Bologna 40138, Italy; paolo.salucci@studio.unibo.it

Accepted 30 November 2022

Hysteroscopic endometrial resection when added to progestin therapy has been shown to improve the outcomes of fertility-sparing treatment in patients diagnosed with atypical endometrial hyperplasia/endometrial intra-epithelial neoplasia.<sup>1,2</sup> Unfortunately, with such a technique, the extension and depth of endometrium removal appears poorly reproducible. Moreover, the procedure must be performed in the operating room, and potential thermal damage of the specimen may affect its quality for histological examination.<sup>3</sup> Hysteroscopic tissue removal systems have shown greater safety and better outcomes for the length of the procedure, the learning curve, and successful complete removal of benign intrauterine pathology compared with resectoscopes.<sup>4</sup> However, further studies are needed to investigate the role of hysteroscopic tissue removal systems in patients

with malignant pathology. Hysteroscopic procedures, when performed in the office/outpatient setting, are cost-effective, with a low complication rate and high patient satisfaction.<sup>5</sup> However, their use in the fertility-sparing treatment of atypical endometrial hyperplasia/endometrial intra-epithelial neoplasia has never been described. The aim of this video article was to demonstrate the use of hysteroscopic tissue removal systems for the fertility-sparing treatment of patients with endometrial hyperplasia/endometrial intra-epithelial neoplasia.

We report the management of two women diagnosed with atypical endometrial hyperplasia/endometrial intra-epithelial neoplasia who expressed the desire to preserve fertility. After counseling, women opted for fertility-sparing treatment of the disease.

INTERNATIONAL JOURNAL OF  
**GYNECOLOGICAL CANCER**

**Visual Dilation & Curettage (D&C) for the fertility-sparing treatment of Atypical Endometrial Hyperplasia/ Endometrial Intraepithelial Neoplasia: An easy to perform in office technique**

Paolo Casadio, MD<sup>1</sup>; Antonio Raffone, MD<sup>1,2</sup>; Paolo Salucci, MD<sup>2</sup>; Diego Raimondo, MD, PhD<sup>1</sup>; Renato Seracchioli, MD, PhD<sup>1,2</sup>; Jose Carugno, MD<sup>3</sup>; Attilio Di Spiezio Sardo, MD, PhD<sup>4</sup>

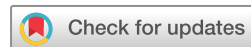

<sup>1</sup> Division of Gynaecology and Human Reproduction Physiopathology, IRCCS Azienda Ospedaliero-Universitaria di Bologna, Bologna, Italy  
<sup>2</sup> Department of Medical and Surgical Sciences (DIMEC), University of Bologna, Bologna, Italy  
<sup>3</sup> Obstetrics, Gynecology and Reproductive Sciences Department, Minimally Invasive Gynecology Division, University of Miami, Miami, FL, USA  
<sup>4</sup> Gynecology and Obstetrics Unit, Department of Neuroscience, Reproductive Sciences and Dentistry, School of Medicine, University of Naples Federico II, Naples, Italy

 @IJGOnline

Copyright © 2020 BMJ Publishing Group Ltd, International Gynecologic Cancer Society, & European Society of Gynecological Oncology. All rights reserved.

**Video 1** Hysteroscopic endometrial resection using a hysteroscopic tissue removal system



© IGCS and ESGO 2022. No commercial re-use. See rights and permissions. Published by BMJ.

**To cite:** Casadio P, Raffone A, Salucci P, *et al.* *Int J Gynecol Cancer* Published Online First: [please include Day Month Year]. doi:10.1136/ijgc-2022-003877

## Video article

Fertility-sparing treatment was performed in the office setting and consisted of hysteroscopic endometrial resection using a hysteroscopic tissue removal system, followed by immediate insertion of a 52 mg levonorgestrel-releasing intrauterine device. The total procedure time (endometrial resection and intrauterine device insertion) ranged from 10 to 13 min. The women were closely followed up every 3 months with endometrial biopsy to assess the response to treatment.

A hysteroscopic tissue removal system allowed us to perform hysteroscopic endometrial resection in an-office setting. Its use is a safe and feasible in-office/outpatient alternative for the fertility-sparing treatment of women diagnosed with atypical endometrial hyperplasia/endometrial intra-epithelial neoplasia. However, further studies are needed to investigate the safety of using hysteroscopic tissue removal systems for the treatment of uterine pre-malignant or malignant pathology.

### Author affiliations

<sup>1</sup>Division of Gynaecology and Human Reproduction Physiopathology, IRCCS Azienda Ospedaliero-Universitaria di Bologna, Bologna, Emilia-Romagna, Italy

<sup>2</sup>Gynecology and Obstetrics Unit, Department of Neuroscience, Reproductive Sciences and Dentistry, School of Medicine, University of Naples Federico II, Napoli, Campania, Italy

<sup>3</sup>Department of Medical and Surgical Sciences (DIMEC), Alma Mater Studiorum, Università di Bologna, Bologna, Emilia-Romagna, Italy

<sup>4</sup>Department of Gynecology and Reproductive Sciences, Minimally Invasive Gynecology Division, University of Miami, Miller School of Medicine, Miami, Florida, USA

**Contributors** PC: guarantor, conceptualization and surgery. AR: manuscript preparation. PS: video editing and manuscript preparation. DR: reviewing and editing. RS: supervision, editing, and reviewing. JC: audio narration, reviewing, and editing. ADSS: supervision and surgery.

**Funding** The authors have not declared a specific grant for this research from any funding agency in the public, commercial or not-for-profit sectors.

**Competing interests** None declared.

**Patient consent for publication** Not applicable.

**Provenance and peer review** Not commissioned; externally peer reviewed.

**Data availability statement** All data relevant to the study are included in the article.

### ORCID iDs

Antonio Raffone <http://orcid.org/0000-0001-5443-2333>

Paolo Salucci <http://orcid.org/0000-0002-9015-9722>

## REFERENCES

- 1 Uterine neoplasms NCCN guidelines version 1.2022. Available: <https://www.nccn.org/guidelines/guidelines-detail?category=1&id=1473> [Accessed 2 Oct 2022].
- 2 Lucchini SM, Esteban A, Nigra MA, *et al.* Updates on conservative management of endometrial cancer in patients younger than 45 years. *Gynecol Oncol* 2021;161:802–9.
- 3 Franchini M, Zolfanelli F, Gallorini M, *et al.* Hysteroscopic polypectomy in an office setting: specimen quality assessment for histopathological evaluation. *Eur J Obstet Gynecol Reprod Biol* 2015;189:64–7.
- 4 Shazly SAM, Laughlin-Tommaso SK, Breitkopf DM, *et al.* Hysteroscopic morcellation versus resection for the treatment of uterine cavity lesions: a systematic review and meta-analysis. *J Minim Invasive Gynecol* 2016;23:867–77.
- 5 Carugno J, Grimbizis G, Franchini M. International consensus statement for recommended terminology describing hysteroscopic procedures. *J Minim Invasive Gynecol* 2021;13:287–94.