



OPEN ACCESS

Obstetrics and Gynecology Hospital of Fudan University, Shanghai, Shanghai, China

Correspondence to

Dr Liangqing Yao, Obstetrics and Gynecology Hospital of Fudan University, Shanghai, Shanghai, China; yaoliangqing@163.com

Accepted 20 June 2022

Retrograde hysterectomy approach in a patient with a frozen pelvis due to a suspected ovarian malignancy

Xuhui Dong , Lei Yuan, Liangqing Yao 

Surgical treatment of gynecological disease with colorectal involvement is a challenge which requires complete surgical excision of lesions.¹ Blind blunt dissection of the Douglas pouch might cause massive and rectal tissue damage.^{2,3} Traditional hysterectomy may cause rectal injury for those cases with severe adhesion in the Douglas pouch.⁴ Retrograde hysterectomy has usually been applied in laparoscopic assisted vaginal surgery. However, are case demonstrated retrograde laparoscopic hysterectomy for a patient with severe adhesion in the Douglas pouch.

Method: A step-by-step video demonstration of the technique

Result: A 53-year-old woman with a history of dysmenorrhea had abdominal distention for 2 months. PET-CT showed that the uptake of fluorodeoxyglucose in the surrounding peripheral rim of soft tissue masses was elevated. Laparoscopy showed severe adhesions in the pelvic cavity, which might be caused by malignant tumor and endometriosis. It is difficult to

expose the Douglas pouch due to the dense adhesions with poorly defined margins posteriorly to the uterus. Therefore, the surgeon decided to open the Douglas pouch finally. After coagulating the ligaments, pushing the bladder, and incising the vaginal wall, the outline and margin of the lesion was exposed so that the lesion could be cut off safely. Omentectomy, appendectomy, partial peritonectomy, pelvic and para-aortic lymph node resection were performed. The neoplasm in the right ovarian cyst was clear cell carcinoma, and the lesion on the surface of the rectum was endometriosis. The patient recovered well without any complications and defecated 3 days after surgery. She is still alive up to now.

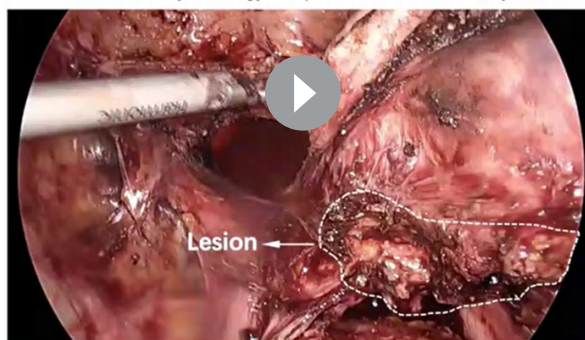
Conclusion: Our video showed that a flexible change in laparoscopic surgical procedures could overcome difficulty safely and quickly. Compared with the traditional type, retrograde hysterectomy can recognize the margin of a lesion, and is a safe alternative for patients with dense adhesion around the uterus.

INTERNATIONAL JOURNAL OF
GYNECOLOGICAL CANCER

Retrograde Hysterectomy approach in a patient with a frozen pelvis due to a suspected ovarian malignancy

Xuhui Dong, Lei Yuan, Liangqing Yao

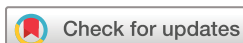Obstetrics and Gynecology Hospital of Fudan University, China



@IJGConline

Copyright © 2020 BMJ Publishing Group Ltd, International Gynecological Cancer Society, & European Society of Gynaecological Oncology. All rights reserved.

Video 1 Retrograde hysterectomy approach in a patient with a frozen pelvis due to a suspected ovarian malignancy



© IGCS and ESGO 2022.
Re-use permitted under CC BY.
Published by BMJ.

To cite: Dong X, Yuan L, Yao L.
Int J Gynecol Cancer Published
Online First: [please include
Day Month Year]. doi:10.1136/
ijgc-2022-003363

Video article

Contributors XD: data collection and video editing, reviewing the literature, drafting and revising the manuscript; LY: revision of the manuscript; LY: patient's overall management, final approval of the version to be submitted and critical review of the manuscript. All authors read and approved the final manuscript.

Funding The authors have not declared a specific grant for this research from any funding agency in the public, commercial or not-for-profit sectors.

Competing interests None declared.

Patient consent for publication Consent obtained directly from patient(s)

Ethics approval This study involves human participants but the ethics committee of the Obstetrics and Gynecology Hospital of Fudan University exempted this study. Participants gave informed consent to participate in the study before taking part.

Provenance and peer review Not commissioned; externally peer reviewed.

Data availability statement All data relevant to the study are included in the article.

Open access This is an open access article distributed in accordance with the Creative Commons Attribution 4.0 Unported (CC BY 4.0) license, which permits others to copy, redistribute, remix, transform and build upon this work for any purpose, provided the original work is properly cited, a link to the licence is given,

and indication of whether changes were made. See: <https://creativecommons.org/licenses/by/4.0/>.

ORCID iDs

Xuhui Dong <http://orcid.org/0000-0002-4675-0945>

Liangqing Yao <http://orcid.org/0000-0002-4400-245X>

REFERENCES

- 1 Yoriki K, Kusuki I, Kawamata M, *et al.* Successful detection of rectal injury during laparoscopic surgery using a rectal probe in a patient with deep endometriosis. *J Obstet Gynaecol Res* 2021;47:425–9.
- 2 Volpi E, Bernardini L, Angeloni M, *et al.* Retroperitoneal and retrograde total laparoscopic hysterectomy as a standard treatment in a community hospital. *Eur J Obstet Gynecol Reprod Biol* 2014;172:97–101.
- 3 Litta P, Saccardi C, Conte L, *et al.* Reverse hysterectomy: another technique for performing a laparoscopic hysterectomy. *J Minim Invasive Gynecol* 2013;20:631–6.
- 4 Cho F-N. A technique to deal with severe adhesions between the uterus and bladder or rectum in laparoscopic-assisted vaginal hysterectomy. *J Minim Invasive Gynecol* 2007;14:750–1.