



Treatment of hydatidiform mole using manual vacuum aspiration: technical and tactical aspects

Antonio Braga ^{1,2}, Lilian Padrón,³ Jorge Rezende-Filho,¹ Kevin Elias,⁴ Neil Horowitz,⁴ Ross Berkowitz⁴

► Additional supplemental material is published online only. To view, please visit the journal online (<http://dx.doi.org/10.1136/ijgc-2021-002631>).

¹Department of Obstetrics and Gynecology, Federal University of Rio de Janeiro, Rio de Janeiro, Rio de Janeiro, Brazil

²Department Maternal Child, Federal Fluminense University, Niterói, Rio de Janeiro, Brazil

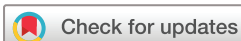³Gynecology Institute, Federal University of Rio de Janeiro, Rio de Janeiro, Brazil

⁴Department of Obstetrics and Gynecology, Division of Gynecologic Oncology, Brigham and Women's Hospital, Harvard Medical School, Boston, Massachusetts, USA

Correspondence to

Dr Antonio Braga, Obstetrics and Gynecology, Federal University of Rio de Janeiro, Rio de Janeiro 22240-003, Brazil; bragamed@yahoo.com.br

Accepted 26 April 2021



© IGCS and ESGO 2021. No commercial re-use. See rights and permissions. Published by BMJ.

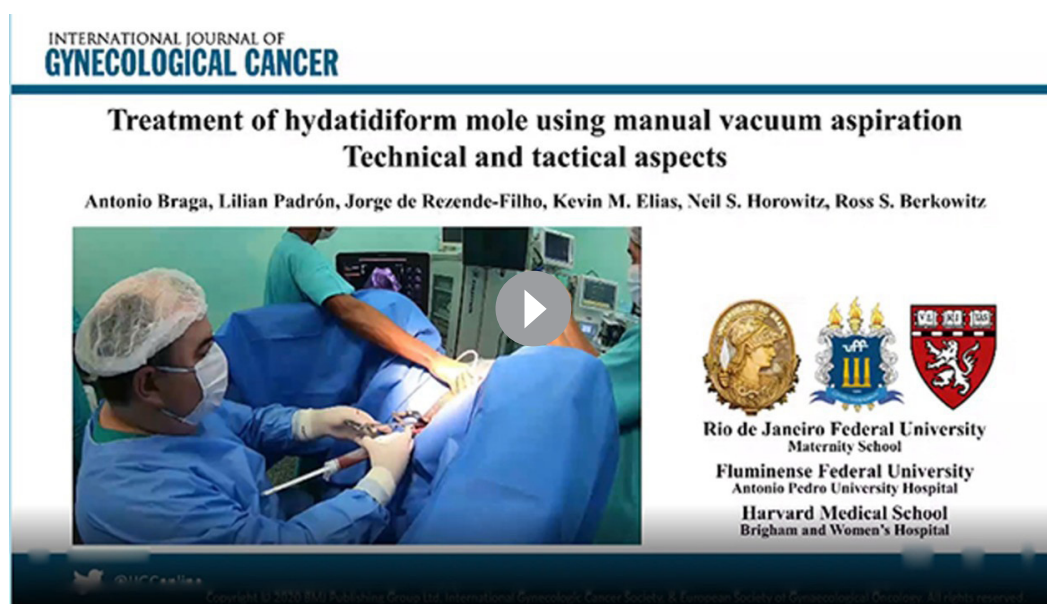
To cite: Braga A, Padrón L, Rezende-Filho J, *et al.* *Int J Gynecol Cancer* Published Online First: [please include Day Month Year]. doi:10.1136/ijgc-2021-002631

Hydatidiform mole (HM) represents the benign spectrum of gestational trophoblastic disease (GTD), an abnormal pregnancy characterized by aberrant fertilization of the oocyte.¹ The treatment of HM is uterine evacuation, usually done through electric vacuum aspiration (EVA). However, numerous conditions—including legal, religious, and economic—prevent several countries from having access to the devices used to perform EVA. In Brazil the vast majority of GTD Reference Centers do not have EVA, so more than 70% of HMs are treated with manual vacuum aspiration (MVA).² The aim of this video article is to present a representative case where MVA is used for evacuation of HM (Video 1).

After approval by the Rio de Janeiro Federal University Institutional Review Board in February 2021 (number: 4.555.188) and obtaining written informed consent from the patient, we describe a case of a

patient at 12 weeks gestation who was referred to our institution due to bleeding, uterus larger than gestational age, human chorionic gonadotropin of 178 678 IU/L, and ultrasonography suggesting HM. She underwent uterine MVA for the treatment of a molar pregnancy.

In the video we show the MVA technique for the treatment of HM, as well as strategies to make the surgery safer and more effective (see also online supplemental tables 1 and 2). There are two important tips for performing molar MVA: the first is to have two aspiration syringes, which makes the procedure more efficient, and the second is to perform cervical dilation with the plastic cannulas themselves, minimizing the risk of perforation.³ Ultrasonography guidance during the procedure assists in monitoring uterine evacuation, avoiding uterine perforation, and helping to ensure complete



Video 1 Uterine evacuation by manual vacuum aspiration guided by ultrasonography for the treatment of hydatidiform mole. This video shows that manual vacuum aspiration can replace electric vacuum aspiration in settings that do not have electrical equipment for molar evacuation. This simple, effective, and inexpensive method can be a safe alternative for uterine evacuation in cases of hydatidiform mole.

Video article

evacuation. When the contents of the syringe become pink and bullous, it is a sign that the uterine cavity is empty.⁴ A gentle uterine sharp curettage after molar evacuation is important to remove any adherent trophoblastic tissue remnants.

Twitter Antonio Braga @BragaDTG

Contributors AB: Surgeon, development of paper, review of the literature. LP: Surgeon, development of paper, review of the literature. JR-F: Ultrasonographer, development and review of paper. KE, NH, RB: Development and review of paper. All authors approved the final version.

Funding This research was supported by the National Council for Scientific and Technological Development – CNPq (AB), Donald P. Goldstein MD Trophoblastic Tumor Registry Endowment and the Dyett Family Trophoblastic Disease Research and Registry Endowment (KME, NSH, RSB).

Competing interests None declared.

Patient consent for publication Not required.

Provenance and peer review Not commissioned; externally peer reviewed.

Data availability statement All data relevant to the study are included in the article or uploaded as supplementary information.

Supplemental material This content has been supplied by the author(s). It has not been vetted by BMJ Publishing Group Limited (BMJ) and may not have been peer-reviewed. Any opinions or recommendations discussed are solely

those of the author(s) and are not endorsed by BMJ. BMJ disclaims all liability and responsibility arising from any reliance placed on the content. Where the content includes any translated material, BMJ does not warrant the accuracy and reliability of the translations (including but not limited to local regulations, clinical guidelines, terminology, drug names and drug dosages), and is not responsible for any error and/or omissions arising from translation and adaptation or otherwise.

ORCID iD

Antonio Braga <http://orcid.org/0000-0002-2942-6182>

REFERENCES

- 1 Elias KM, Berkowitz RS, Horowitz NS. State-Of-The-Art workup and initial management of newly diagnosed molar pregnancy and postmolar gestational trophoblastic neoplasia. *J Natl Compr Canc Netw* 2019;17:1396–401.
- 2 Braga A, Moraes V, Maestá I, *et al.* Changing trends in the clinical presentation and management of complete hydatidiform mole among Brazilian women. *Int J Gynecol Cancer* 2016;26:984–90.
- 3 Padrón L, Rezende Filho J, Amim Junior J, *et al.* Manual compared with electric vacuum aspiration for treatment of molar pregnancy. *Obstet Gynecol* 2018;131:652–9.
- 4 Braga A, Padrón L, Balen JL. Video hysteroscopy in the diagnosis of molar pregnancy in two challenging situations: complete mole with normal hCG and partial mole with early gestational age. *J Minim Invasive Gynecol* 2021;S1553-4650:00081–9.

Supplemental Table 1. Specific material needed to perform a uterine manual vacuum aspiration for treatment of hydatidiform mole.

Material	Function
Gauze and surgical dressing	Used for both antisepsis and cervical hemostasis
Cheron dressing forceps (1 unit)	Used for external and internal genital antisepsis
Surgical bowl (1 unit)	Used to store chlorhexidine for antisepsis
Kidney dish (2 unit)	Used to receive material aspirated from the uterus by the syringe
Vaginal speculum (1 unit)	Used to visualize access to the uterus via the cervical canal
Pozzi uterine tenaculum forceps (1 unit)	Used to provide traction of the cervix, rectifying the uterus and minimizing the chance of uterine perforation
Intrauterine suction cannula (1 unit for each number from 4 until 12)	Used both for cervical dilation and for accessing intrauterine content
Syringe (2 units)	Used to promote negative pressure and aspirate intrauterine content and store it during the procedure
Sharp uterine curette (1 unit)	Used to gently curette the endometrial cavity at the end of the manual vacuum aspiration

Supplemental Table 2. Summary of tips for carrying out a uterine manual vacuum aspiration for treatment of hydatidiform mole.

Strategy	Execution
Routine preoperative exams	Request blood type and complete blood cell counts, basic chemistry, hepatic and thyroid panels, urinalysis, serum hCG level (for patients with a uterus larger than 20 cm measured suprapubic–fundus on physical examination, thyroid-stimulating hormone, free thyroxine, electrocardiogram and chest x-ray are also requested)
Blood reserve	We recommend reserving 2 packed red blood cell
Prophylactic antibiotic therapy	We do not recommend
Cervical preparation and uterotonic infusion	We not routinely use cervical preparation with prostaglandin or oxytocin during the procedure to avoid the risk of trophoblastic embolization. We exclusively reserve its use in cases of hemorrhage prior to or during surgery
Anesthetic care	Total intravenous anesthesia with a propofol infusion and fentanyl boluses as needed. Although anesthetic drugs (neuroleptics) or paracervical anesthetic block are allowed, we only recommend general anesthesia in a surgical center for treatment of molar pregnancy using manual vacuum aspiration due to the higher risk of bleeding during the procedure, even in cases of non-enlarged uteri for gestational age
Cervical dilation	We use suction cannulas to promote cervical dilation. Its plastic and flexible structure minimizes the risks of uterine perforation
Intraoperative ultrasonography	Important to confirm the suspicion of molar pregnancy, predict the progression of molar pregnancy into gestational trophoblastic neoplasia evaluating Doppler velocimetry of the uterine arteries and help guides the surgical procedure
Suction cannula	Cervical dilation should begin with a cannula number 4 and proceed to cannula number 7 for uteri smaller than 12 centimeters, leaving cannulas 8 (or exceptionally 10) for uteri enlarger than gestational age. As the uterine volume decreases during the evacuation, we find it prudent to change the cannula to a smaller size in order to access all portions of the uterus
Uterine evacuation	The use of two aspiration syringes makes the procedure more efficient. Once the syringe is filled, it should be removed from the uterus, delivered to the assistant, who returns a new empty vacuum syringe to the surgeon, which will be attached to the cannula for further uterine evacuation. In the meantime, the assistant empties the uterine contents of the syringe and prepares it, with vacuum, for the next evacuation cycle
End of procedure	When the contents collected in the syringe becomes pink and bullous, it is a sign that the uterine cavity is empty
Sharp curettage	After the end of molar evacuation, about 15% of patients may still have molar tissue in the endometrial cavity. We therefore perform a gentle sharp curettage to remove any adherent trophoblastic remnants and avoid the need for a second uterine evacuation
Macroscopic evaluation and preparation for pathology	After the procedure, the surgeon should wash the molar material with saline, taking care to remove blood clots. The tissue should be packed in 10% buffered formaldehyde
Postoperative guide	Use usual analgesics and anti-spasmodics. Assess the need for specific treatment (such as the use of anti-emetics). Use anti-D immunoglobulin in RhD-

	negative patients. Monitor vital signs. Guide effective contraception. Discharge can be given in 12-24h, depending on the clinical conditions
Postmolar follow-up	Do not wait for the histopathology result to refer the patient to the Gestational Trophoblastic Disease Reference Center, if the macroscopy is suggestive of hydatidiform mole