

Persistent postoperative ascites successfully identified and treated with laparoscopic indocyanine green fluorescence

Rodrigo Fernandes ¹, Cristina Anton ¹, Andre Lopes ¹, Alexandre Silva e Silva,¹ Eric Leblanc,² Ulysses Ribeiro Jr,³ Jesus Paula Carvalho ¹

¹Obstetria e Ginecologia, Universidade de Sao Paulo Instituto do Cancer do Estado de Sao Paulo, Sao Paulo, Brazil
²Gynecology Oncology, Oscar Lambret Cancer Centre, Lille, Hauts-de-France, France
³Gastroenterologia, Universidade de Sao Paulo Instituto do Cancer do Estado de Sao Paulo, Sao Paulo, São Paulo, Brazil

Correspondence to

Rodrigo Fernandes, Obstetria e Ginecologia, Universidade de Sao Paulo Instituto do Cancer do Estado de Sao Paulo, Sao Paulo, Brazil; roffernandes@gmail.com

Accepted 30 April 2020

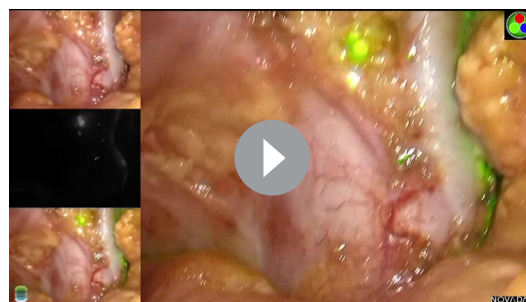
Lymphatic ascites after a lymphadenectomy due to disruption of lymphatic vessels is a complication reported to happen in 2.7% of those procedures.^{1–3}

There are several types of lymphatic leakage reported in the literature such as lymphorrhea, lymphocele, lymphatic ascites, chylous ascites, and lymphatic fistula. Medical treatment is the primary treatment of choice and has been reported to cure ascites in 66% to 77% of cases.¹ Surgical treatment to identify the leakage site should not be considered as the first choice and is reserved if medical treatment fails to solve it.¹⁴ Indocyanine green (ICG) and fluorescence imaging (FI) have been vastly used for different purposes including sentinel lymph node identification for different types of cancer, retina evaluation, and organ perfusion before resection. In addition, ICG and FI have potential to solve contemporary problems in gynecologic oncology and may be used to evaluate perfusion of colorectal anastomosis or uterine perfusion after radical trachelectomy.^{5,6} In this video we present a case where ICG and FI were used to help identify the precise site of lymphatic leakage and successfully solve it. Different from previous authors who published ICG interdigital foot injection, we demonstrate an alternative application at the proximal part of the thigh.⁷

A 59-year-old woman diagnosed with high-grade serous ovarian carcinoma FIGO stage IIIC, underwent upfront debulking surgery with total hysterectomy, bilateral adnexectomy, omentectomy, and partial lymphadenectomy in another hospital.

The patient was referred to our institution and underwent six cycles of chemotherapy with carboplatin-paclitaxel, however she persisted with enlarged pelvic and para-aortic lymph nodes, suspicious for secondary involvement without any other sites of metastasis. We decided to perform systematic pelvic and para-aortic lymphadenectomy. A few days after the surgery the patient developed ascites confirmed by the clinical aspect and biochemical evaluation of the fluid.

Conservative treatment consisting of parental nutrition, a low-fat diet with medium-chain



Video 1.

triglycerides, and several percutaneous drainages were unsuccessful. Then we decided to perform laparoscopy, ICG, and FI to fix the leakage.

During the procedure 1.2 liters of lymphatic ascites were drained. An injection of 1 mL of ICG in three sites of the proximal part of both thighs was performed and after 10 min the use of near infrared fluorescence successfully identified the active leakage site. Several metal clips were used to stop the leakage.

After surgery the patient was discharged with no further complications. Long-term follow-up demonstrated no more ascites.

The use of laparoscopy and ICG subcutaneous injection appears as a promising technique to identify active lymphatic leakage and treat it surgically. The injection of ICG to the thigh appears to be an alternative to interdigital foot injection.

Twitter Andre Lopes @Andrelopes1002

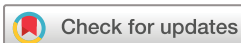Contributors RPF (corresponding author): Surgeon, development of paper, review of the literature. CA: Surgeon, development of paper, review of the literature. AL: Development of paper. UR: Review of paper. EL: Development and review of paper. JPC: Development and review of paper.

Funding The authors have not declared a specific grant for this research from any funding agency in the public, commercial, or not-for-profit sectors.

Competing interests None declared.

Patient consent for publication Not required.

Provenance and peer review Not commissioned; externally peer reviewed.



© IGCS and ESGO 2020. No commercial re-use. See rights and permissions. Published by BMJ.

To cite: Fernandes R, Anton C, Lopes A, et al. *Int J Gynecol Cancer* Published Online First: [please include Day Month Year]. doi:10.1136/ijgc-2020-001198

Video article

Data availability statement Data are available in a public, open access repository

ORCID iDs

Rodrigo Fernandes <http://orcid.org/0000-0002-5264-2166>

Cristina Anton <http://orcid.org/0000-0002-6259-2449>

Andre Lopes <http://orcid.org/0000-0002-4986-8738>

Jesus Paula Carvalho <http://orcid.org/0000-0003-4495-057X>

REFERENCES

- 1 Lv S, Wang Q, Zhao W, *et al.* A review of the postoperative lymphatic leakage. *Oncotarget* 2017;8:69062–75.
- 2 Frey MK, Ward NM, Caputo TA, *et al.* Lymphatic ascites following pelvic and paraaortic lymphadenectomy procedures for gynecologic malignancies. *Gynecol Oncol* 2012;125:48–53.
- 3 Cartron G, Leblanc E, Ferron G, *et al.* Complications des lymphadénectomies coelioscopiques en oncologie gynécologique : 1102 interventions chez 915 patientes. *Gynécologie Obstétrique & Fertilité* 2005;33:304–14.
- 4 Micha JP, Mendivil AA, Cupp JS, *et al.* Recurrent lymphatic ascites in a patient cured of cervical carcinoma. *Gynecol Oncol Case Rep* 2012;2:105–6.
- 5 Escobar PF, Ramirez PT, Garcia Ocasio RE, *et al.* Utility of indocyanine green (ICG) intra-operative angiography to determine uterine vascular perfusion at the time of radical trachelectomy. *Gynecol Oncol* 2016;143:357–61.
- 6 Alekseev M, Rybakov E, Shelygin Y, *et al.* A study investigating the perfusion of colorectal anastomoses using fluorescence angiography: results of the FLAG randomized trial. *Colorectal Dis* 2020. doi:10.1111/codi.15037. [Epub ahead of print: 18 Mar 2020].
- 7 Papadia A, Imboden S, Mohr S, *et al.* Indocyanine green fluorescence imaging in the surgical management of an iatrogenic lymphatic fistula: description of a surgical technique. *J Minim Invasive Gynecol* 2015;22:1304–6.