



Perineal resection and anorectal amputation with perforator flap reconstruction by a dorsal approach in prone Jackknife position

Carlos Martínez-Gómez ^{1,2}, Martina Aida Angeles,¹ Alejandra Martínez ^{1,2}, Thomas Meresse,³ Dimitri Gangloff,³ Gwenael Ferron^{1,4}

¹Department of Surgical Oncology, Institut Universitaire de Cancer de Toulouse, Institut Universitaire du Cancer de Toulouse - Oncopole, Toulouse, France

²CRCT Team 1 - Tumor Immunology and Immunotherapy, INSERM, Toulouse, France

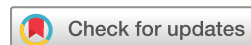³Plastic and Reconstructive Surgery, Institut Universitaire du Cancer de Toulouse, Toulouse, France

⁴CRCT 19 - Oncosarc - Oncogenesis of Sarcomas, INSERM, Toulouse, France

Correspondence to

Dr Gwenael Ferron, Department of Surgical Oncology, Institut Claudius Regaud, Institut Universitaire du Cancer de Toulouse, Oncopole, 1 Avenue Irène Joliot-Curie31059, Toulouse, Cedex 9, France; ferron.gwenael@iuct-oncopole.fr

Accepted 30 April 2020



© IGCS and ESGO 2020. No commercial re-use. See rights and permissions. Published by BMJ.

To cite: Martínez-Gómez C, Angeles MA, Martínez A, *et al.* *Int J Gynecol Cancer* Published Online First: [please include Day Month Year]. doi:10.1136/ijgc-2020-001423

ABSTRACT

Some gynecological malignancies, such as vulvar or vaginal cancer, can present a local extension to the anus or rectum due to their close anatomical relationship. The frontline treatment in the case of locally advanced vulvar cancer should be chemoradiotherapy rather than mutilant surgery.¹ However, in the case of residual disease or relapse, a perineal excision, including a low anterior anorectal resection, remains the only salvage treatment.² While in some anorectal cancers the anal sphincter can be spared and, therefore, fecal continence is preserved, in locally advanced vulvovaginal cancers, the sphincter is frequently either invaded by the tumor or needs to be removed to obtain free margins. These patients require a permanent colostomy, which may be performed before chemoradiotherapy or at the same time of perineal resection.

Our aim is to illustrate the feasibility of both perineal resection and reconstruction in the jackknife/Kraske position, a variation of the prone position, in which the hips are more elevated than the head and the feet.³

We present the case of a 48-year-old woman referred to our center for an isolated perineal relapse of a locally advanced squamous vulvar cancer. At diagnosis, a permanent loop sigmoid colostomy was performed due to rectal invasion. She was treated with exclusive concomitant chemoradiotherapy.¹

This multidisciplinary approach starts by Doppler ultrasound identification of the perforator vessels and the cutaneous delimitation of the flap. During the first part of the procedure, an en-bloc resection of the anus, rectum, right major labia, posterior vaginal wall, and central tendinous point of the perineum was performed. A running suture was done to invaginate the neoplastic tissue to avoid tumor spillage. Then a pedicled inferior gluteal artery perforator flap was performed (Video 1).⁴

The final anatomopathological analysis reported a 4-cm well differentiated squamous vulvar cancer relapse with free margins. The tumor was 2 mm from the rectal mucosa. Eight weeks after operation, two

small areas of flap dehiscence were managed by home care nursing.

In conclusion, prone jackknife/Kraske positioning provides an excellent surgical field exposure which is useful for tumor resection and gluteal perforator flap reconstruction in the case of vulvovaginal cancers presenting with anorectal involvement.

Twitter Martina Aida Angeles @AngelesFite and Alejandra Martínez @Alejandra

Contributors CM-G: conceptualization, video editing, and writing the original draft. MAA: conceptualization, video editing, and writing the original draft. AM: conceptualization, project administration, supervision, and writing review. DG: conceptualization, project administration, supervision, and writing review. TM: conceptualization, project administration, supervision, and writing review. GF: conceptualization, project administration, surgery and video recording, supervision, and writing review.

Funding The authors have not declared a specific grant for this research from any funding agency in the public, commercial, or not-for-profit sectors.

Competing interests GF reports personal fees from Olympus outside of the submitted work.

Patient consent for publication Not required.

Provenance and peer review Not commissioned; externally peer reviewed.

Data availability statement All data relevant to the study are included in the article.

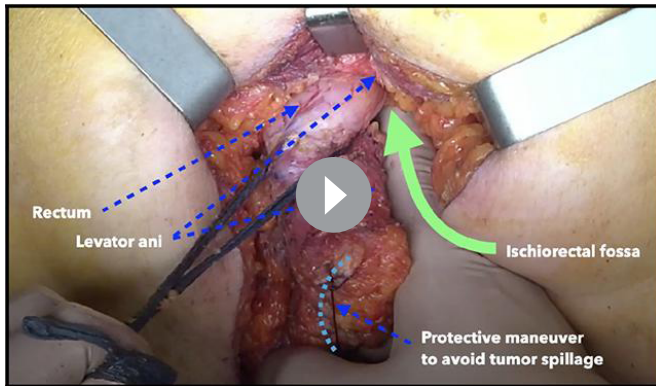
ORCID iDs

Carlos Martínez-Gómez <http://orcid.org/0000-0002-9652-7880>
Alejandra Martínez <http://orcid.org/0000-0002-7633-3536>

REFERENCES

- Moore DH, Ali S, Koh W-J, *et al.* A phase II trial of radiation therapy and weekly cisplatin chemotherapy for the treatment of locally-advanced squamous cell carcinoma of the vulva: a Gynecologic Oncology Group Study. *Gynecol Oncol* 2012;124:529–33.
- Hagemans JAW, Blinde SE, Nuytens JJ, *et al.* Salvage abdominoperineal resection for squamous cell anal cancer: a 30-year single-institution experience. *Ann Surg Oncol* 2018;25:1970–9.
- McKechnie T, Lee Y, Springer JE, *et al.* Prone compared with lithotomy for abdominoperineal resection: a systematic review and meta-analysis. *J Surg Res* 2019;243:469–80.
- Devulapalli C, Jia Wei AT, DiBiagio JR, *et al.* Primary versus flap closure of perineal defects following

Video article



Video 1 Perineal resection and anorectal amputation with perforator flap reconstruction in prone position

oncologic resection: a systematic review and meta-analysis. *Plast Reconstr Surg* 2016;137:1602–13.