

# Sentinel lymph node in apparent early ovarian cancer: open technique

Victor Lago,<sup>1</sup> Pilar Bello,<sup>2</sup> María Tiermes Marina Martín,<sup>1</sup> Beatriz Montero,<sup>3</sup> Pablo Padilla-Iserte,<sup>1</sup> Susana Lopez,<sup>3</sup> Luis Matute,<sup>1</sup> Santiago Domingo<sup>1</sup>

► This video is too large to play in the PDF, please visit the full text version online at: <https://ijgc.bmj.com/content/10.1136/ijgc-2019-000732>.

<sup>1</sup>Gynecologic Oncology Department, University Hospital La Fe, Valencia, Spain

<sup>2</sup>Nuclear Medicine Department, University Hospital La Fe, Valencia, Spain

<sup>3</sup>Pathology Department, University Hospital La Fe, Valencia, Spain

## Correspondence to

Dr Victor Lago, University Hospital La Fe, Valencia 46026, Spain; victor.lago.leal@hotmail.com

Accepted 18 September 2019

In apparent early stage ovarian cancer, complete surgical staging surgery including systematic lymphadenectomy is recommended at the time of diagnosis. Although minimally invasive surgery can be carried out for re-staging, laparotomy is the standard surgical approach recommendation to treat and stage patients with apparent early stage ovarian cancer.<sup>1</sup> After complete staging surgery, approximately 14% of the patients are upstaged due to positive lymph nodes.<sup>2</sup> Nevertheless, low grade carcinomas may present a lower rate of lymph node involvement.<sup>3</sup> The sentinel lymph node technique has been reported to be feasible in a recent pilot study.<sup>4</sup> In an attempt to avoid the potential drawbacks of lymphadenectomy, two clinical trials (SENTOV and SELLY) are currently ongoing to clarify the use of the sentinel lymph node technique in early ovarian cancer.

Video 1 explains step-by-step the sentinel lymph node procedure in a patient diagnosed with a suspicious adnexal mass. Exploratory laparotomy and adnexectomy, followed by frozen section, were performed. The intra-operative pathology examination confirmed a carcinoma. For sentinel lymph node detection, a combination of two methods was used: technetium-99m nanocolloid and indocyanine green. The injection points were at the infundibulopelvic and ovarian ligament stumps. We injected subperitoneally 0.2 mL of saline solution containing 37 MBq of technetium-99m nanocolloid followed by 0.5 mL of indocyanine green. We used a 27 G needle at each injection point. After a minimum of 15 min, the operative field

was checked with an intra-operative mobile gamma camera for descriptive purposes only. Guided by the acoustic signal of the gamma probe and a near-infrared camera, we performed a minimum dissection looking for the sentinel lymph node or nodes in the pelvic and para-aortic region. Any lymph node with a remarkable radioactivity count higher than 10 times the background and dyed with indocyanine green was considered a sentinel lymph node and was harvested separately. A systematic surgical staging was performed after the sentinel lymph node procedure was accomplished. Between 2017 and 2019, this procedure was performed in 30 patients, in the context of our pilot experience<sup>4</sup> and the clinical trial SENTOV (NCT03452982).

**Twitter** María Tiermes Marina Martín @Tiermes

**Contributors** VL: conceptualization, project administration, surgery, video editing, writing the original draft. PB: conceptualization, review of draft. MTMM: video recording and surgery. BM: conceptualization, review of draft. PPI: conceptualization, surgery and review of draft. SL: conceptualization, review of draft. LM: conceptualization, surgery and review of draft. SD: conceptualization, project administration, surgery and video recording, supervision, review of draft.

**Funding** This study was funded by Precipita (Crowdfunding campaign).

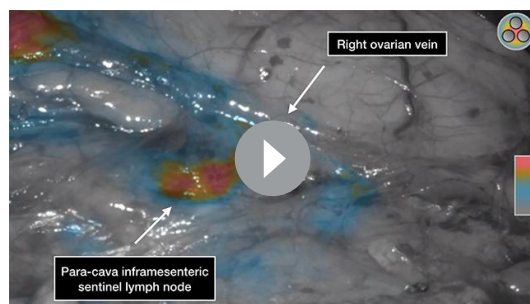
**Competing interests** None declared.

**Patient consent for publication** Not required.

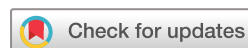**Provenance and peer review** Commissioned; internally peer reviewed.

## REFERENCES

- Colombo N, Sessa C, du Bois A, *et al*. ESMO-ESGO consensus conference recommendations on ovarian cancer: pathology and molecular biology, early and advanced stages, borderline tumours and recurrent disease. *Ann Oncol* 2019;30:672–705.
- Kleppe M, Wang T, Van Gorp T, *et al*. Lymph node metastasis in stages I and II ovarian cancer: a review. *Gynecol Oncol* 2011;123:610–4.
- Lago V, Minig L, Fotopoulou C. Incidence of lymph node metastases in apparent early-stage low-grade epithelial ovarian cancer: a comprehensive review. *Int J Gynecol Cancer* 2016;26:1407–14.
- Lago V, Bello P, Montero B, *et al*. Clinical application of the sentinel lymph node technique in early ovarian cancer: a pilot study. *Int J Gynecol Cancer* 2019;29:377–81.



Video 1.



© IGCS and ESGO 2019. No commercial re-use. See rights and permissions. Published by BMJ.

**To cite:** Lago V, Bello P, Marina Martín MT, *et al*. *Int J Gynecol Cancer* Published Online First: [please include Day Month Year]. doi:10.1136/ijgc-2019-000732