

Can somatic BRCA2 status solve a case of olaparib monotherapy resistance?

Presenter:

Antonella Pietragalla
Fondazione Policlinico Universitario A. Gemelli IRCCS, Rome, Italy

Discussants:

Angelo Minucci
Molecular and Genomic Diagnostics Laboratory, Fondazione Policlinico Universitario A. Gemelli IRCCS, Rome, Italy

Discussants:

Claudia Marchetti
Gynecologic Oncology, Fondazione Policlinico Universitario A. Gemelli IRCCS, Rome, Italy

Discussants:

Giovanni Scambia
Gynecologic Oncology, Fondazione Policlinico Universitario A. Gemelli IRCCS, Rome, Italy
Universita Cattolica del Sacro Cuore Facolta di Medicina e Chirurgia, Roma, Italy

Anna Fagotti
Gynecologic Oncology, Fondazione Policlinico Universitario A. Gemelli IRCCS, Rome, Italy
Universita Cattolica del Sacro Cuore Facolta di Medicina e Chirurgia, Roma, Italy

Correspondence to

Anna Fagotti, Gynecologic Oncology, Fondazione Policlinico Universitario A. Gemelli IRCCS, Rome 00168, Italy; annafagotti70@gmail.com

Accepted 23 August 2019

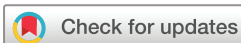CASE PRESENTATION

A Caucasian 55-year-old woman with FIGO stage IC high-grade serous ovarian cancer underwent total hysterectomy, bilateral salpingo-oophorectomy, infracolic omentectomy, and bilateral pelvic and para-aortic lymphadenectomy in November 2013. Subsequently, she received six cycles of paclitaxel (175 mg/m²) and carboplatin (AUC 5) until March 2014. The family history was significant for maternal breast cancer. In July 2014, based on tumor histology and after genetic counseling, germline BRCA (gBRCA) testing was proposed to the patient. The gBRCA test showed a known pathogenic variant (PV) in the BRCA2 gene: c.2494G>T, rs786202875, in heterozygous state, resulting in premature BRCA2 protein truncation (p.Glu832Ter). The primary tumor from the patient was tested by Hereditary Cancer Solution (Sophia Genetics, Switzerland) covering the coding regions of 26 most clinically relevant genes, associated with breast and ovarian cancer to investigate whether other genes were involved. Using this approach, we confirmed the gBRCA2 variant as well as the pathogenic TP53 variant c.395A>G, p.(Lys132Arg) as expected in high-grade ovarian cancer patients.

DR MARCHETTI**Would you propose BRCA 1/2 testing based on medical and family history only?**

Germline PVs in BRCA1/2 (BRCA) genes linked to hereditary breast and ovarian carcinoma development have been extensively studied. BRCA genes are involved in homologous DNA recombination and play an essential role in double-strand DNA break repair. Patients who have gPVs in either BRCA genes are at a higher risk for breast, ovarian, pancreatic, and prostate cancer compared with the general population. In 2011, a comprehensive analysis performed by The Cancer Genome Atlas demonstrated a >10% prevalence of gBRCA PVs in ovarian cancer patients, independently of age at diagnosis and family history of breast/ovarian cancer.^{1 2} Germline PVs prevalence progressively increases in patients with serous ovarian carcinoma (17%–20%), high-grade serous carcinoma (23%–25%), and in platinum-sensitive patients (30%–40%).¹

Based on these data, European and United States' guidelines recommend BRCA genetic testing for all ovarian, fallopian tube, and primary peritoneal cancer patients (with the exception of mucinous and borderline tumors) even in the absence of family history. BRCA testing should be proposed at the time of initial diagnosis, providing appropriate information about risk-assessment, prognosis, and therapeutic strategy.



© IGCS and ESGO 2019. No commercial re-use. See rights and permissions. Published by BMJ.

To cite: Pietragalla A, Minucci A, Marchetti C, *et al.* *Int J Gynecol Cancer* Published Online First: [please include Day Month Year]. doi:10.1136/ijgc-2019-000757

Case studies

Patients positive for BRCA1/2 pathogenic variants show a greater benefit from the treatment with PARP inhibitor olaparib as the results of the SOLO1 trial. First-line treatment with bevacizumab should be offered to BRCA wild-type patients.^{3,4}

DR MINUCCI

Would you perform somatic BRCA testing, based on positive gBRCA test results? if so, why, how, and when?

Currently, the BRCA test in peripheral blood ('germline or constitutional test') for the detection of constitutional pathogenic variants is performed in most laboratories using well-established techniques, namely by next-generation sequencing (NGS), eventually followed by Sanger sequencing for variant validation. In addition, patients harboring gBRCA and/or tumor BRCA (tBRCA) PVs are sensitive to PARPi and platinum-based chemotherapy.⁵ Consequently, BRCA testing on formalin-fixed paraffin-embedded or fresh frozen tissue samples, which allows for simultaneous somatic and gPVs assessment, has gained increasing diagnostic and clinical importance for high-grade serous ovarian cancer patients. In fact, in (-) gBRCA patients, the tBRCA testing conducted on a diagnostic biopsy or a primary staging or cytoreductive surgery, can identify the variants acquired as somatic mutations in addition to constitutional defect and, although a 3% of discrepancy has been proposed, up to a 100% concordance between tBRCA and gBRCA tests has been found when high-quality procedures are performed.⁶ In addition, considering that now searching for the largest genomic rearrangement from tumor analysis is possible, we underline that tBRCA may become the preferred method to detect both exclusive somatic and germline PVs, including copy number variations/large genomic rearrangements in HGSOc patients, replacing the gBRCA.⁷ Only, in the event of a positive result, must the alteration be verified in peripheral blood in order to ascertain its constitutional origin.

In this context, tBRCA will diminish the total number of genetic analyses, because in the presence of a negative result the patient will avoid gBRCA analysis. This consideration is placed in the context that one important practical issue is the limited availability of genetics counselors. As result, the delay for patients with advanced ovarian cancer accessing the geneticist consultation and gBRCA testing may not be compatible with the timing of personalized therapy and treatment. In addition, because many women with advanced ovarian cancer may not be concerned with the distressful issue of the hereditary risk, tBRCA testing may also favor a better use of geneticist consultation resources. In fact, at this time, genetic counseling is recommended both when genetic testing is offered to the patient and after genetic test results are disclosed. In the case of satisfactory information given by the clinician (gynecologist/oncologist) performing the initial tBRCA testing, we emphasize that only patients with a positive test result be referred to a geneticist.

We believe that this more streamlined testing approach, potentially starting from tBRCA analysis, with information given to the patient by the clinician, can also shorten testing turnaround times, but preserving, however, the autonomy of the patient for access to gBRCA testing. On the other hand, tBRCA testing in formalin-fixed paraffin-embedded (FFPE) or frozen fresh tissue samples is a multistep process involving pathology review, DNA extraction, quantification with quality control, library preparation, generation of sequencing data, bioinformatic analysis, and detection of

low-frequency variants, as well as variant classification to determine the implications for the patient. These issues make the test accessible only to personnel with the necessary expertise. Finally, somatic PVs in BRCA1 and BRCA2 are observed in approximately 3.5%–8.5% and 2.5%–4% of high-grade serous ovarian cancer patients without an underlying germline gPVs, respectively.⁷ Moreover, tBRCA testing can provide useful information also to (+) gBRCA patients. In fact, durable responses in women with advanced disease at diagnosis are uncommon and the development of acquired chemo-resistance often occurs during disease recurrence. In this context, NGS at the time of recurrence can provide detailed knowledge of the molecular tumor aberrancies allowing triage for treatment recommendations, if a BRCA mutation reversion event has occurred.

At the completion of primary chemotherapy, the patient did not receive any maintenance. She was without any evidence of disease until November 2015, when she was noted to have an increased serum CA125 serum level (74.4 UI/mL) and a PET-CT scan was ordered. This study detected recurrent disease in the right and left paracolic regions, mesentery, and diaphragm. In January 2016, she then had her initial presentation to our Gynecologic Oncology Division with recurrent high-grade serous ovarian cancer. The patient was counseled for secondary cytoreduction at this time.

DR FAGOTTI/DR SCAMBIA

What would you discuss with the patient regarding secondary cytoreductive surgery?

Imaging studies showed a localized abdominal relapse in a platinum-sensitive ovarian cancer patient, associated by elevated CA125 serum levels. The majority of data in platinum-sensitive recurrent ovarian cancer is derived from retrospective series. Two prospective multicenter randomized clinical trials, DESKTOP III (NCT #01166737) and GOG213 (NSC #704865), comparing secondary de-bulking surgery followed by platinum-based chemotherapy vs chemotherapy alone have been conducted. DESKTOP III patients were diagnosed with platinum-sensitive disease with a positive Arbeitsgemeinschaft Gynäkologische Onkologie score, Eastern Cooperative Oncology Group performance status 0, ascites ≤ 500 mL, and complete resection at initial surgery. The study showed the benefits of secondary cytoreductive surgery exclusively in completely resected patients with a significant improvement in median progression-free survival from 14.0 to 19.6 months (5.6 months [$P < 0.01$]). We are still awaiting results for the primary study endpoint and overall survival.⁸ The GOG213 trial was designed to assess two primary objectives: anti-vascular endothelial growth factor (VEGF) targeting impact (with bevacizumab) and overall survival after secondary cytoreduction in platinum-sensitive recurrent high-grade serous ovarian cancer. In particular, patients were randomized to surgery followed by chemotherapy vs chemotherapy alone. GOG213 showed that secondary cytoreductive surgery can be safely performed in patients with platinum-sensitive relapsed high-grade serous ovarian cancer but did not improve overall survival.⁹ To date, no data from randomized controlled trials are available on the correlation between secondary cytoreductive surgery and BRCA status.

On January 2016, the patient underwent diagnostic laparoscopy, as standard of care in our institution, to assess for miliary

carcinomatosis that could compromise a complete cytoreduction. Multiple⁴ but resectable areas of relapse were identified, and we proceeded with laparotomy, with anterior rectal resection and temporary colostomy, pelvic peritonectomy, appendectomy, right diaphragmatic stripping, and mesocolic nodule resection. There was no residual disease and final pathology confirmed recurrent high-grade serous carcinoma. The patient received six cycles of bevacizumab (15 mg/kg), carboplatin (AUC 4) on day 1, and gemcitabine 800 mg/m² on days 1 and 8 (February to June 2016) followed by maintenance bevacizumab (15 mg/kg) on day 1 every 21 days until January 2017 (22 cycles overall).

In February 2017, the patient suffered a bowel obstruction (volvulus) and underwent ileal resection with ileostomy without evidence of recurrent disease. During the planned reversal of ileostomy surgery, in May 2017, a diffused peritoneal recurrence was detected and surgery was then aborted. A CT scan confirmed diffused peritoneal carcinomatosis and suspicious lymph node metastases. The serum CA125 level was 84 U/mL. During reversal ileostomy surgery, a diffused peritoneal recurrence was detected. Therefore, the patient was enrolled in a randomized phase III trial SOLO3 (NCT02282020) evaluating single-agent olaparib efficacy and safety compared with standard chemotherapy in platinum-sensitive BRCA germline relapsed ovarian cancer patients. The patient was treated with olaparib 300 mg tablets twice a day, starting in July 2017 for 10 months until April 2018 with a partial response and clinical benefit.

DR MARCHETTI

How effective is PARP-inhibitor olaparib monotherapy in patients with BRCA mutations?

Olaparib's clinical efficacy as monotherapy has been evaluated in study 42. In December 2014, based on this study, the FDA approved olaparib as monotherapy for the treatment of high-grade serous ovarian cancer in patients with gBRCA mutation who had received at least three previous lines of chemotherapy. Study 42 is a single-arm, phase II study on olaparib (400 mg twice per day) treatment of patients with gBRCA1/2 m ovarian, breast, prostate, and pancreatic cancers who had received at least three prior lines of chemotherapy. The ovarian cancer cohort included 193 (147 patients were BRCA1, BRCA2 mutated) platinum-resistant/refractory patients or platinum-sensitive patients ineligible to receive further platinum-based chemotherapy. Overall response rate was 34% (95% CI, 26 to 42) and the median duration of response was 7.9 months (95% CI 5.6 to 9.6).¹⁰ The randomized phase III trial SOLO3 (NCT02282020) assessed the efficacy and safety of olaparib monotherapy compared with standard chemotherapy (weekly paclitaxel, topotecan, gemcitabine, or pegylated liposomal doxorubicin) in the platinum-sensitive patient population (266 gBRCA m patients). The trial was presented at the American Society of Clinical Oncology Annual Meeting in 2019 and showed an overall response rate (primary endpoint of the study) of 72% with olaparib vs 51% with standard chemotherapy (OR 2.53, 95% CI 1.40 to 4.58; P=0.002).¹¹ Other PARP-inhibitors such as rucaparib and niraparib have been also evaluated as monotherapy treatment.

In the pooled analysis of the study 10 and Ariel 2 trial, rucaparib as a single agent achieved an overall response rate of 53.5% with a duration of response of 9.2 for the treatment of BRCA-mutated

relapsed ovarian carcinoma patients who had received at least one prior platinum therapy.¹² Similarly, the Quadra study assessed the clinical benefit of niraparib treatment in heavily pretreated patients with ovarian cancer. In this setting, niraparib demonstrated activity in homologous recombination deficiency-positive patients who were PARP inhibitor-naive and platinum-sensitive (n=45), with an objective response rate of 28% and duration of response of 9.2 months.¹³ In BRCA-mutated patients, PARP-inhibitor monotherapy could represent a chemo-free target therapy option to individualize therapeutic strategies.

In April 2018, a CT scan revealed suspicious progressive disease, which was confirmed by PET-CT, with a 2 cm nodule with increased metabolic activity close to hepatic segment II. At this time, in June 2018, the patient underwent a third cytoreductive surgery with complete resection of Glisson's capsule and the peritoneal nodule. Histological examination confirmed an ovarian high-grade serous recurrence. There was no evidence of residual disease.

DR FAGOTTI/DR SCAMBIA

What is the role of tertiary cytoreductive surgery in recurrent ovarian cancer?

Data on the feasibility, efficacy, and safety of tertiary cytoreductive surgery derive from retrospective studies (most generated by single-institution experiences), demonstrating a benefit in patients with relapsed ovarian cancer. The largest multicenter retrospective study was by Fotopoulou et al involving 406 patients treated between 1997 and 2011 in 14 centers across Europe, the United States, and Asia. The median overall survival for patients without tumor residual vs any residuals was 49 months (95% CI, 42.5 to 56.4 months) vs 12 months (95% CI 9.3 to 14.7 months) (P<0.001).¹⁴ According to other studies, complete macroscopic tumor resection seems to have a significant impact on overall- and progression-free survival. Due to the lack of prospective randomized trials and the heterogeneous presentation of recurrent disease, an individualized approach in this setting should always be considered.

The decision regarding tertiary cytoreductive is always challenging. It should be performed only in highly selected patients and in specialized centers where high rates of complete tumor resection may be achieved. Prospective analyses are warranted to define its value in recurrent ovarian cancer patients, particularly in BRCA mutated patients. Until more robust data is presented, caution should be taken in proposing tertiary surgery: complete cytoreduction may not result in a clinical benefit for patients.

After tertiary cytoreductive surgery, the patient was started on third-line chemotherapy with liposomal doxorubicin (40 mg/m²) every 28 days in August 2018, which was stopped after only two cycles due to infusion reaction. At the same time, during a routine breast ultrasound screening, a multilobular left breast mass was noted with ipsilateral lymphadenopathy, confirmed by breast MRI. Biopsy confirmed a recurrence of ovarian cancer. In September 2018, a CT scan revealed diffused peritoneal carcinomatosis and left pleural effusion treated with pleural drainage catheter placement. From October 2018 to November 2018, the patient was treated with single-agent carboplatin (AUC 4). Treatment was stopped after two cycles due to progressive disease. The patient died in December 2018 (Figure 1).

Case studies

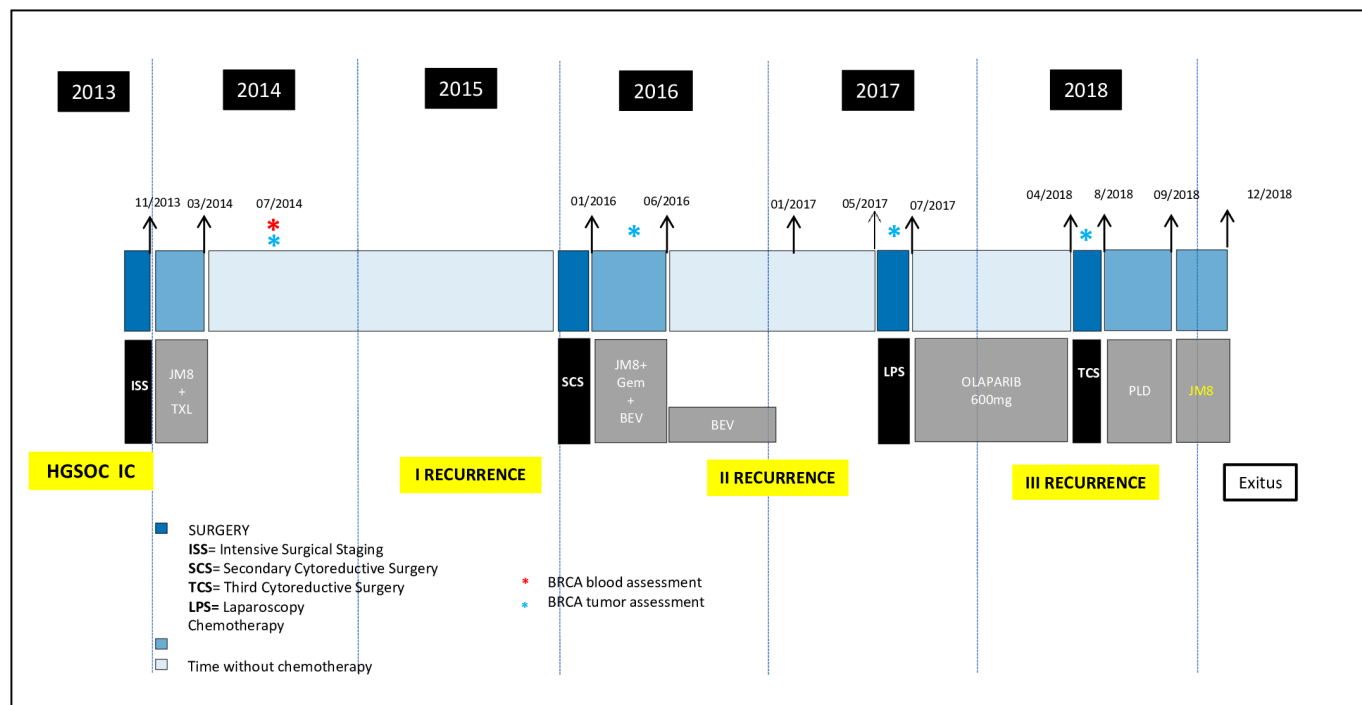


Figure 1 Patient's ovarian cancer history.

DR MINUCCI

How did resistance to olaparib arise?

The most widely accepted mechanism of PARPi resistance is the restoration of the HR pathway through secondary reversion mutations. A first mutation class involves a genetic reversion event, leading to deletion of a frameshift mutation, correcting the original reading frame, thereby producing an allele containing a new mutation, encoding a DNA-repair proficient BRCA1/2 protein.^{15 16} A second mutation class involves a direct reversion of the wild-type allele or a new BRCA1/2 isoform (as in this case) of the original mutation.¹⁷ However, other mechanisms such as upregulation of drug efflux pump (*p*-glycoproteins), aberrant MET/HGFR and PI3K/AKT signaling, and loss of PARP1 expression have been described as contributing to PARPi resistance.

Our case confirms that secondary BRCA1/2 mutations can be an important mechanism of resistance to olaparib in high-grade serous ovarian tumors and begins the discussion concerning how secondary BRCA1/2 mutations arise. In this patient, we can hypothesize that at least three factors may have contributed to secondary BRCA2 mutation: treatment with a DNA-damaging agent such as carboplatin, in first line-chemotherapy, increased the mutation rate and BRCA2 deficiency amplified this phenomenon, contributing to the occurrence of the secondary mutation; prolonged treatment with a platinum agent and drugs that selectively kill BRCA2-deficient cells (bevacizumab, carboplatin, gemcitabine) has supported the few BRCA2-expressing cells surviving the treatment; and treatment with PARP inhibitors served as a selective pressure for BRCA2-restored cells.

After treatment with PARPi, the patient's disease did not show a complete response and finally progressed. We hypothesized that a secondary BRCA2 mutation restoring BRCA2 activity could be responsible for disease progression. NGS on formalin fixed paraffin embedded sections, obtained from tertiary surgery, surprisingly

highlighted two BRCA2 variants: the gPV *c.2494G>T*, with a minor allele frequency of 11%, and a secondary BRCA2 *c.2494G>C* variant with a minor allele frequency of 45%. The last variant leads to an amino-acid substitution, *p.(Glu832Gln)*, rather than the introduction of a stop codon, as for the germline *c.2494T* allele, and potentially restores the BRCA2 open reading frame. In addition, glutamic acid and glutamine are structurally similar amino acids, hypothesizing that this substitution is likely to have a minimal effect on BRCA2 function when compared with wild-type allele. Finally, we tested multiple tumor samples from the patient (primary tumor, first and second recurrences) by NGS to demonstrate when the BRCA2 *c.2494G>C* variant arose. This approach did not highlight the *c.2494G>C* variant in any of the samples analyzed, allowing us to state that the appearance of the secondary BRCA2 variant occurred between II and III ovarian recurrences (Figure 2).

DR SCAMBIA/DR MARCHETTI

Which strategies may be used to prevent the development of reversion mutation and treat tumors with acquired PARPi resistance?

This case confirms a reversion BRCA2 mutation at the time of PARPi treatment. In theory, if reversions in BRCA mutations are acquired following therapy exposure, rather than existing in rare subclones in primary tumors, it is beneficial to administer PARPi earlier in the patient's therapy course rather than after relapse. This approach could provide a substantial benefit with regard to progression-free survival among BRCA1/2 mutation carriers.³ Moreover, preclinical and clinical studies are needed to develop therapeutic approaches, such as combination and sequencing approaches, if reversion mutations are identified. One approach could be to switch from a PARPi to an alternate treatment (such as standard chemotherapy) when a reversion mutation is detected and to come back to a PARPi

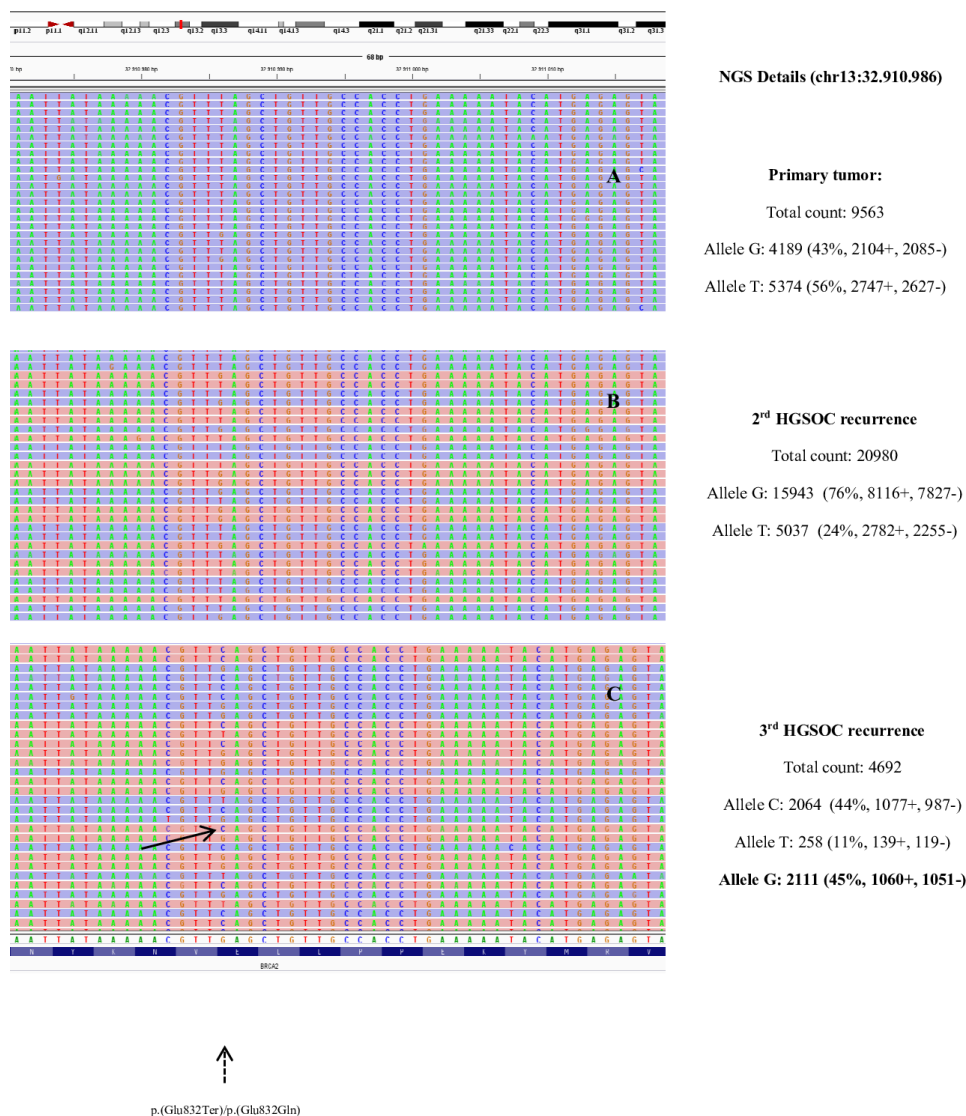


Figure 2 BAM files visualized by the Integrative Genomics Viewer show the sequencing reads associated to c.2494G>T, p.(Glu832Ter), variant in the primary tumor (A) and 2nd recurrence (B). In the 3rd recurrence (C), coexistence of the two BRCA2 variants (c.2494G>T/c.2494G>C) is shown (arrow). The dashed arrow indicates the nucleotide position of the two BRCA2 variants. On the right, next-generation sequencing (NGS) details of the BRCA2 c.2494 (LRG_293t1) position (chr13:32.910.986) obtained by the three tumor samples are reported. In the 3rd HGSO recurrence, NGS details of the new BRCA2 allele (c.2494G) are reported in bold.

treatment if the revertant clone decreases. Combination studies of PARPi with ATR inhibitors, chemotherapy, immune checkpoint, and VEGF inhibitors (such as cediranib) are currently in progress.

DISCUSSANTS' CLOSING SUMMARY

The recurrence of high-grade serous carcinoma is a common event despite initial maximum surgical effort and successful response to first-line platinum-based chemotherapy. Multiple recurrences, each associated with progressively shorter treatment-free intervals, characterize progressive disease. The role of secondary and tertiary cytoreductive surgery, in this specific context, is still controversial and there are no randomized controlled trials evaluating the correlation of surgery after primary chemotherapy and BRCA status. In the era of precision oncology, somatic BRCA testing followed by gBRCA mutation analysis for positive cases, should be

routinely performed in women with epithelial ovarian cancer, since PARPi therapy is the standard of care in BRCA-mutated patients. Early reversion mutation detection is important in clinical practice to evaluate olaparib efficacy better and to understand if the patient is a PARPi non-responder. Some questions remain unanswered: can early reversion mutation detection followed by therapeutic modifications really improve patient outcomes in the absence of radiologic disease progression? This question can only be answered with clinical trials investigating if the early detection of reversion mutations, particularly in patients without clinical progression or benefits, shows added value. Is olaparib as maintenance treatment beneficial to prevent the development of reversion mutations in patients with newly diagnosed, advanced BRCA-mutated ovarian cancer in complete or partial response following first-line standard platinum-based chemotherapy (SOLO1 trial, NCT01844986) rather

Case studies

than relapsed disease?³ A comprehensive approach is needed to achieve therapies that are more successful.

Contributors AP is the presenter. AF, CM, AM, GS are the discussants.

Funding The authors have not declared a specific grant for this research from any funding agency in the public, commercial, or not-for-profit sectors.

Competing interests AP worked in the AstraZeneca Medical Department until December 2018.

Patient consent for publication Not required.

Provenance and peer review Commissioned; internally peer reviewed.

REFERENCES

1. Alsop K, Fereday S, Meldrum C, *et al.* BRCA mutation frequency and patterns of treatment response in BRCA mutation-positive women with ovarian cancer: a report from the Australian Ovarian Cancer Study Group. *J Clin Oncol* 2012;30:2654–63.
2. The Cancer Genome Atlas Research Network. Integrated genomic analyses of ovarian carcinoma. *Nature* 2011;474:609–15.
3. Moore K, Colombo N, Scambia G, *et al.* Maintenance olaparib in patients with newly diagnosed advanced ovarian cancer. *N Engl J Med* 2018;379:2495–505.
4. Burger RA, Brady MF, Bookman MA, *et al.* Incorporation of bevacizumab in the primary treatment of ovarian cancer. *N Engl J Med* 2011;365:2473–83.
5. Pujade-Lauraine E, Ledermann JA, Selle F, *et al.* Olaparib tablets as maintenance therapy in patients with platinum-sensitive, relapsed ovarian cancer and a BRCA1/2 mutation (SOLO2/ENGOT-Ov21): a double-blind, randomised, placebo-controlled, phase 3 trial. *Lancet Oncol* 2017;18:1274–84. Sep18.
6. Ellison G, Ahdesmäki M, Luke S, *et al.* An evaluation of the challenges to developing tumor BRCA1 and BRCA2 testing methodologies for clinical practice. *Hum Mutat* 2018;39:394–405.
7. Enyedi MZ, Jaksa G, Pintér L, *et al.* Simultaneous detection of BRCA1/2 mutations and large genomic rearrangements in germline DNA and FFPE tumor samples. *Oncotarget* 2016;7:61845–59.
8. Du Bois A, Vergote I, Ferron G, *et al.* Randomized controlled phase III study evaluating the impact of secondary cytoreductive surgery in recurrent ovarian cancer: AGO DESKTOP III/ENGOT ov20. *JCO* 2017;35:5501.
9. Coleman RL, Enserro D, Spiratos N, *et al.* A phase III randomized controlled trial of secondary surgical cytoreduction (SSC) followed by platinum-based combination chemotherapy (PBC), with or without bevacizumab (B) in platinum-sensitive, recurrent ovarian cancer (PSOC): a NRG Oncology/Gynecologic Oncology Group (GOG) study. *JCO* 2018;36:5501.
10. Domchek SM, Aghajanian C, Shapira-Frommer R, *et al.* Efficacy and safety of olaparib monotherapy in germline BRCA1/2 mutation carriers with advanced ovarian cancer and three or more lines of prior therapy. *Gynecol Oncol* 2016;140:199–203.
11. Penson RT, Villalobos Valencia R, Cibula D, *et al.* Olaparib monotherapy versus (vs) chemotherapy for germline BRCA-mutated (gBRCAm) platinum-sensitive relapsed ovarian cancer (PSR OC) patients (PTS): phase III SOLO3 trial. *J Clin Oncol* 2019;37:5506.
12. Oza AM, Tinker AV, Oaknin A, *et al.* Antitumor activity and safety of the PARP inhibitor rucaparib in patients with high-grade ovarian carcinoma and a germline or somatic BRCA1 or BRCA2 mutation: integrated analysis of data from study 10 and ARIEL2. *Gynecol Oncol* 2017;147:267–75.
13. Moore KN, Secord AA, Geller MA, *et al.* Niraparib monotherapy for late-line treatment of ovarian cancer (QUADRA): a multicentre, open-label, single-arm, phase 2 trial. *Lancet Oncol* 2019;20:636–48.
14. Fotopoulou C, Zang R, Gultekin M, *et al.* Value of tertiary cytoreductive surgery in epithelial ovarian cancer: an international multicenter evaluation. *Ann Surg Oncol* 2013;20:1348–54.
15. Dhillon KK, Swisher EM, Taniguchi T. Secondary mutations of BRCA1/2 and drug resistance. *Cancer Sci* 2011;102:663–9.
16. Sakai W, Swisher EM, Karlan BY, *et al.* Secondary mutations as a mechanism of cisplatin resistance in BRCA2-mutated cancers. *Nature* 2008;451:1116–20.
17. Sakai W, Swisher EM, Jacquemont C, *et al.* Functional restoration of BRCA2 protein by secondary BRCA2 mutations in BRCA2-mutated ovarian carcinoma. *Cancer Res* 2009;69:6381–6.