

**Disclosures** Granular cell tumor of the breast is a rare tumor, often benign. The presence of criteria of malignancy must retain the vigilance of the clinician and the pathologist and encourage close clinical and radiological surveillance of the patient.

#### #74 VIN TREATMENT OUTCOMES AT A UK CENTRE OVER THE LAST 15 YEARS

Mark Mcgowan\*, Mercedes Jimenez-Linan, Filipe Martins, Peter Baldwin. *Cambridge University Hospitals, Cambridge, UK*

10.1136/ijgc-2023-ESGO.234

**Introduction/Background** Vulval intraepithelial neoplasia (VIN) is a premalignant lesion. The incidence of VIN is increasing and is estimated to be 3.8 per 100,000 women-years. This 15-year retrospective institutional study of treated VIN informs on recurrence rates, risk factors for recurrence following various treatment modalities.

**Methodology** Retrospective study of primary treatment and outcomes for VIN at CUH from 2008 to 2022. A total of 88 patients from the pathology database and 20 patients from the vulval clinic were grouped according to initial treatment modality.

**Results** The median age of the cohort was 51 (CI 50.2 – 55.0) years. Median follow-up time was 45 (CI 40 – 57) months. 4 groups were studied: Local excision with clear margins – n=26 with 5 recurrences at median 52 months - Multifocal disease (MFD) rate 19%, Local excision with positive margins – n=44 with 24 recurrences at median 23 months - MFD rate 50%, Laser – n=25 with 17 recurrences at median 26 months - MFD rate 64%, and Medical – n=13 with 7 recurrences at median 17 months - MFD rate 46%.

**Conclusion** Local excision achieving clear margins is associated with significantly lower risk of recurrence ( $p=0.003$ ). Where margins are positive relapse rates are higher and occur earlier after initial treatment (50% vs 19%;  $p0.004$ ). MFD is a risk factor for early recurrence ( $p=0.018$ ). These patients are at high risk of recurrence and may require multimodal treatments and more intense follow up.

**Disclosures** No conflicts of interest to disclose.

#### #79 ATR-FTIR SPECTROSCOPY ANALYSIS OF GYNECOLOGICAL TUMOR PARAFFIN BLOCKS

<sup>1</sup>Ariel Polonsky\*, <sup>1</sup>Hila Weinberger, <sup>1</sup>Moran Gawie- Rotman, <sup>1</sup>Fatma Kadan, <sup>1</sup>Ilana Bruchim, <sup>2</sup>Dov Malonek, <sup>2</sup>Ben Zion Dekel. <sup>1</sup>Hillel Yaffe medical center, Hadera, Israel; <sup>2</sup>Ruppitt institute, Hadera, Israel

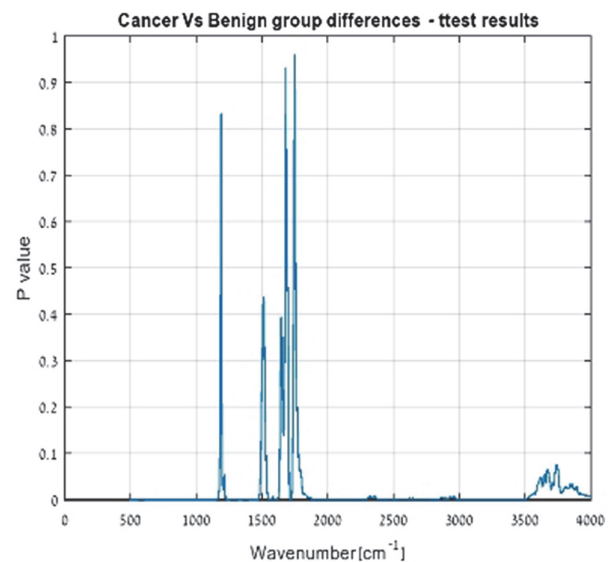
10.1136/ijgc-2023-ESGO.235

**Introduction/Background** Epithelial ovarian cancer (EOC) is the most lethal cancer among gynecological malignancies worldwide, accounting for 90% of all ovarian cancers. Our study's primary objective is to discriminate benign from malignant ovarian tumors using tissue samples that underwent formalin fixation using ATR-FTIR spectroscopy.

**Methodology** This is a retrospective, single center study. Inclusion criteria were of formalin fixed tissue taken from pathology archive samples, resected from females ages 18 and above. Two sets of slides from malignant tumors and 2 sets of slides from benign tumors were used to study the effect of tissue thicknesses on the measured absorption spectra: a set of

4 microns and a set of 12 microns from each tumor type were compared. Spectroscopic measurements were performed on the different slides. The 4 microns tissue thickness group was chosen. Each slide was measured in multiple locations. PCA-LDA Discrimination analysis was performed using the measured spectra. The cross-validation process was repeated five times. The results of these validations were then averaged to produce a single estimation.

**Results** A total of 74 tissue samples were examined. Absorption spectra of the malignant tumors were consistently different from that of benign tumors at many spectral ranges. Using K-fold cross validation technique, the study showed that the model correctly classified the samples into malignant and benign groups with an accuracy of 94.5%.



Abstract #79 Figure 1 Cancer group vs benign group differences

**Disclosures** Our study exhibits a sensitive method to differentiate between a benign and malignant paraffin block preparation. With further research, this technique could become an alternative to conventional histopathology.

#### #107 SARCOMAS OF THE BREAST: A RETROSPECTIVE STUDY OVER 25 YEARS FROM A SINGLE INSTITUTION

Fadoua Bouguerra\*, Hayfa Haj Abdallah, Wael Kaabia, Mohamed Souissi, Sabrine Tbesi, Bouzid Nadia, Samia Belajouza, Sameh Tebra. *Farhat Hached Hospital, Sousse, Tunisia*

10.1136/ijgc-2023-ESGO.236

**Introduction/Background** Breast sarcomas are a rare and heterogeneous group of malignant neoplasms that account for less than 1% of all breast cancers. Although surgery is considered the gold standard treatment, the management of adjuvant therapy remains controversial and uncertain. The objective of our work is to evaluate the therapeutic modalities of breast sarcomas by analyzing local experience.

**Methodology** We conducted a descriptive retrospective study of 14 cases of breast sarcoma treated at the Farhat Hached Hospital oncological radiotherapy department in Sousse, Tunisia, between 1995 and 2020. We analyzed patient characteristics, surgical procedures, and adjuvant therapy modalities.