



OPEN ACCESS

¹Department of Gynecologic Oncology, West China Second University Hospital, Chengdu, Sichuan, China

²Key Laboratory of Birth Defects and Related Diseases of Women and Children (Sichuan University), Ministry of Education, Chengdu, China

Correspondence to

Dr Ying Zheng, Department of Gynecologic Oncology, West China Second University Hospital, Chengdu, Sichuan, China; 3636647084@qq.com

Accepted 8 November 2022
Published Online First
16 December 2022

Transumbilical laparoendoscopic single-site radical trachelectomy with uterine arteries' ascending branches preservation for early-stage cervical cancer

Yu Chen,^{1,2} Ying Zheng ,^{1,2} Qiao Wang,^{1,2} Siyu Dai^{1,2}

Cervical cancer is the fourth-leading cause of cancer incidence and death among females according to Global Cancer Statistics 2018.¹ With an increasing number of young women being diagnosed with cervical cancer, fertility-sparing surgery is widely demanded. According to 2022 National Comprehensive Cancer Network guidelines, radical trachelectomy and pelvic lymphadenectomy are indicated for patients with stage IA2, stage IB1, and selected stage IB2 cervical cancers, meaning minimally invasive approach remains an option. The transumbilical laparoendoscopic single-site (TU-LESS) approach is now gaining in popularity for treating gynecologic diseases

because of its convenient specimen extraction, better cosmesis, reduced post-operative pain, and shorter recovery period.² To the best of our knowledge, this is the first case in which the whole laparoscopic procedure of radical trachelectomy through TU-LESS approach has been reported.

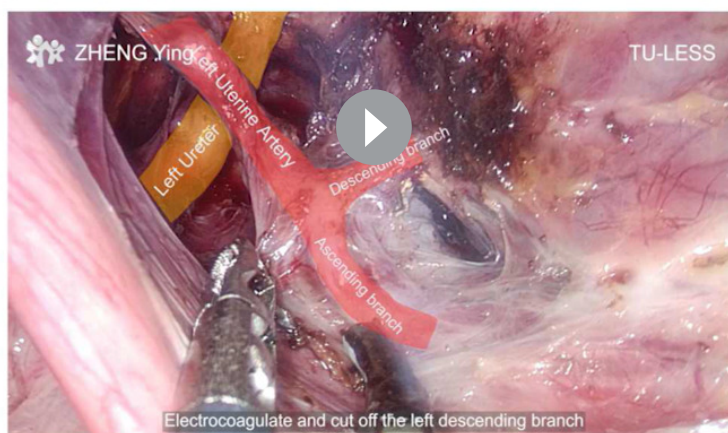This video demonstrates the fertility-sparing surgery procedure containing radical trachelectomy and pelvic lymphadenectomy with bilateral ascending branches of uterine arteries preservation. The patient was a 34-year-old woman diagnosed with International Federation of Gynecology and Obstetrics stage IB1 moderately differentiated squamous cervical

INTERNATIONAL JOURNAL OF GYNECOLOGICAL CANCER

Radical Trachelectomy with Uterine Arteries' Ascending Branches Preservation for Early-stage Cervical Cancer

Zheng Ying, Wang Qiao, Dai Siyu, Chen Yu

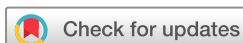Department of Gynecology, West China Second University Hospital, Sichuan University



 @IJGConline

Copyright © 2020 BMJ Publishing Group Ltd, International Gynecologic Cancer Society, & European Society of Gynaecological Oncology. All rights reserved.

Video 1 TU-LESS radical trachelectomy and pelvic lymphadenectomy with bilateral ascending branches preservation for early-stage cervical cancer.



© IGCS and ESGO 2023.
Re-use permitted under CC BY.
Published by BMJ.

To cite: Chen Y, Zheng Y, Wang Q, et al. *Int J Gynecol Cancer* 2023;**33**:835–836.

Video article

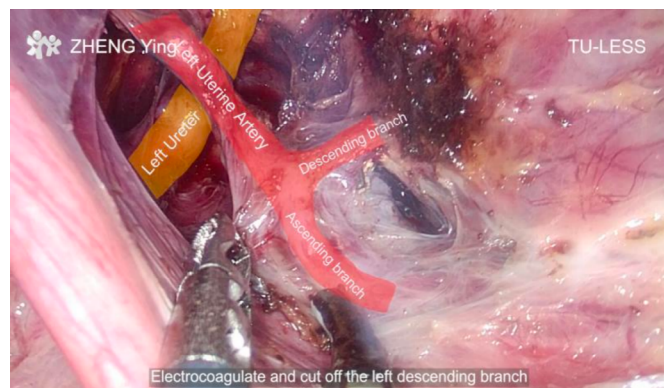

Figure 1 Exposure of uterine artery branches.

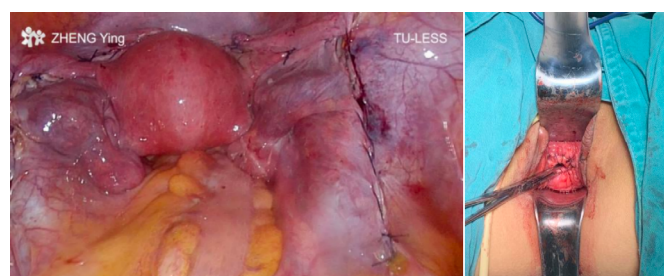


Figure 2 Inside and outside view after radical trachelectomy.

cancer who expressed a strong desire for reproduction. After sufficient consultation, she decided to receive a fertility-sparing treatment protocol. This video highlights the feasibility of sufficiently dissecting paracervical structures and exposing uterine artery branches with complex procedures and no assistance via TU-LESS. We adopted a simplified uterine manipulator, which minimized the squeezing and injury to the cervix, to assist exposure of the surgical field. Resection of the cervix was accomplished transvaginally with a cold knife to ensure sufficient margin. Pathology examination of surgical margin, lymph node specimens, and lymphovascular invasion were negative. The umbilical incision was closed by Zheng's anchor suturing technique to prevent incisional complications and improve cosmetics.³ No disease recurrence or surgical complications were detected in the 6 months of follow-up.

Minimally invasive surgery is safe and effective for fertility-sparing without compromising oncologic outcomes, especially

in patients with a tumor size <2 cm.⁴ TU-LESS is a feasible option for delicate dissection in radical trachelectomy and can achieve minor incision and faster recovery. However, owing to the limited operational space and absence of assistance in TU-LESS, this type of surgery requires an extensive learning curve before performance.

Contributors YC performed the data collection, video production, and manuscript preparation. YZ was the guarantor of the study and was a responsible surgeon. QW and SD were responsible surgeons.

Funding This work was supported by Key Science and Technology Projects of Sichuan Province (2020YFS0049) and Technological Innovation Research and Development Projects of Chengdu Science and Technology Bureau (2019-YF05-00473-SN).

Competing interests None declared.

Patient consent for publication Not applicable.

Ethics approval This study involves human participants and was approved by West China Second University Hospital (protocol identification number: 2022034). Participants gave informed consent to participate in the study before taking part.

Provenance and peer review Not commissioned; externally peer reviewed.

Data availability statement All data relevant to the study are included in the article and video.

Open access This is an open access article distributed in accordance with the Creative Commons Attribution 4.0 Unported (CC BY 4.0) license, which permits others to copy, redistribute, remix, transform and build upon this work for any purpose, provided the original work is properly cited, a link to the licence is given, and indication of whether changes were made. See: <https://creativecommons.org/licenses/by/4.0/>.

ORCID iD

Ying Zheng <http://orcid.org/0000-0002-7136-0113>

REFERENCES

- 1 Bray F, Ferlay J, Soerjomataram I, *et al*. Global cancer statistics 2018: GLOBOCAN estimates of incidence and mortality worldwide for 36 cancers in 185 countries. *CA Cancer J Clin* 2018;68:394–424.
- 2 Boruta DM. Laparoendoscopic single-site surgery in gynecologic oncology: an update. *Gynecol Oncol* 2016;141:616–23.
- 3 Chen Y, Zheng Y, Xu L-F, *et al*. Zheng's anchor suturing technique for safe and cosmetic umbilical incision in transumbilical laparoendoscopic single-site surgeries. *Surg Today* 2022. doi:10.1007/s00595-022-02585-6. [Epub ahead of print: 15 Oct 2022].
- 4 Nezhat C, Roman RA, Rambhatla A, *et al*. Reproductive and oncologic outcomes after fertility-sparing surgery for early stage cervical cancer: a systematic review. *Fertil Steril* 2020;113:685–703.