Introduction/Background Pelvic reconstruction after pelvic exenteration is a challenge for gynecologic oncology surgeons. In this vulvar relapse case, a huge defect was left in the perineum after the exenteration. We decided to do a double V-YT flap in order to fill all the defect and a sigmoid neovagina for the sexual reconstruction and to avoid an empty pelvis syndrome.
Methodology Video edited.
Results .
Conclusion .

2022-RA-1155-ESGO FEASIBILITY OF HAND ASSISTED LAPAROSCOPIC SENTINEL NODE BIOPSY IN VULVAR CANCER USING COMBINED RADIOACTIVE AND FLUORESCENCE GUIDANCE

Giuseppina Fais, Alfonso Altieri, Giulia Carboni, Giuseppe Deo, Maria Luisa Fais, Andrea Ungredda, Valerio Mais, Stefano Angioni, Michele Peiretti. *Department of Surgical Sciences, Division of Gynecology and Obstetrics, University of Cagliari, Italy*

10.1136/ijgc-2022-ESGO.953

Introduction/Background The aim of this preliminary retrospective study was to assess the feasibility and accuracy of Indocyanine Green (ICG) sentinel lymph node (SLN) sampling using a laparoscopic camera during vulvar cancer staging.
Methodology Retrospective study. Between 2016 and 2022, 9 women with diagnosis of vulvar cancer underwent radical vulvectomy and inguinofemoral lymphadenectomy; in 2 (22%) selected cases we performed ICG SLN mapping using the IMAGE1 laparoscopic camera combining with Tc99(m)-nanocolloid during open surgery.

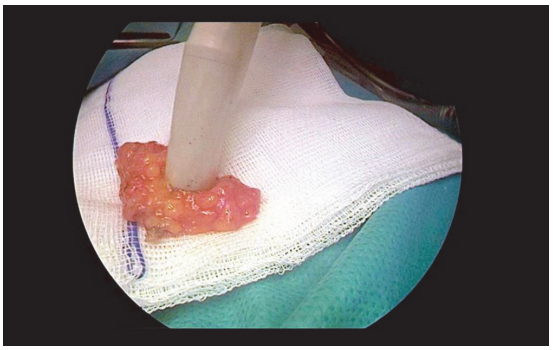

Abstract 2022-RA-1155-ESGO Figure 1

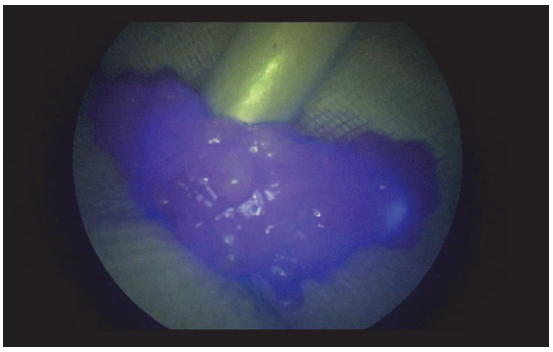

Abstract 2022-RA-1155-ESGO Figure 2

Results The median age of patients was 73 (range 84–60) years. Mean operative time 212.5 minutes. The overall detection rate of SLN mapping was 100%. No post-operative short or long-term complications related to the procedure were observed.
Conclusion Real-time NIR technology supported by the IMAGE1 S by Storz is a reliable system and represents a consolidated method for SLN mapping in selected cases with vulvar cancer.

In our study we confirmed the feasibility of Hand-Assisted Laparoscopy during an open procedure to detect groin SLN with ICG in vulvar cancer. This approach can be used in combination with Tc99(m)-nanocolloid, increasing the detection rate or it can be an appropriate option to detect SLN in those countries where Tc99(m)-nanocolloid is not available or cannot be practiced.

The use of laparoscopic camera for ICG SLN mapping seems to be accessible and inexpensive. Further studies are needed to evaluate the accuracy and oncological outcomes.

2022-RA-1162-ESGO PROACTIVE MANAGEMENT IN VULVAR RADIOTHERAPY FACILITATES TREATMENT COMPLETION

[1]Inbal Golomb, [2]Eliya Shachar, [1]Dorin Berman, [1]Adi Davidovitch, [1]Yasmin Korzetz, [1]Yasmin Natan Oz, [1]Tatiana Rabin. [1]*Radiation Oncology, Tel Aviv Medical Center, Tel Aviv, Israel*; [2]*Medical Oncology, Tel Aviv Medical Center, Tel Aviv, Israel*

10.1136/ijgc-2022-ESGO.954

Introduction/Background Vulvar carcinoma is a rare malignancy, accounting for 4% of gynecological malignancies. Radiotherapy is commonly used and highly effective yet associated with severe adverse effects and psychological implications which limit treatment completion.Only 50% of patients complete the radiotherapy planned treatment(>20 fractions, duration <8 weeks and <1 week of break).Guidelines for management and supportive care during radiotherapy for vulvar carcinoma are lacking.
Methodology We retrospectively analyzed medical charts of patients who underwent radiotherapy for vulvar carcinoma from October 2018-December 2021.
Results Among 17 patients treated at our institution, 8 received definitive therapy, 8 adjuvant treatment, and 1 palliative radiation. Radiation doses ranged from 36–66Gy. Seven patients were treated with an electron boost, 2 with a brachytherapy boost. The most common side effects included local pain, requiring analgesics and cannabis among 12 women and skin burns in 15 women, 5 had grade III burns, of which one required hyperbaric oxygenation.

In an effort to facilitate treatment completion, a proactive approach was employed, including instruction and guidance regarding the treatment process prior to initiation. Close monitoring entailing weekly physician visits, and with the onset of adverse events, more intense 2–3 assesments per week were instituted, focusing on pain alleviation. In an effort to ease the emotional burden and anxiety, patients were supported by a social worker and psychologist. Treatment breaks were initiated by physician prior to severe burn development in order to prevent longer breaks or cessation of radiotherapy. Eleven patients had physician-initiated breaks, with an average duration of 4.3 days. Four women had breaks over 1 week (median 9.5 days), all in the definitive treatment setting. All patients completed the treatment regimen. With an average