

invading ureters on magnetic resonance imaging. This surgery is presenting a central pelvic recurrence of a cervix cancer previously treated with chemoradiation. After an anterior pelvic exenteration surgery, an ileal conduit urinary diversion performed. This surgical video contains the steps of ileal conduit; isolation of the ileal loop, stapled side to side ileo-ileal anastomosis, urostomy fixation, pigtail stent insertion and uretero-ureteral anastomosis.

Methodology A 20 cm ileum segment is isolated and ureters are anastomosed to the proximal end of the conduit and the distal end is used to perform a cutaneous stoma for urine drainage, which is externally connected to a collection device attached to the skin

Results Ileal conduit urinary diversion is an incontinent urinary diversion.

Conclusion This type of urinary diversion is incontinent but can be easily managed by patients.

2022-RA-1174-ESGO

ROLE OF ADJUVANT THERAPY IN INTERMEDIATE-RISK CERVICAL CANCER PATIENTS – SCCAN STUDY SUB-ANALYSIS

¹David Cibula, ²Huseyin Akilli, ³Luc RCW van Lonkhuijzen, ⁴Anna Fagotti, ¹Lukáš Dostálek, ⁵David Isla Ortiz, ⁶Mehmet Mutlu Meydanli, ⁷Nadeem R Abu-Rustum, ⁸Diego Odetto, ⁹Fabio Landoni, ¹⁰Jiri Presl, ¹¹Jaroslav Klat, ¹²Henrik Falconer, ¹³Aldo Lopez, ¹⁴Ricardo dos Reis, ¹⁵Ignacio Zapardiel, ¹⁶Rene Laky, ³Constantijne H Mom, ⁴Nicolò Bizzarri, ²Ali Ayhan. ¹Gynecologic Oncology Center, Department of Obstetrics and Gynecology, First Faculty of Medicine, Charles University and General University Hospital (Central and Eastern European Gynecologic Oncology Group, CEEGOG), Prague, Czech Republic; ²Baskent University School of Medicine Department of gynecology and Obstetrics Division of Gynecologic Oncology, Ankara, Turkey; ³Amsterdam University Medical Centers, Center for Gynecologic Oncology Amsterdam, Amsterdam, Netherlands; ⁴Fondazione Policlinico Universitario A. Gemelli, IRCCS, UOC Ginecologia Oncologica, Dipartimento per la salute della Donna e del Bambino e della Salute Pubblica, Rome, Italy; ⁵Gynecology Oncology Center, National Institute of Cancerology Mexico, Mexico City, Mexico; ⁶Department of Gynecologic Oncology, Zekai Tahir Burak Women's Health and Research Hospital, University of Health Sciences, Ankara, Turkey; ⁷Memorial Sloan Kettering Cancer Center, New York, NY; ⁸Department of Gynecologic Oncology, Hospital Italiano de Buenos Aires, Instituto Universitario Hospital Italiano, Buenos Aires, Argentina; ⁹University of Milano-Bicocca, Department of Obstetrics and Gynecology, Gynaecologic Oncology Surgical Unit, ASST-Monza, San Gerardo Hospital, Monza, Italy; ¹⁰Department of Gynaecology and Obstetrics, University Hospital Pilsen, Charles University in Prague, Pilsen, Czech Republic; ¹¹Department of Obstetrics and Gynecology, Faculty of Medicine, University Hospital and University of Ostrava, Ostrava, Czech Republic; ¹²Department of Pelvic Cancer, Karolinska University Hospital and Department of Women's and Children's Health, Karolinska Institutet, Stockholm, Sweden; ¹³Department of Gynecological Surgery, National Institute of Neoplastic Diseases, Lima, Peru; ¹⁴Department of Gynecologic Oncology and Reproductive Medicine, The University of Texas MD Anderson Cancer Center, Houston, TX; ¹⁵Gynecologic Oncology Unit, La Paz University Hospital – IdiPAZ, Madrid, Spain; ¹⁶Gynecology, Medical University of Graz, Graz, Austria

10.1136/ijgc-2022-ESGO.96

Introduction/Background The 'intermediate-risk' (IR) group of early-stage cervical cancer patients is characterised by negative pelvic lymph nodes and a combination of tumour-related prognostic risk factors such as tumour size ≥ 2 cm, presence of lymphovascular space invasion (LVSI), and deep stromal invasion. The role of adjuvant treatment in these patients remains controversial, based on a single randomised GOG 92 study performed more than 20 years ago. The objective of our study was to evaluate if adjuvant (chemo)radiation is associated with a disease-free survival benefit after radical surgery in patients with IR cervical cancer.

Methodology We analysed data from patients who met criteria for intermediate risk cervical cancer (tumour 2–4 cm +LVSI

OR tumour size >4 cm; N0; no parametrial invasion; clear surgical margins), underwent primary surgical treatment with a curative intent between 2007 – 2016, and were registered in the international multicentre Surveillance in Cervical CANcer (SCCAN) study. Administration of the adjuvant treatment stratified the cohort in two subgroups in which oncological outcomes were evaluated and compared using log-rank test.

Results Of 692 patients included in the analysis, 274 (39.6%) patients received no adjuvant treatment (AT-) and 418 (60.4%) were treated with adjuvant radiotherapy or chemoradiotherapy (AT+). The 5-year disease-free survival was 83.2% and 80.3% ($P=0.365$) and corresponding overall survival 88.7% and 89.0% ($P=0.281$) in AT- and AT+ groups, respectively (figure 1). Separate sub-group analyses in patients with tumour ≥ 4 cm and 2–4 cm +LVSI also did not reveal any significant survival benefit of combined treatment in either of the sub-groups. Adjuvant (chemo)radiotherapy was not identified as an independent prognostic factor in the cohort or any of the sub-groups.

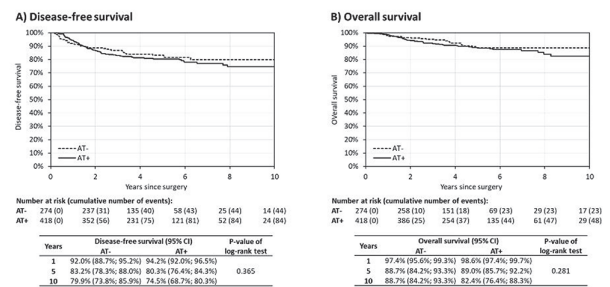


Figure 1 Disease-free survival (A) and Overall survival (B) of intermediate-risk cervical cancer patients divided by administration of adjuvant treatment

AT-: patients did not undergo adjuvant treatment; AT+: patients underwent adjuvant treatment (radiotherapy or chemoradiation). Time 0 marks the day of the surgical treatment.

Abstract 2022-RA-1174-ESGO Figure 1 Disease-free survival (A) and overall survival (B) of intermediate-risk cervical cancer patients divided by administration of adjuvant treatment

AT-: patients did not undergo adjuvant treatment; AT+: patients underwent adjuvant treatment (radiotherapy or chemoradiation). Time 0 marks the day of the surgical treatment

Conclusion Radical surgery alone achieved equal disease-free and overall survival in patients with intermediate-risk, early-stage cervical cancer as compared with combined treatment composed of radical surgery and adjuvant (chemo) radiotherapy.

2022-RA-1180-ESGO

NONFUNCTIONAL COMPLICATIONS ASSOCIATED WITH RADICAL HYSTERECTOMY

¹María Alonso-Espías, ¹Alicia Hernández, ²Marcos Alonso-García, ¹Myriam Gracia, ¹Virginia García-Pineda, ¹Jaime Siegrist, ¹María Dolores Diestro, ³Rocío Amedo, ¹Ignacio Zapardiel. ¹Gynecologic Oncology Unit, La Paz University Hospital, Madrid, Spain; ²General Direction of Public Health, Madrid, Spain; ³La Paz University Hospital, Madrid, Spain

10.1136/ijgc-2022-ESGO.97

Introduction/Background Bladder dysfunction is the most frequent complication after radical hysterectomy. However, there are other relevant complications associated with cervical cancer