

Results 1,460 patients with a rare gynecologic cancer entered our department. 1,092 patients received any kind of therapy and 368 'only' had a consultation. The most common histologic types were: borderline tumors of the ovary (424 pts, 29%), low grade serous ovarian cancer (179 pts, 12.3%), ovarian sex cord-stromal tumors (164 pts, 11.2%), uterine sarcoma (142 pts, 10%), clear cell ovarian cancer (115 pts, 8%), and ovarian germ cell tumors (73 pts, 5%). There was a continuous increase of pts over the years: 237 (2011–2013), 215 (2014–2015), 276 (2016–2017), 347 (2018–2019), 385 (2020–2021) cases. In total, 905 pts came from NRW and 555 patients from other states.

Conclusion We observe a centralization of patients from whole Germany with rare gynecological cancers in our center with a rising number of patients during the observation period. This provides a unique chance for further research in rare gynecologic tumors and also allows to offer prospective trials.

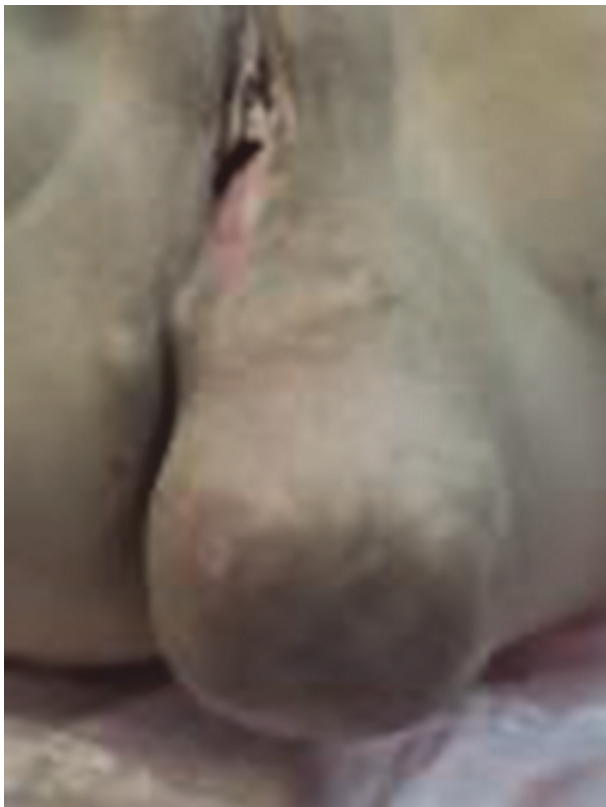2022-RA-786-ESGO

ANGIOMYXOMA AGGRESSIVUM – SURGICAL COMPLETE RESECTION OF EXTREMELY RARE TUMOR OF PERINEUM

¹Marcin Jedryka, ¹Andrzej Czekanski, ¹Piotr Lepka, ²Marcin Zietek. ¹*Oncological Gynecology, Wrocław Medical University and Lower Silesian Oncology Center, Wrocław, Poland*; ²*Oncological Surgery, Wrocław Medical University and Lower Silesian Oncology Center, Wrocław, Poland*

10.1136/ijgc-2022-ESGO.407

Introduction/Background Angiomyxoma aggressivum is an extremely rare perineal tumor that expansively grows compressing the locally adjacent organs.



Abstract 2022-RA-786-ESGO Figure 1

Methodology This is a case report of a 47-year-old patient with huge tumor of perineum localised on the left side of perineum, along the vaginal and rectal wall stretching out from the left obturator fossa till the left buttock. The tumor was previously partially debulked in other hospital giving the histopathological diagnosis of aggressive angiomyxoma with high estrogen receptors expression. The adjuvant hormone therapy of GNRH analogues was then introduced with initial good clinical outcome. After almost one year of clinical remission the flabby tumor grew back to the vast dimensions causing many ailments. After thorough imaging diagnostics excluding local pelvic muscles infiltration and any distant metastases as well the patient was qualified for radical debulking surgery from the perineal access. The resection was completely performed when the proper dissecting plane of this locally aggressive tumor had been found with the anatomic respect of vital vessels and nerves. The perineal plastic surgery followed then the surgical complete excision simultaneously. The postoperative course was uneventful. The pathologic report confirmed the previous diagnosis of aggressive angiomyxoma with clear surgical margins.

Results The patient is being strictly followed-up for one year so far with no signs of the relapse both in clinical and imaging examinations.

Conclusion Perineal aggressive angiomyxoma is a very rare tumor with unequivocal tendency of local recurrence. The scant publications suggest that complete surgical resection is the best option to prevent of the disease relapse. Systematic treatment or radiotherapy have not been proved to be effective, however antiestrogenic hormone therapy is recommended as this kind of perineal tumor usually has pronounced hormonal receptors expression.

2022-RA-816-ESGO

THE IMPACT OF THE NEW RCOG 2019 CURRICULUM AND COVID 19 PANDEMIC ON GYNAECOLOGICAL TRAINING AMONGST THE SPECIALIST TRAINEES IN THE UNITED KINGDOM: A PROSPECTIVE STUDY

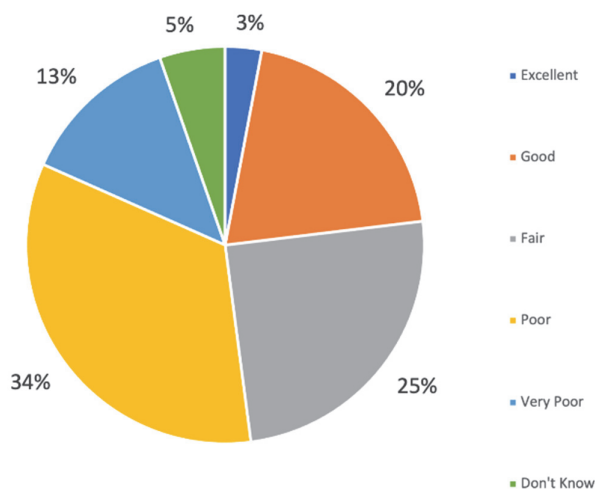
^{1,2}Anas Barakat, ¹Aemn Ismail, ^{1,2}Supratik Chattopadhyay. ¹*Gynaecology Oncology Department, University Hospitals of Leicester NHS Trust, LEICESTER, UK*; ²*Leicester Cancer Research Centre, University of Leicester, Leicester, UK*

10.1136/ijgc-2022-ESGO.408

Introduction/Background The Royal College of Obstetricians and Gynaecologists (RCOG) introduced a new curriculum in 2019, where a new portfolio was implemented by all obstetrics and gynaecology trainees across the UK. Four professional identities replaced nineteen modules. Furthermore, the National Health Service was hit by the COVID 19 pandemic in 2020. Our survey aims to find how the new RCOG curriculum and COVID 19 pandemic affected gynaecological training amongst specialist trainees in the UK.

Methodology A cross sectional study was conducted using the University of Leicester online survey platform involving the RCOG trainees in the UK from the 1st of June 2021 to the 1st of October 2021. The survey was divided into two main categories: 1) new RCOG curriculum and gynaecology training, 2) COVID 19 pandemic and gynaecology training.

Results We received replies from 10% of trainees. The quality of gynaecology training under the new RCOG curriculum was described as less than good in 75.6% of respondents (figure 1). However, it was observed that the subspecialty trainees were the most satisfied trainees, with 66.7% describing training as good to excellent. The COVID 19 pandemic adversely affected all aspects of gynaecology training. Benign gynaecology, subfertility, urogynaecology, and gynaecology modules training were affected in 94.0%, 85.1%, 89.7%, and 83.5% of trainees, respectively (table 1). During the pandemic, gynaecology teaching was affected in 84.9% of trainees, redeployment occurred in 11.8% of trainees, and 16% suffered adverse ARCP outcomes.



Abstract 2022-RA-816-ESGO Figure 1

Abstract 2022-RA-816-ESGO Table 1 The impact of COVID 19 pandemic on gynaecology training of respondents

Module	Not at all affected	Slightly affected	Moderately affected	Very affected	Extremely affected
Benign Gynaecology	6%	6%	15.8%	37.6%	34.6%
Sub-fertility	14.9%	6.6%	15.7%	31.4%	31.4%
Uro-gynaecology	10.3%	6.3%	14.3%	29.4%	39.7%
Gynae-Oncology	16.5%	16.5%	21.3%	23.6%	22%
Hysteroscopy	14.6%	18.7%	24.4%	20.3%	22%
Colposcopy	22.4%	15.2%	13.6%	24%	24.8%

Conclusion Our survey reveals that the new RCOG curriculum and COVID 19 pandemic have simultaneously compromised the gynaecology training amongst the UK trainees. RCOG and GMC-led more exhaustive survey would be welcomed to

corporate our findings and take necessary actions. Gynaecology training amongst current trainees should be of the highest quality to optimize patient care in line with the professional skills recommended by the GMC.

2022-RA-828-ESGO

A CASE OF 19 YEARS OLD, FEMALE WITH MALIGNANT SPINDLE CELL NEOPLASM; PELVIC MONOPHASIC SYNOVIAL SARCOMA ARISING FROM THE PELVIC LIGAMENTS

Ronald Rodriguez Latap, Leobert Julienne A Dela Pena. *Obstetrics and Gynecology, West Visayas State University, Iloilo City, Philippines*

10.1136/ijgc-2022-ESGO.409

Introduction/Background Sarcomas are uncommon arising from mesenchymal elements anywhere in the body. Synovial Sarcoma or Malignant Synovioma arises from different types of soft tissues such as muscles and ligaments. It is classified into biphasic, monophasic or poorly differentiated. Biphasic is composed of epithelial cells, spindle fibroblast-like cells and few epitheloid cells. Monophasic type exhibit abundant spindle cells, epitheloid cells though lacking in clearly defined epithelial component.

Methodology Case of a 19 years old, nulligravid with hypogastric pain and abdominal mass. CT scan revealed complex illdefined mass, moderate ascites and clots. She underwent cytoreductive surgery with findings of pelvic mass attached to the right adnexa and uterus. Histopathologic result revealed malignant spindle cell neoplasm and immunohistochemical studies showed positive CD 99, TLE 1, Bcl-2, S100 and Desmin. Intraoperatively it is classified as Stage 1A according to AJCC Staging System.

Results It is caused by unique chromosomal translocations of t(X;18) (p11.2;q11.2) found in more than 90% of cases. Immunohistochemistry has been proven to be pivotal in its diagnosis. Initial surgery is an important prognostic factor.

Conclusion Synovial sarcoma rare type of soft tissue neoplasm affecting adolescents and young adults. It originates from primitive or uncommitted mesenchymal cells that differentiate to resemble synovial cells. It is caused by unique chromosomal translocations of t(X;18) (p11.2;q11.2) found in more than 90% of cases resulting in formation two fusion genes: SYT-SSX1 or SYT-SSX2. Immunohistochemical studies positive for TLE1, CD99, Bcl-2, S-100 and Desmin. These results are consistent showing reactivity with epithelial membrane antigen, cyokeratin, E-cadherin, S-100 in combination with CD34 negativity are useful and sensitive markers. Initial surgery is an important prognostic factor, it has a 5-year survival rate of 76% after cytoreductive surgery. Adjuvant chemotherapy with ifosfamide with doxorubicin may be given but there are no specific guidelines because of its rarity.