







# Ghost ileostomy: prevention, diagnosis, and early treatment of colorectal anastomosis leakage in advanced ovarian cancer

Victor Lago <sup>1</sup>, Lourdes Sala Climent <sup>2</sup>, Blanca Segarra-Vidal <sup>1</sup>, Matteo Frasson,<sup>3</sup> Blas Flor,<sup>3</sup> Santiago Domingo <sup>1</sup>

<sup>1</sup>Gynecology Oncology, La Fe University and Polytechnic Hospital, Valencia, Spain

<sup>2</sup>Department of Gynecology, Arnau de Vilanova University Hospital, Lleida, Spain

<sup>3</sup>Department of Colorectal Unit, La Fe University and Polytechnic Hospital, Valencia, Spain

## Correspondence to

Lourdes Sala Climent, Department of Gynecology, Arnau de Vilanova University Hospital, Lleida, Catalunya, Spain; [salalourdes.275@gmail.com](mailto:salalourdes.275@gmail.com)

Accepted 2 November 2021

Published Online First

16 November 2021

In ovarian cancer, modified posterior pelvic exenteration and end-to-end colorectal anastomosis are usually necessary to achieve optimal cytoreduction. Anastomotic leak ranges from 1.7% to 6.8%, and is the main life-threatening scenario after colorectal anastomosis. It has been associated with an increase in morbidity and mortality rates, days of hospitalization, and chemotherapy delays.<sup>1</sup>

With regard to the management after colorectal anastomosis, ghost ileostomy has been shown to be a good approach to reduce the rate of protective stoma.<sup>2,3</sup> The use of ghost ileostomy in conjunction with close post-operative monitoring (C-reactive protein, procalcitonin, and rectoscopy) allows early


and sub-clinical diagnosis of leakage. It can be easily converted into a diverting ileostomy if an anastomotic leakage is suspected, and only requires the loop removal for reversal. During the conversion into a diverting ileostomy it also allows a wash-up of the abdominal cavity to be done and the placement of a percutaneous drainage if indicated. Consequently, ghost ileostomy avoids the disadvantages associated with stoma such as dehydration, malnutrition, renal failure, prolapse, or stricture. Additionally, it also avoids the impact on self-image and quality of life associated with stoma.<sup>3,4</sup>

We present a case in which end-to-end colorectal anastomosis was performed due to an advanced



INTERNATIONAL JOURNAL OF  
**GYNECOLOGICAL CANCER**

---

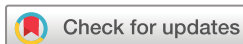## GHOST ILEOSTOMY: PREVENTION, DIAGNOSIS, AND EARLY TREATMENT OF COLORECTAL ANASTOMOSIS LEAKAGE IN ADVANCED OVARIAN CANCER.


**Victor Lago <sup>1</sup>; Lourdes Sala <sup>2\*</sup>; Blanca Segarra-Vidal <sup>1</sup>; Matteo Frasson <sup>3</sup>; Blas Flor <sup>3</sup>; Santiago Domingo <sup>1</sup>**

<sup>1</sup> Department of Gynecologic Oncology, University Hospital La Fe (Valencia, Spain)  
<sup>2</sup> Department of Gynecology, University Hospital Arnau de Vilanova (Lleida, Spain); \* Corresponding author  
<sup>3</sup> Department of Surgery, University Hospital La Fe (Valencia, Spain)


 @IJGOnline

Copyright © 2020 BMJ Publishing Group Ltd, International Gynecologic Cancer Society, & European Society of Gynaecological Oncology. All rights reserved.



© IGCS and ESGO 2022. No commercial re-use. See rights and permissions. Published by BMJ.

**To cite:** Lago V, Sala Climent L, Segarra-Vidal B, *et al.* *Int J Gynecol Cancer* 2022;**32**:109–110.

**Video 1** Ghost ileostomy: prevention, diagnosis and early treatment of colorectal anastomosis leakage

## Video article

ovarian cancer. A protective ghost ileostomy was performed as follows: a portion of terminal ileum 20 cm distant from the ileocecal valve was identified, the afferent and efferent portions were marked with a long and short stitch, and a vessel loop was placed from the mesenteric border to the abdominal wall at the point of the theoretical stoma.<sup>2,3</sup>

Post-operatively, C-reactive protein and procalcitonin serum levels were monitored on post-operative days 1 and 3, followed by a low pressure rectoscopy on day 4.<sup>1</sup> Based on normal results, the patient started solid intake. At first defecation she had a sudden clinical worsening and an anastomotic leak was suspected. C-reactive protein and procalcitonin were measured and had risen from basal levels, and a sequential rectoscopy and a computed tomography-enterography showed an anastomotic leakage. Therefore, the ghost ileostomy was converted into a diverting ileostomy at an early clinical stage before fecal peritonitis was established and without re-laparotomy.

Ghost ileostomy represents a real option for tailoring the number of diverting ileostomies performed without increasing the morbidity and mortality. It is a reproducible, safe, and low-cost technique.<sup>3,4</sup>

**Twitter** Blanca Segarra-Vidal @BSegarraVidal

**Contributors** All the authors (VL, LS, BS, MF, BF, SD) have actively participated in the work providing input including: (1) substantial contributions to conception and study design, the guarantor in this case is VL; (2) participation in the diagnosis and

treatment, either in the surgery or in the endoscopic detection of anastomotic leak; (3) drafting of the article; and (4) final approval of the version to be published.

**Funding** The authors have not declared a specific grant for this research from any funding agency in the public, commercial or not-for-profit sectors.

**Competing interests** None declared.

**Patient consent for publication** Not applicable.

**Provenance and peer review** Not commissioned; externally peer reviewed.

**Data availability statement** All data relevant to the study are included in the article.

### ORCID iDs

Victor Lago <http://orcid.org/0000-0002-2971-1899>

Lourdes Sala Climent <http://orcid.org/0000-0003-2694-220X>

Blanca Segarra-Vidal <http://orcid.org/0000-0003-3203-0725>

Santiago Domingo <http://orcid.org/0000-0002-8355-3369>

## REFERENCES

- 1 Lago V, Fotopoulou C, Chiantera V, *et al*. Risk factors for anastomotic leakage after colorectal resection in ovarian cancer surgery: a multi-centre study. *Gynecol Oncol* 2019;153:549–54.
- 2 Lago V, Sanchez-Migallón A, Flor B, *et al*. Comparative study of three different managements after colorectal anastomosis in ovarian cancer: conservative management, diverting ileostomy, and ghost ileostomy. *Int J Gynecol Cancer* 2019;29:1170–6.
- 3 Lago V, Flor B, Matute L, *et al*. Ghost ileostomy in advanced ovarian cancer: a reliable option. *Int J Gynecol Cancer* 2018;28:1418–26.
- 4 Lago V, Fotopoulou C, Chiantera V, *et al*. Indications and practice of diverting ileostomy after colorectal resection and anastomosis in ovarian cancer cytoreduction. *Gynecol Oncol* 2020;158:603–7.