

Introduction/Background* Borderline ovarian tumors (BOT) are low malignant potential lesions with a good prognosis that represent around 15% of all epithelial tumors of the ovary. In addition to that, 30% of patients with

BOT are less than 40 years old which makes the preservation of fertility a key point in management.

Molecular studies in ovarian cancer have shown a correlation between the genetic profile of the tumor and the patient's prognosis

Methodology We report the case of a 25-year-old patient, G0P0A0, diagnosed with a mucinous borderline right ovarian tumor back in 2005. In 2009, during a routine control ultrasound, another ovarian cyst was identified on the right side. She was operated again of a cystectomy and peritoneal staging and histopathology confirmed the mucinous nature of the tumor. FIGO stage was IA in both cases. The two blocs of tumors underwent a full exome sequencing technique in order to identify possible key mutations.

Result(s)* Both tumors had variations of EGFR, FGFR3, BRCA1, STK11, NTKR1 and PIK3CA genes. However, the first tumor also had a KRAS mutation that wasn't found in the second lesion four years later. KRAS variants have been shown to be present in low grade ovarian cancer and well-differentiated tumors.

Conclusion* Borderline tumors often recurs in form of borderline tumor but the genetic profile should not be the same as the primary tumor, as shown in our case report. Loss of KRAS could explain the recurrence of the disease. Seeing that the molecular profile of the tumor is in constant change, a continuity in the spectrum normal-benign-borderline-malignant could be hypothesized.

455 PREVENTION OF INCISIONAL HERNIA IN OVARIAN CANCER PATIENTS UNDERGOING MIDLINE LAPAROTOMY

¹B Fabrego Capdevila*, ¹E Miralpeix, ¹JM Sole-Sedeño, ²JA Pereira-Rodriguez, ¹G Mancebo. ¹Hospital del Mar, Department of Obstetrics and Gynecology, Barcelona, Spain; ²Hospital del Mar, Department of Surgery, Barcelona, Spain

10.1136/ijgc-2021-ESGO.405

Introduction/Background* Incisional hernias (IH) are a frequent complication of midline laparotomies in abdominal surgery. This study was conducted in order to determine the efficacy of mesh placement and assess the optimal fascia suture technique to reduce the IH rate in patients surgically treated after being diagnosed with malignant or borderline ovarian tumors.

Methodology Retrospective data from patients undergoing midline laparotomy for borderline or ovarian cancer in Hospital del Mar, Barcelona, from January 2008 to December 2019 were collected. Patient demographic, preoperative and intraoperative characteristics and potential risk factors for hernia were reported. The incidence of IH between groups (mesh and non-mesh) and the technique used in fascial closure for each patient (small bites technique vs large tissue bites) was reported.

Result(s)* In total, 133 patients with available data for follow-up were included. After clinical and radiological examination, 25 (18.79%) of them showed IH. 18 of 61(29.5%) patients in non-mesh group developed IH, compared with 7 of 72 (9.7%) in mesh group (OR 0.25, 95% CI 0.09-0.66,

$p < 0.005$). Patients of large tissue bites group showed higher prevalence of IH compared with small bites technique group without statistical significance (OR 0.46, 95% CI 0.17-1.24, $p = 0.119$). The combination of mesh reinforcement and small bites technique for fascial closure significantly reduce IH risk ($p = 0.021$).

Conclusion* The incidence of IH is high in patients undergoing midline laparotomy for ovarian cancer or borderline ovarian tumor. The addition of a prophylactic mesh and the use of small bites technique may reduce the incidence of IH and potentially minimize the social impact and costs of this complication.

464 MARKERS ON PLATELET MICROVESICLES FOR DIAGNOSTICS OF OVARIAN CANCER

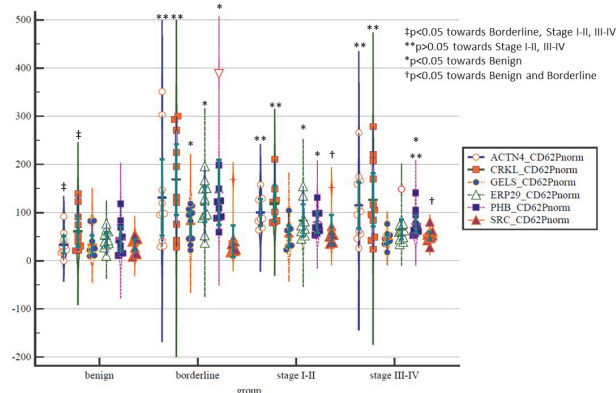
¹E Karlsson, ²F Mobarrez, ³E Epstein, ⁴G Auer, ⁵J Widengren, ¹M Lomnytska*. ¹Uppsala University, Women's and Children's health, Uppsala, Sweden; ²Uppsala University, Department of Medical Sciences, Clinical Chemistry, Uppsala, Sweden; ³Karolinska Institute, Women's and Children's health, Stockholm, Sweden; ⁴Karolinska Institute, Oncology and Pathology, Stockholm, Sweden; ⁵Royal Technical University, Stockholm, Sweden

10.1136/ijgc-2021-ESGO.406

Introduction/Background* Routine blood markers provide poor diagnostic capacity for ovarian cancer. Ultrasound examination using the criteria developed by International Ovarian Tumor Analysis group is the most sensitive and specific diagnostic method, but in up to 20% of cases evaluation is inconclusive (Sladkevicius et al. 2020; Valentin et al. 2011). We pioneered platelet proteome analysis and identified platelet biomarkers of ovarian cancer (Lomnytska et al. 2018).

Methodology The purpose of the study is to identify diagnostic marker panel on platelet microvesicles in blood plasma for non-invasive differential diagnostics of benign adnexal lesions, borderline tumours and ovarian cancer. The expression of platelet protein biomarkers on platelet microvesicles in patients with benign and malignant adnexal lesions was analysed using flow cytometry. Identified biomarker panels were analysed together with the gynaecologic ultrasound criteria.

Result(s)* Analysis comprised 39 patients with benign adnexal lesions (n=10), borderline (n=10), ovarian cancer stage I-II (n=8) and stage III-IV (n=11). Using flow cytometry analysis of platelet microvesicles in platelet-poor blood plasma, we detected our previously identified by proteome analysis of platelets markers ACTN4, CRKL, ERP29, GELS, PHB and SRC



Abstract 464 Figure 1