introduction of letrozole as maintenance therapy. Follow up imaging studies showed no signs of disease progression. At the last check up, the patient was in good condition, without specific complaints.

Result(s)*

Conclusion* Mechanism of EC-AIA is not well understood. As in our case, the tumour can mimic benign uterine lesions and postpone a proper diagnosis. This can lead to advanced stage disease with uncommon clinical presentation. Few studies have described the molecular mechanism of adenomyosis formation. It has been suggested that loss of heterozygosity in the DNA mismatch repair family is associated with adenomyosis and its pathogenesis. Better understanding of the molecular and immunologic drivers of response and resistance will be critical in management of EC-AIA.

864 MINIMALLY INVASIVE VERSUS OPEN HYSTERECTOMY IN HIGH-RISK ENDOMETRIAL CANCER: A PROPENSITY SCORE MATCHING ANALYSIS

[1]B Segarra Vidal*, [2]A Zorrills-Vaca, [3]G Dinoi, [4]V Študent, [5]N Agustí, [6;7]A Llueca, [8]A Mariani, [9]P Ramirez. [1]*Hospital Universitario y Politécnico de La Fe, Gynecologic Oncology, València, Spain*; [2]*MD Anderson Main Building, Houston, USA*; [3]*Gemelli, Roma, Italy*; [4]*Mayo Clinic, Rochester, USA*; [5]*Hospital Clínic de Barcelona, Barcelona, Spain*; [6]*Hospital General Universitari de Castelló, Castelló de la Plana, Spain*; [7]*Gynecology Oncology Unit Hospital General Universitario de Castellon. Departamento de Medicina. Universitat Jaume I (UJI). , Spain*; [8]*Mayo Clinic Rochester MN, Rochester, USA*; [9]*The University of Texas MD Anderson Cancer Center, Houston, USA*

10.1136/ijgc-2021-ESGO.206

Introduction/Background* Randomized trials have shown comparable oncologic outcomes between open versus minimally invasive surgery for endometrial cancer. Limited data is available specifically in patients with high-risk disease. The aim of this study was to compare disease-free survival, overall survival, and recurrence rates between minimally invasive surgery versus open surgery in patients with high-risk endometrial cancer.

Methodology This was a multicentric, propensity score matched study of patients with high-risk endometrial cancer who underwent total abdominal hysterectomy, bilateral salpingo-oophorectomy and staging between January 1999 and June 2016 at two referral cancer centers. High-risk endometrial cancer included uterine grade 3 endometrioid, serous carcinoma, clear cell carcinoma, and undifferentiated carcinoma or carcinosarcoma with any degree of myometrial invasion. Patients were categorized *a priori* into two groups based on the surgical approach, propensity scores were calculated based on potential confounders and then both groups were matched in a 1:1 fashion using the nearest neighbor technique. Cox hazard regression analysis was used to evaluate effect of surgical technique on survival.

Result(s)* A total of 626 patients were eligible, of which 263 patients underwent minimally invasive surgery and 363 open surgery. The median age was 67 years (IQR 60-74), and the median body mass index was 30.5 kg/m^2 (IQR 25.5-35.8). After matching, both groups had 185 matched pairs with comparable demographics and clinical characteristics. In the matched cohort, there were no differences in disease-free survival rates at 5-years between open surgery (53.4% [95%CI 45.6-60.5%]) and minimally invasive surgery (54.6% [95%CI 95% 46.6-61.8]; P=0.82). Minimally invasive surgery was not associated with worse disease-free survival (HR 0.85, 95% CI 0.63 to 1.16; P=0.30), overall survival (HR 1.04, 95% CI 0.73 to 1.48, P=0.81), or recurrence rate (HR 0.99; CI 95% 0.69-1.44; P=0.99) compared to open surgery. Use of uterine manipulator was not associated with worse disease-free survival (HR 1.01, 95% CI 0.65 to 1.58, P=0.96), overall survival (HR 1.18, 95% CI 0.71 to 1.96, P=0.53), or recurrence rate (HR,1.12; CI 95% 0.67 to1.87; P=0.66).

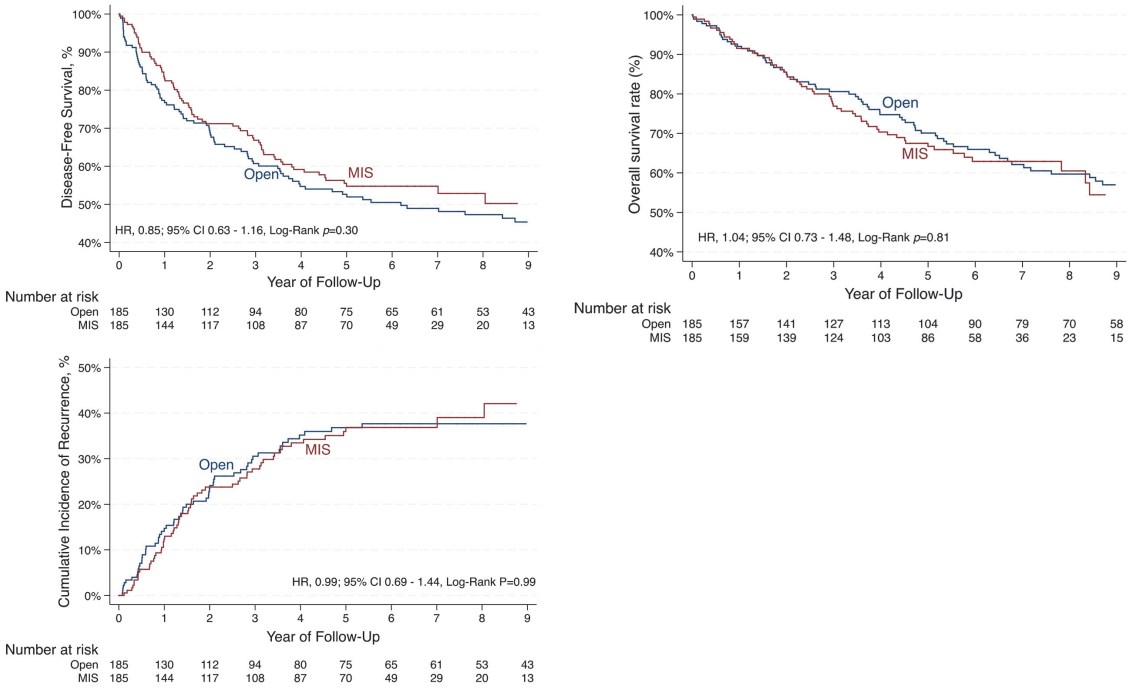

Abstract 864 Figure 1

Conclusion* There was no difference in oncologic outcomes when comparing minimally invasive and open surgery among high-risk endometrial cancer patients

865 EFFECTIVENESS AND SAFETY OF SENTINEL NODE IN ENDOMETRIAL CANCER : REVIEW OF THE LITERATURE

[1]S Petousis*, [2]C Margioula Siarkou, [2]A Papanikolaou, [2]K Dinas, [2]A Daniilidis. [1]*Aristotle University of Thessaloniki*; [2]*Aristotle University of Thessaloniki, 2nd Department of Obstetrics and Gynaecology, Thessaloniki, Greece*

10.1136/ijgc-2021-ESGO.207

Introduction/Background* Main objective of the present study is to discuss the effectiveness and safety of sentinel lymph node in endometrial cancer cases.
Methodology A comprehensive review of published literature in Pubmed, with special focus on meta-analyses and prospective studies, was performed.
Result(s)* Sentinel lymph node (SLN) is indicated for treatment of low and intermediate risk endometrial cancer. Since lymphadenectomy is an important source of morbidity (17.5%) with 2.5% mortality and no proven therapeutic value has been indicated for systematic lymphadenectomy, minimization of approach aims to reduce postoperative morbidity such as lymphedemas. Blood loss, operation time and postoperative complications of SLN are comparable with no lymphadenectomy and significantly decrease compared with systematic lymphadenectomy. SLN detection rates are reported to reach 97% per patient, 87% per hemipelvis and 78% bilaterally. SLNs detected bilaterally are associated with 95.8% sensitivity and over than 98% negative predictive value. Use of SLN strategy is proven to mitigate concern for missed paraaortic micormetastasis, thereafter eliminating risk for postoperative overtreatment. Finally, regarding used regimen, ICG is potentially superior to blue dye as its use was associated with 26.5% increase od SLN dtections rates. Furthermore, a larger dose of ICG is associated with a higher number of retrieved SLNs but not with an increased bilateral DR
Conclusion* SLN is a safe and effective strategy to identify nodal micrometastasis, thereafter optimizing complentary therapy in low and intermediate risk endometrial cancer patients.

872 BLOODLESS MANAGEMENT OF PATIENT UNDERGOING PELVIC EXENTERATION

[1]H Jiang*, [2]V Le Thanh, [3]C Pappa, [3]M Abdalla, [3]S Smyth, [1]H Soleymani Majd. [1]*Churchill Hospital, Gynaeoncology, UK*; [2]*John Radcliffe Hospital, UK*; [3]*Churchill Hospital, UK*

10.1136/ijgc-2021-ESGO.208

Introduction/Background* Blood transfusions are common in the surgical management of gynaecology oncology patients, up to 93% of patients undergoing pelvic exenteration may require blood products. However, increasingly more patients are cautious in receiving blood products, either for fear of potential risks or for religious believes. It is therefore vital to optimize the management of these patients in order to avoid blood transfusions.

We describe the case of a 58-year old female Jehovah's witness patient undergoing pelvic exenteration, focusing on the preoperative, intraoperative and postoperative measures that allowed an uncomplicated surgery without blood transfusion.
Methodology In this case, we summarize the management of a 58-year old lady who underwent laparotomy, pelvic exenteration, Bricker colicureterostomy, end colostomy formation for recurrent endometrial carcinoma, despite previous total abdominal hysterectomy and bilateral salpingo-oophorectomy followed by brachytherapy, chemotherapy and external beam radiotherapy for high grade serous carcinoma.
Result(s)* Preoperatively, an advance decision to refuse blood products was discussed, to ascertain all the options that were suitable. Since her preoperative haemoglobin was acceptable (127 g/L), no further intervention was required. Intraoperatively, blood loss was effectively minimised with meticulous haemostasis, intraoperative haemodilution and cell salvage. Despite these interventions, total blood loss was 1030mL and postoperative haemoglobin was 113 g/L. Postoperative measures therefore included intravenous iron infusion, minimisation of phlebotomy and optimisation of cardiopulmonary status. Erythropoietin was also considered, but was not necessary as patient responded to the previous measures well and was successfully discharged after an uncomplicated recovery.
Conclusion* Only a few cases of total pelvic exenteration have been described in the literature for Jehovah's witness patients. However, our case shows that laparotomy and pelvic exenteration is feasible in patients refusing blood products, if performed under a multidisciplinary team and with careful preoperative, intraoperative and postoperative planning, also in the setting of previous radical hysterectomy and co-adjuvant therapy.

875 ECTOPIC LEFT RENAL ARTERY ORIGINATING FROM LEFT COMMON ILIAC: A RARE ANATOMIC VARIATION

S Petousis*, C Margioula-Siarkou, A Daniilidis, G Mavromatidis, A Papanikolaou, K Dinas. , *2nd Department of Obstetrics and Gynaecology*

10.1136/ijgc-2021-ESGO.209

Introduction/Background* Main objective is to present the case of a rare anatomic variation observed during laparotomy procedure along with performing a relative review of the literature.
Methodology Medical eleents of patient were reviewed with special focus on epidemiological, surgical and histopathological characteristics. A comprehensive review of published literature in Pubmed, with special focus on meta-analyses and prospective studies, was also performed.
Result(s)* A 56-year old woman was operated with laparotomy to peform full surgical staging with total hysterectomy with bilateral salpingoophorectomy, pelvic lymphadenectomy, paraaortic lymphadenectomy and infracolic omentectomy because of initial diagnosis of serous endometrial cancer. During laparotomy procedure, the diagnosis of an ectopic left renal artery (LRA) originating directly from the left common iliac artery (LCIA) was made. Woman was already known to have an ectopic pelvic kidney (EPK). EPK was found in retroperitoneal space, approximately in the level of sigmoidal bend. The LRA indeed originated just 2 cm below the level of bifurcation, while the left renal vein (LRV) was originated relatively from the left iliac vein (LIV) also 2-3 cm below the level of venal bifurcation, having a parallel route just below the LRA.

To our knowledge, this is the first published case of such an anatomical intraoperative finding, which indicates the high complexity degree that may characterize the performance of a para-aortic lymphadenectomy.