Left upper abdomen: surgical anatomy

Santiago Domingo, Tiermes Marina

Gynecologic Oncology, Hospital Universitari i Politecnic La Fe, Valencia, Spain

Correspondence to
Dr Santiago Domingo, Gynecologic Oncology, Hospital Universitari i Politecnic La Fe, Valencia, Spain; santiago.domingo.delpozo@gmail.com

Accepted 1 February 2021

The high burden of disease in the upper abdomen has been a historical limit for achieving a complete cytoreduction in advanced ovarian cancer. Despite its involvement being associated with the biological aggressiveness of the tumor, the achievement of a complete cytoreduction has been associated with long-term survival and should be the surgeon's goal.[1] Even more, the left upper abdomen can be a unique place for relapsed ovarian cancer, and therefore, we should consider these cases for secondary cytoreduction. Unfortunately, surgical complications in this abdominal area should be taken into account, as the impact on quality of life suggests that neoadjuvant chemotherapy in cases with high volume disease could be an alternative to primary debulking surgery.[2]

The surgical anatomy of the upper abdomen should be learned and understood to perform a safe procedure. In particular, the left upper abdomen has two locations that need further surgical considerations: the lesser sac and the spleen.[3]

The lesser sac is a natural space, a 'box', limited dorsally by the body and tail of the pancreas, and caudally by the transversa mesocolon, where the middle colic artery runs. Ventrally, the greater omentum will cover this box, together with the posterior side of the stomach. Finally, the omental bursa will close the lesser sac in the cephalic area. The frame of the box is made by the distal part of the transversa colon and the proximal descendent colon splenic flexure. Laterally, the lesser sac is attached to the parietal peritoneum by the phrenocolic ligament, meanwhile medially we can find the only natural door to the lesser sac, the Winslow hiatus, which is the direct entrance to this complex space.[3 4] The protection against carcinomatosis in this area is known whenever there are surgical adhesions in the upper abdomen (ie, cholecystectomy).[5]

The spleen, as a 'half' intraperitoneal organ, can also be affected by carcinomatosis, particularly in the hilium, although intraparenchimatous metastasis can also be identified.

Concerning the technique,[6] splenectomy has two key points. First the dissection of its attachments, particularly from the splenic flexure of the colon. Second, the vascular supply. The splenic artery runs from the celiac trunk over the cephalic border of the pancreas, being easily identified (Video 1). However, the splenic vein arises from the splenic hilium (Figure 1), usually with several polar veins, and runs through the ventral side of the pancreas, creating the portal system once the inferior and superior mesenteric vein join in. Hence, both vessels run in different pathways, joining in the tail of the pancreas and making a curvature towards the splenic hilum. This is crucial because the tail of the pancreas can be involved in the tumor and should be removed with the spleen.

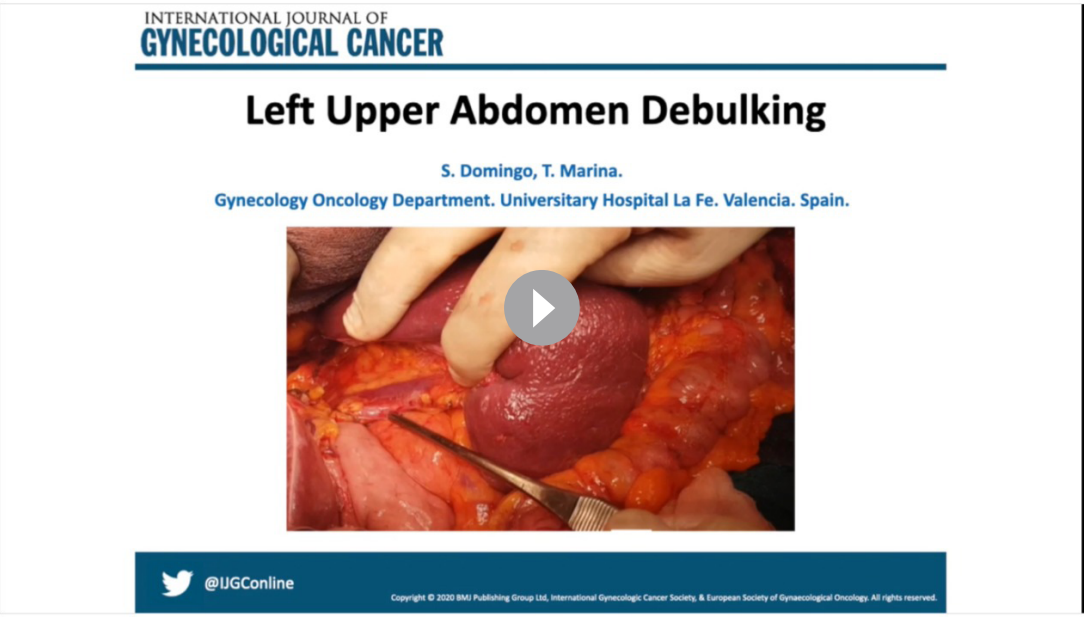

Video 1. Surgical anatomy for the left upper abdomen

To cite: Domingo S, Marina T. *Int J Gynecol Cancer* 2021;31:1190–1191.

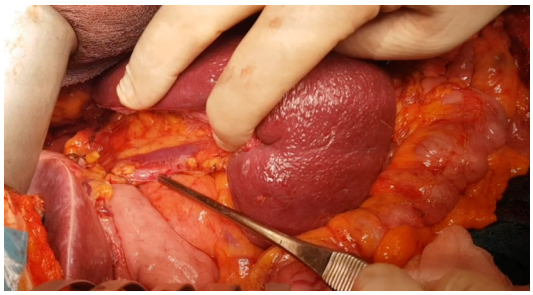

Figure 1 Spleen hilium and vessels exposition.

In this video, we explain the surgical anatomy of this complex abdominal area, describing the vascular supply to the spleen, and moving from imaging to a real surgical case.

Twitter Tiermes Marina @Tiermes

Collaborators Dr Victor Lago, Dr Pablo Padilla, Dr Luís Matute, Dr Marta Gurrea, Dr Alvaro Garcia-Granero, Dr Carlos Domingo.

Contributors SD designed the document and edited the educational video. TM under SD's supervision, wrote the document and helped with the video editing.

Funding The authors have not declared a specific grant for this research from any funding agency in the public, commercial or not-for-profit sectors.

Competing interests None declared.

Patient consent for publication Not required.

Provenance and peer review Not commissioned; externally peer reviewed.

ORCID iDs
Santiago Domingo http://orcid.org/0000-0002-8355-3369
Tiermes Marina http://orcid.org/0000-0002-3307-5346

REFERENCES

1 Zivanovic O, Eisenhauer EL, Zhou Q, *et al*. The impact of bulky upper abdominal disease cephalad to the greater omentum on surgical outcome for stage IIIC epithelial ovarian, fallopian tube, and primary peritoneal cancer. *Gynecol Oncol* 2008;108:287–92.
2 Fagotti A, Ferrandina MG, Vizzielli G, *et al*. Randomized trial of primary debulking surgery versus neoadjuvant chemotherapy for advanced epithelial ovarian cancer (SCORPION-NCT01461850). *Int J Gynecol Cancer* 2020;30:1657–64.
3 Garcia-Granero A, Primo Romaguera V, Millan M, *et al*. A video guide of five access methods to the splenic flexure: the concept of the splenic flexure box. *Surg Endosc* 2020;34:2763–72.
4 Benseler V, Hornung M, Iesalnieks I, *et al*. Different approaches for complete mobilization of the splenic flexure during laparoscopic rectal cancer resection. *Int J Colorectal Dis* 2012;27:1521–9.
5 Kehoe SM, Eisenhauer EL, Chi DS. Upper abdominal surgical procedures: liver mobilization and diaphragm peritonectomy/resection, splenectomy, and distal pancreatectomy. *Gynecol Oncol* 2008;111:S51–5.
6 Ramirez PT, Dos Reis R, dos RR. Splenectomy in patients with advanced or recurrent ovarian cancer: open and laparoscopic surgical techniques and clinical outcomes. *Gynecol Oncol* 2007;104:29–32.