

How to perform a laparoscopic pelvic sentinel lymph node dissection using near-infrared fluorescence with indocyanine green in gynecological cancers

Elie Vésale,¹ Henri Azais,^{1,2} Jérémie Belghiti,¹ Maryam Nikpayam,^{1,2} Catherine Uzan,^{1,2} Geoffroy Canlorbe^{1,2}

► This video is too large to play in the PDF, please visit the full text version online at: <https://ijgc.bmj.com/content/29/2/442>

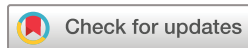¹Department of Gynecologic and Breast Surgery and Oncology, AP-HP, Pitié-Salpêtrière University Hospital, Paris, France

²Sorbonne University, Paris, France

Correspondence to

Henri Azais, Department of Gynecologic and Breast Surgery and Oncology, AP-HP, Pitié-Salpêtrière University Hospital, Paris 75013, France; henriazais@gmail.com

Accepted 12 November 2018
Published Online First
18 January 2019



© IGCS and ESGO 2019. No commercial re-use. See rights and permissions. Published by BMJ.

To cite: Vésale E, Azais H, Belghiti J, et al. *Int J Gynecol Cancer* 2019;**29**:442.

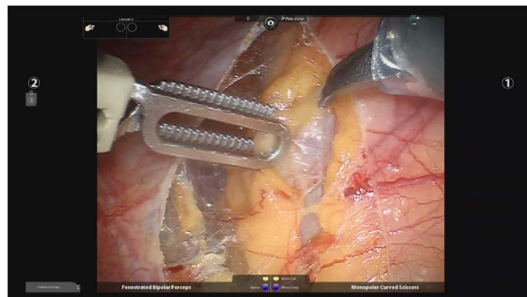
ABSTRACT

The role of pelvic sentinel lymph node dissection (SLND) is increasing in oncological pelvic surgery, especially in the management of cervical and endometrial cancer. SLND using indocyanine green (ICG) is safe and effective, and its sensitivity is higher than with other detection methods. The advantages of ICG are its low toxicity, its confinement within the vascular compartment, its rapid excretion, and the rarity of allergic reaction. These advantages confer to this fluorescent dye a superiority over blue, which can cause anaphylactic reactions. Using ICG does not require advance planning involving nuclear protection and delayed surgery, as are mandatory when using ⁹⁹Tc detection. ICG allows the

surgeon to visualize the lymph nodes through the peritoneum and thus avoid wide dissection.

According to European guidelines,¹ the indications for SLND in cervical cancer are for patients with FIGO (International Federation of Gynecology and Obstetrics) IA1–IA2 disease, lymphovascular space involvement - positive status, without systematic pelvic lymphadenectomy – and patients with FIGO IB1–IIA1 disease, prior to systematic pelvic lymphadenectomy. Guidelines^{1,2} for endometrial cancer management state that SLND is indicated in cases of low-risk endometrial cancer (FIGO IA, grade 1–2), without systematic lymphadenectomy in cases of non-detection, with the technique being preferable to systematic lymphadenectomy in cases of intermediate-risk endometrial cancer (FIGO IB, grade 1–2, or FIGO IA, grade 3).²

Our objective is to review the technique of ICG injection and the real-time detection of pelvic SLNs using near-infrared imaging by means of a step-by-step explanation of the procedure using an instructional [Video 1](#).



Video 1 Technique of indocyanine green injection and real-time detection of pelvic sentinel lymph node using near-infrared imaging.

REFERENCES

1. Cibula D, Pötter R, Planchamp F, et al. The European Society of Gynaecological Oncology/European Society for Radiotherapy and Oncology/European Society of Pathology guidelines for the management of patients with cervical cancer. *Virchows Arch* 2018;472:919–36.
2. Querleu D, Darai E, Lecuru F, et al. [Primary management of endometrial carcinoma. Joint recommendations of the French Society of Gynecologic Oncology (SFOG) and of the French College of Obstetricians and Gynecologists (CNGOF)]. *Gynecol Obstet Fertil Senol* 2017;45:715–25.