

# Video assisted thoracoscopic surgery and its applicability in patients with advanced ovarian cancer

Juan Carlos Muruzábal,<sup>1</sup> Nadia Veiga ,<sup>1</sup> Sara Aguirre,<sup>1</sup> Juan José Guelbenzu,<sup>2</sup> Elena Ramírez<sup>2</sup>

<sup>1</sup>Ginecología Oncológica, Hospital Universitario de Navarra, Pamplona, Navarra, Spain

<sup>2</sup>Cirugía Torácica, Hospital Universitario de Navarra, Pamplona, Navarra, Spain

## Correspondence to

Dr Nadia Veiga, Ginecología, Hospital Universitario de Navarra, Irúnlarrea, 3, 31008, Pamplona, Navarra, Spain; naveigac@gmail.com

Accepted 24 April 2023

In this video article, we present four applications of video assisted thoracoscopic surgery in patients with advanced ovarian cancer:

1. Evaluation and confirmation of pleural disease.
2. Identification and resection of macroscopic suspicious cardio-phrenic lymph nodes.
3. Mediastinal cytoreduction. Resect gross tumor, choosing between primary cytoreduction versus neoadjuvant chemotherapy.
4. Harpoon guided resection of single lung metastases. Possibility of performing a lobectomy in oligo-metastatic disease.

Pleural effusion with positive cytology defines International Federation of Gynecology and Obstetrics stage IVA ovarian cancer and remains an independent variable associated with a worse

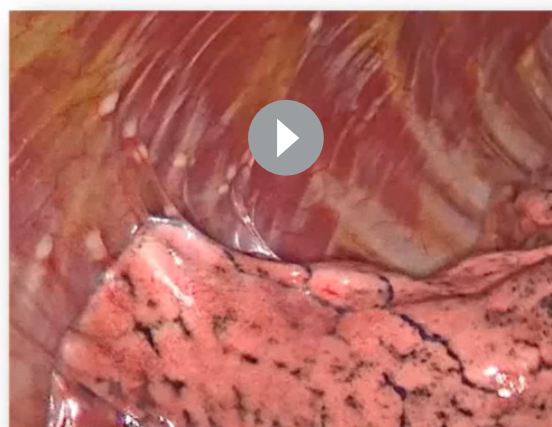prognosis. Analysis of pleural cytology alone is insufficient to assess macroscopic pleural disease. Nearly 30% of patients with negative cytology had gross disease at video assisted thoracoscopic surgery and, conversely, with a positive cytology, no pleural disease is seen.<sup>1,2</sup> In addition, computed tomography features suggestive of pleural malignancy do not always correlate with surgical findings, and the disease can remain undetected on imaging examination.

One indication of video assisted thoracoscopic surgery in patients with ovarian cancer with pleural effusion is to confirm pleural disease that modifies stage and management.<sup>1-3</sup> Although malignant pleural effusions upstage disease, they do not contraindicate an initial cytoreductive abdominal

INTERNATIONAL JOURNAL OF  
**GYNECOLOGICAL CANCER**

## Video-Assisted Thoracoscopic Surgery (VATS) and its applicability in patients with advanced ovarian cancer

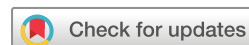J.C Muruzábal, N. Veiga, S. Aguirre, J.J. Guelbenzu, Elena Ramírez



 @IJGOnline

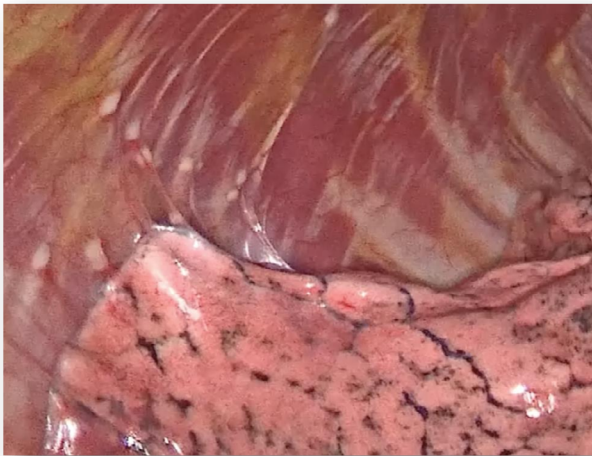
Copyright © 2020 BMJ Publishing Group Ltd, International Gynecologic Cancer Society, & European Society of Gynaecological Oncology. All rights reserved.

**Video 1** Identification and resection of macroscopic suspicious cardio-phrenic lymph nodes.



© IGCS and ESGO 2023. No commercial re-use. See rights and permissions. Published by BMJ.

**To cite:** Muruzábal JC, Veiga N, Aguirre S, et al. *Int J Gynecol Cancer* Published Online First: [please include Day Month Year]. doi:10.1136/ijgc-2023-004359



**Figure 1** Applications of video assisted thoracoscopic surgery in patients with advanced ovarian cancer: evaluation and confirmation of pleural disease.

surgery.<sup>3</sup> Video assisted thoracoscopic surgery can show pleural tumor burden and allows intrathoracic evaluation and resection of enlarged lymph nodes. Also, it allows the removal of macroscopic disease in a primary cytoreduction or, if not feasible, determines patients who would benefit from neoadjuvant chemotherapy.<sup>1-3</sup>

Patients with single lung metastases can be managed by performing a selective lung resection with this procedure. Avoiding the morbidity of an open thoracotomy or the need for extra incisions, port sites could be used for chest tube placement.<sup>4</sup> Video assisted thoracoscopic surgery is described as safe and effective, involving limited additional surgical time.<sup>2-4</sup>

## CONCLUSIONS

- ▶ Video assisted thoracoscopic surgery is useful as a diagnostic, staging, and therapeutic modality in ovarian cancer patients with pleural effusion.
- ▶ Video assisted thoracoscopic surgery can evaluate suitable patients for surgical cytoreduction or neoadjuvant chemotherapy.
- ▶ It is a secure and useful procedure, which can determine disease in negative computed tomography images, evaluate patients with poor tolerance/response to chemotherapy, and even resect oligometastatic disease.

**Correction notice** All data relevant to the study are included in the article.

**Contributors** Video article conception and design: JCM, NV. Draft manuscript preparation: NV. All authors reviewed the results and approved the final version. JCM is responsible for the overall content as guarantor.

**Funding** The authors have not declared a specific grant for this research from any funding agency in the public, commercial, or not-for-profit sectors.

**Competing interests** None declared.

**Patient consent for publication** Consent obtained directly from patient(s).

**Ethics approval** This study involves human participants and participants gave informed consent to participate in the study before taking part.

**Provenance and peer review** Not commissioned; externally peer reviewed.

## ORCID iD

Nadia Veiga <http://orcid.org/0000-0002-5761-5781>

## REFERENCES

- 1 Porcel JM, Murata P, Porcel L, *et al.* Prevalence, clinical characteristics, and outcome of pleural effusions in ovarian cancer. *Pleura Peritoneum* 2021;6:75–81.
- 2 Di Guilmi J, Salvo G, Mehran R, *et al.* Role of video-assisted thoracoscopy in advanced ovarian cancer: a literature review. *Int J Gynecol Cancer* 2016;26:801–6.
- 3 Boerner T, Filippova OT, Chi AJ, *et al.* Video-assisted thoracic surgery in the primary management of advanced ovarian carcinoma with moderate to large pleural effusions: a Memorial Sloan Kettering Cancer Center team ovary study. *Gynecol Oncol* 2020;159:66–71.
- 4 Whitworth JM, Schneider KE, Fauci JM, *et al.* Outcomes of patients with gynecologic malignancies undergoing video-assisted thoracoscopic surgery (VATS) and pleurodesis for malignant pleural effusion. *Gynecol Oncol* 2012;125:646–8.