







# Laparoscopic posterior pelvic exenteration using the abdominal perineal resection (APR) technique for management of tumor invading both vagina and rectum

Qidi Jiang , Mo Chen , Lei Yuan , Liangqing Yao 

Department of Gynecologic Oncology, Obstetrics and Gynecology Hospital of Fudan University, Shanghai, China

## Correspondence to

Dr Liangqing Yao, Obstetrics and Gynecology Hospital of Fudan University, Shanghai, Shanghai, China; yaoliangqing@163.com

Accepted 5 April 2023

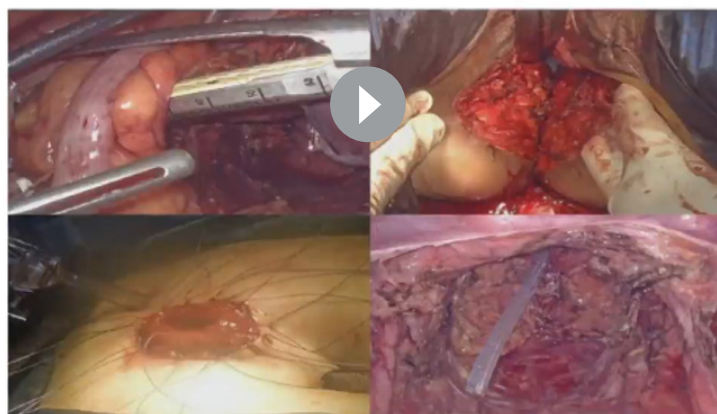Laparoscopic posterior exenteration is a complex and rarely done procedure. This technique enables en bloc resection of the vagina and rectum via a small incision. Because of the high risk of morbidity, most posterior exenteration terminates above the levator ani muscle.<sup>1</sup> Abdominal perineal resection (APR) is widely used for the management of rectal cancer and anal canal cancer, but it has broader applications.<sup>2,3</sup> In [Video 1](#), we demonstrate how we combined the abdominal perineal resection technique with laparoscopic posterior exenteration for radical management of a vaginal malignant tumor that had invaded the rectum.


A 40-year-old woman was referred to our hospital because of irregular bleeding and defecation from the vagina. Colposcopy showed a 5 cm tumor on the lower third of the posterior wall of the vagina. Biopsy of the vagina and rectum both suggested adenocarcinoma of the tumor, possibly originating from the vagina. Colonoscopy showed that the tumor had occupied half of the lumen and also revealed a tiny fistula opening to the vagina. No other macroscopic tumors around the abdomen or in the retroperitoneal space or elsewhere in the body were identified by positron emission tomography/computed tomography (PET/CT). After obtaining informed consent, we

INTERNATIONAL JOURNAL OF  
**GYNECOLOGICAL CANCER**

## Laparoscopic posterior pelvic exenteration using abdominal perineal resection (APR) technique for management of tumor invading both vagina and rectum

Qidi Jiang, Mo Chen, Lei Yuan, Liangqing Yao



 @IJGOnline

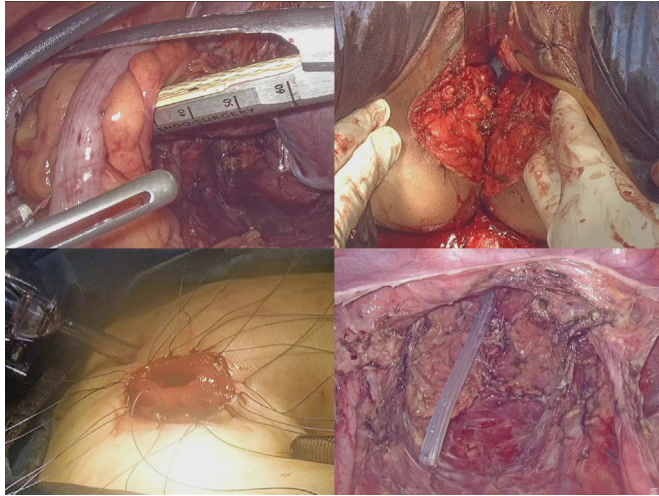
Copyright © 2020 BMJ Publishing Group Ltd, International Gynecologic Cancer Society, & European Society of Gynaecological Oncology. All rights reserved.

**Video 1** Laparoscopic posterior pelvic exenteration using the abdominal perineal resection (APR) technique for management of a vaginal tumor

 Check for updates

© IGCS and ESGO 2023. No commercial re-use. See rights and permissions. Published by BMJ.

**To cite:** Jiang Q, Chen M, Yuan L, *et al.* *Int J Gynecol Cancer* Published Online First: [please include Day Month Year]. doi:10.1136/ijgc-2023-004283



**Figure 1** Hybrid image illustrating the key surgical techniques employed. Upper left image: sigmoid colon transected by an endoscopic linear cutter. Upper right image: complete resection and removal of the vagina, uterus, and rectum as a whole from the perineum. Lower left image: view showing how the terminal colostomy was performed. Lower right image: abdomen after en bloc resection of the vagina, uterus, and rectum.

performed posterior exenteration in the patient. First, the vagina and rectum were dissociated to the level of the levator ani under laparoscopy. Next, we performed perineal resection, which included operating from the perineum and cutting through the levator ani to meet with the intra-abdominal part of the vagina and rectum. The bilateral cut edge of the levator ani and adipose tissue were then closed with sutures. Finally, we performed terminal colostomy using the proximal end of the sigmoid colon.

The whole surgery was performed by gynecological oncologists without assistance from gastrointestinal surgeons. The uterus, vagina, rectum, and anus were resected as a whole. The

surgery lasted for 5 hours and 50 min. There were no major post-operative complications. The pathology confirmed adenocarcinoma of vaginal origin. The patient received 28 fractions of radiotherapy and four cycles of adjuvant chemotherapy after surgery. To date, the follow-up after surgery has been 18 months. Our video shows that en bloc posterior pelvic exenteration performed by gynecologic oncologists using minimally invasive technology combined with perineal resection is feasible and safe. This technique can be used for tumors invading both the vagina and rectum.

**Contributors** QJ wrote and edited the video article. MC reviewed the article and narration. LeY and LiY performed the surgery. LiY is responsible for the overall content as guarantor.

**Funding** The authors have not declared a specific grant for this research from any funding agency in the public, commercial or not-for-profit sectors.

**Competing interests** None declared.

**Patient consent for publication** Not applicable.

**Ethics approval** Not applicable.

**Provenance and peer review** Not commissioned; externally peer reviewed.

**Data availability statement** All data relevant to the study are included in the article.

#### ORCID iDs

Qidi Jiang <http://orcid.org/0000-0002-4400-245X>

Mo Chen <http://orcid.org/0000-0001-5207-9679>

Lei Yuan <http://orcid.org/0000-0002-7516-2819>

Liangqing Yao <http://orcid.org/0000-0002-0554-8257>

#### REFERENCES

- 1 Moukarzel LA, Chi DS. Posterior pelvic exenteration, a crucial component in the surgeon's toolbox for optimizing surgical cytoreduction for advanced ovarian cancer. *J Gynecol Oncol* 2022;33:e41.
- 2 Hawkins AT, Albutt K, Wise PE, et al. Abdominoperineal resection for rectal cancer in the twenty-first century: indications, techniques, and outcomes. *J Gastrointest Surg* 2018;22:1477–87.
- 3 Gavrilă D, Bitere O, Droc G, et al. Abdominoperineal resection for rectal cancer: open, laparoscopic or robotic approach. *Chirurgia (Bucur)* 2021;116:7:573–82.: