





Rectovaginal fistula repair by Martius flap after exclusive chemoradiation in a patient with advanced cervical cancer

Vito Andrea Capozzi , Isabella Rotondella, Alessandra De Finis , Elisa Scarpelli, Tullio Ghi, Roberto Berretta

Department of Medicine and Surgery, University Hospital of Parma, Parma, Italy

Correspondence to
Dr Alessandra De Finis,
University of Parma, 43121
Parma, Italy; alessandra.
definis@unipr.it

Accepted 3 March 2023

INTRODUCTION

Rectovaginal fistula (RVF) is an abnormal connection between the rectum and vagina. Common causes are pelvic irradiation, obstetric trauma, Crohn's disease, and post-surgical complications. Conservative treatments are usually performed in patients unfit for surgery and are characterized by a high recurrence rate. A common surgical approach includes fistula debridement and repair or flap interposition. Simple anatomic fistula repair is associated with a lower success rate than vascularized flap interposition. The Martius flap is a vascularized muscle-adipose flap obtained from the bulbocavernosus muscle.¹ The blood supply is provided by branches of the pudendal artery. RVF repair by Martius flap is a safe procedure which offers good cosmetic and functional results, improving wound healing through neovascularization. Before surgery, a protective ileostomy is usually required.

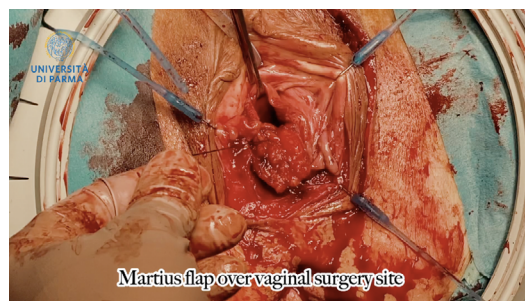


Figure 1 Martius flap over the vaginal surgery site.

CASE PRESENTATION

A 72-year-old woman with squamous cervical cancer, International Federation of Gynecology and Obstetrics stage IIB, was treated by exclusive chemoradiation at our department. After 3 years of negative follow-up, the patient was hospitalized for fecal vaginal discharge. Gynecological examination showed an

INTERNATIONAL JOURNAL OF
GYNECOLOGICAL CANCER

Rectovaginal fistula repair by Martius flap after exclusive chemoradiation in advanced cervical cancer patient. A case report

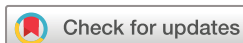Vito Andrea Capozzi¹, Isabella Rotondella¹, Alessandra De Finis¹, Elisa Scarpelli¹, Tullio Ghi¹, Roberto Berretta¹
¹Department of Medicine and surgery, University Hospital of Parma, Parma, 43125, Italy



 @IJGOnline

Copyright © 2023 BMJ Publishing Group Ltd, International Gynecologic Cancer Society, & European Society of Gynecological Oncology. All rights reserved.

Video 1 Surgical procedure step-by-step of a rectovaginal fistula repair by Martius flap in a woman with squamous cervical cancer treated by exclusive chemoradiation.



© IGCS and ESGO 2023. No commercial re-use. See rights and permissions. Published by BMJ.

To cite: Capozzi VA, Rotondella I, De Finis A, *et al.* *Int J Gynecol Cancer* Published Online First: [please include Day Month Year]. doi:10.1136/ijgc-2023-004365

Video article

RVF between the lower third of the posterior vaginal wall and the rectum. Colonoscopy confirmed the presence of an RVF of 2–3 mm diameter. Previous conservative treatments were ineffective. Therefore, after ileostomy, surgical treatment with a Martius flap was attempted. The surgical steps were as follows: (1) laterolabial skin incision; (2) labial dissection to identify the muscle-adipose flap; (3) mobilization of the flap; (4) opening of the lateral vaginal tunnel; (5) clamping of the superior pedicle; (6) transfer of the Martius flap to the vagina (Figure 1); (7) suture of the Martius flap over the vaginal surgical site; and (8) suture of the subcutaneous layer and skin. Amoxicillin, clavulanic acid, and metronidazole were administered 30 min before and continued for 7 days after surgery.

RESULTS

The post-operative course was uncomplicated. After 6 months follow-up, no recurrence of RVF was observed. The patient reported a greatly improved quality of life.

CONCLUSION

The MF is an effective and safe procedure for RVF repair.

Contributors All authors discussed the results and contributed to the final manuscript. VAC is responsible for the overall content as guarantor.

Funding The authors have not declared a specific grant for this research from any funding agency in the public, commercial or not-for-profit sectors.

Competing interests None declared.

Patient consent for publication Not applicable.

Provenance and peer review Not commissioned; internally peer reviewed.

ORCID iDs

Vito Andrea Capozzi <http://orcid.org/0000-0003-4720-5663>

Alessandra De Finis <http://orcid.org/0000-0003-2664-5424>

REFERENCE

- 1 Wilson A, Pillay S, Greenwell T. How and why to take a Martius labial interposition flap in female urology. *Transl Androl Urol* 2017;6(Suppl 2):S81–7.