A variation of laparoscopic ovarian transposition: the ovarian pedicle suspension (PS technique)

Paul I Stanciu , Malcolm L Padwick

Gynaecological Oncology Department, West Hertfordshire Teaching Hospitals NHS Trust, Watford, UK

Correspondence to
Paul I Stanciu, Gynaecological Oncology Department, West Hertfordshire Teaching Hospitals NHS Trust, Watford WD18 0HB, UK; paulstanciu.md@gmail.com

Accepted 7 September 2022

To cite: Stanciu PI, Padwick ML. *Int J Gynecol Cancer* Published Online First: [please include Day Month Year]. doi:10.1136/ijgc-2022-003789

SUMMARY

Laparoscopic ovarian transposition has already been proven to be a safe and effective procedure to preserve ovarian function in patients receiving pelvic radiotherapy for a variety of gynecological malignancies with high success rates.[1 2]

The aim of this video is to present our *PS technique* for Laparoscopic Ovarian Transposition, a reproducible new technique of ovarian transposition that inflicts minimal damage on the ovaries while at the same time places them outside the irradiation fields for pelvic malignancies.

A 32-year-old nulliparous patient with International Federation of Gynecology and Obstetrics (FIGO) stage 1B3 poorly differentiated squamous cell carcinoma of the cervix was referred to our department for ovarian transposition before receiving radical chemoradiation. Laparoscopy was performed as usual using a 10 mm umbilical optic port and four 5 mm ports placed in both iliac fossae and high in both flanks. Bilateral prophylactic salpingectomy was performed and specimens were sent for histology. Both pelvic side walls were opened and both ureters were identified. Both utero-ovarian ligaments were transected along

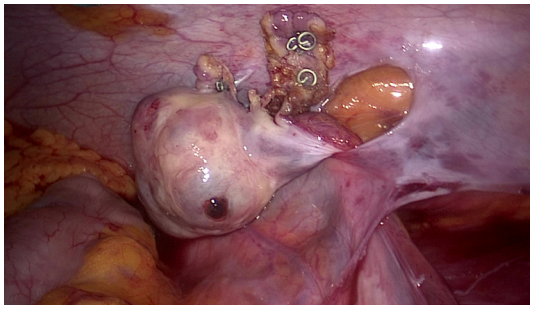

Figure 1 Laparoscopic ovarian transposition: PS technique. PS, pedicle suspension.

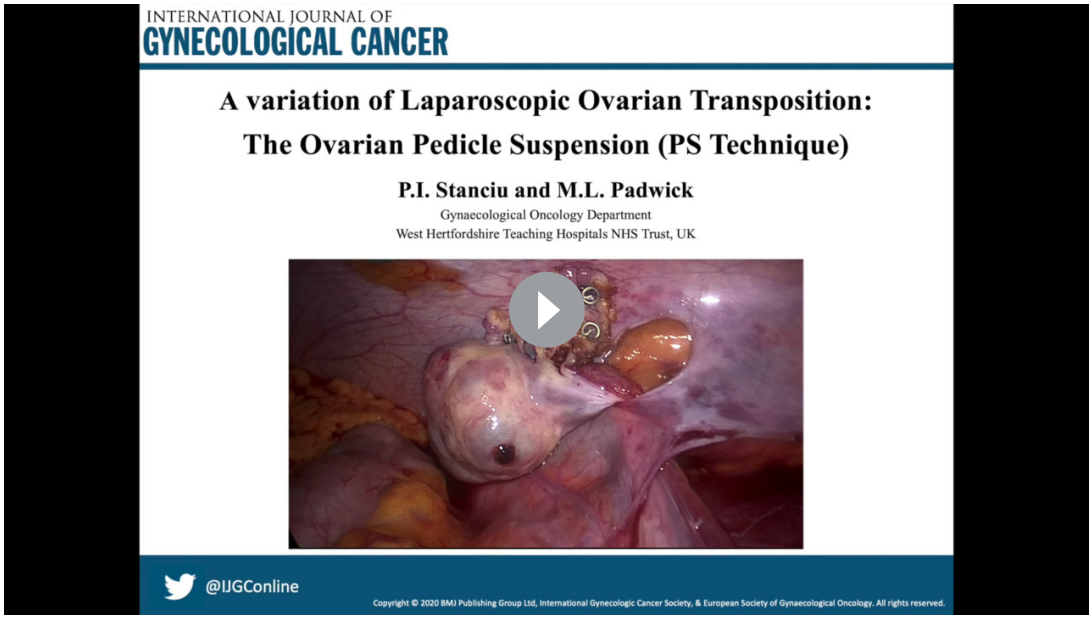

Video 1 In this video article we present an original variation of laparoscopic ovarian transposition that is easily reproducible. Our technique describes the creation of bilateral ovarian flaps after detaching the ovaries from the uterus along with 2 cm of round ligament on each side. This is followed by a good mobilization and fixation of the ovaries outside the traditional irradiation fields of the pelvis.

with 2 cm of round ligament on both sides in order to create the ovarian flaps. The flaps were mobilized and the infundibulopelvic ligaments were skeletonized. The para-colic gutters were incised approximatively 10 cm above the pelvic brim and tunneled. Both ovarian flaps were pulled through these tunnels and were stapled outside the irradiation fields. Titanium staples were used to prevent the flaps from falling back into the pelvis after the procedure and for easy identification of the ovaries on imaging. At the end of the procedure, both ovarian pedicles were tension-free with good mobility and minimal risk of necrosis or torsion. Both ovaries were outside the planned radiation field. There were no intra-operative complications and the patient experienced a good recovery.

In a 10-year retrospective study, Swift et al demonstrated a high success rate of ovarian function preservation after using a comparable technique.[3] Furthermore, we believe that our innovative ovarian flap allows the ovaries to have a degree of natural movement and at the same time prevents torsion and minimizes damage associated with the use of transfixed stitches. A prospective series to assess the outcomes will follow.

Acknowledgements We would like to thank Dr Maria Oikonomou for helping with video editing.

Contributors Contributors: PIS and MLP performed the surgery. PIS edited the video article. Both authors read and approved the final draft. PIS is responsible for the entire content of this video article as guarantor.

Funding The authors have not declared a specific grant for this research from any funding agency in the public, commercial or not-for-profit sectors.

Competing interests None declared.

Patient consent for publication Consent obtained directly from patient(s)

Ethics approval This study involves a human participant who gave informed consent to participate in the study before taking part.

Provenance and peer review Not commissioned; externally peer reviewed.

Data availability statement All data relevant to the study are included in the article.

ORCID iD
Paul I Stanciu http://orcid.org/0000-0003-1005-1939

REFERENCES

1 Gubbala K, Laios A, Gallos I, *et al*. Outcomes of ovarian transposition in gynaecological cancers; a systematic review and meta-analysis. *J Ovarian Res* 2014;7:69.
2 Pahisa J, Martínez-Román S, Martínez-Zamora MA, *et al*. Laparoscopic ovarian transposition in patients with early cervical cancer. *Int J Gynecol Cancer* 2008;18:584–9.
3 Swift BE, Leung E, Vicus D, *et al*. Laparoscopic ovarian transposition prior to pelvic radiation for gynecologic cancer. *Gynecol Oncol Rep* 2018;24:78–82.