

Aggressive angiomyxoma of the pelvis and vagina: a robotic and vaginal combined approach

Ana Luzarraga Aznar ¹, Asunción Perez-Benavente, ¹ Vicente Bebia, ¹ Natalia R Gómez-Hidalgo ², Silvia Cabrera, ¹ Antonio Gil-Moreno ^{3,4}

¹Gynecologic Oncology, Hospital Vall d'Hebron, Barcelona, Spain

²Gynecologic oncology, Vall d'Hebron Hospital, Barcelona, Spain

³Gynecology Oncology Department, Universitat Autònoma de Barcelona, Barcelona, Spain

⁴Hospital Vall d'Hebron, Barcelona, Catalunya, Spain

Correspondence to

Dr Ana Luzarraga Aznar, Gynecologic Oncology, Hospital Vall d'Hebron, 08035 Barcelona, Spain; aluzarraga7@gmail.com

Accepted 30 November 2022

Published Online First
15 December 2022

Aggressive angiomyxoma is a rare mesenchymal tumor, typically arising in the soft tissue of the pelvis and perineum, ¹ with local aggressive behavior and frequent local recurrence. Surgical excision is the standard treatment, and it is especially relevant to acquire negative pathologic margins to reduce the local relapse. ²

We report the case of a 47 year-old woman diagnosed with an aggressive angiomyxoma of the pelvis and perineum. A magnetic resonance imaging (MRI) scan revealed a 9cm infiltrative mass at the level of the lateral wall of the left introitus, extending to the left infravesical space, lateral wall of the vagina and anal sphincter, infiltrating the levator ani muscle and the ischioanal fossa. A surgical treatment was performed consisting first of a robotic approach with standard five-port placement configuration. The surgical strategy initially consisted of the development of the lateral avascular spaces of the left pelvis. The first maneuver involved the detachment of the tumor from the obturator fossa and left lateral wall of

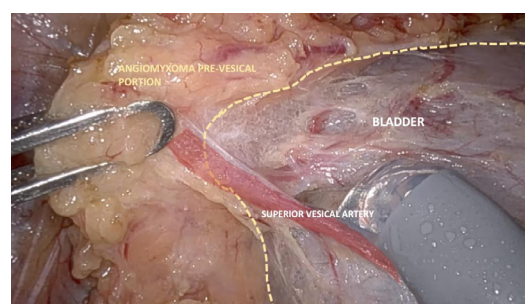
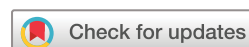

Figure 1 Bladder detachment of the pre-vesical portion of the aggressive angiomyxoma.

the bladder by developing also the medial paravesical space. Then, development of the Retzius space up to the bladder neck was achieved to identify the pre-vesical portion of the tumor. The use of intravenous indocyanine green helped us to identify the anatomical plane for the detachment of the tumor from the bladder. Next, a vaginal approach with a longitudinal incision was performed, enabling us to identify



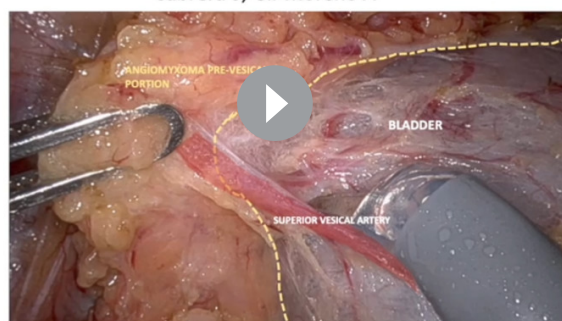
© IGCS and ESGO 2023. No commercial re-use. See rights and permissions. Published by BMJ.

To cite: Luzarraga Aznar A, Perez-Benavente A, Bebia V, et al. *Int J Gynecol Cancer* 2023;33:839–840.

INTERNATIONAL JOURNAL OF
GYNECOLOGICAL CANCER

Aggressive angiomyxoma of the pelvis and perineum: a robotic and vaginal combined approach

Luzarraga A, Pérez-Benavente A, Bebia V, Rodríguez Gómez-Hidalgo N, Cabrera S, Gil-Moreno A



@IJGOnline

Copyright © 2023 BMJ Publishing Group Ltd, International Gynecologic Cancer Society, & European Society of Gynecological Oncology. All rights reserved.

Video 1

Video article

the ischiatic tuberosity, ischiocavernosus, bulbocavernosus, and perineum transversus muscles. The ischioanal fossa was developed and the tumor exteriorized. Detachment of the aggressive angiomyxoma from the lateral wall of the vagina and rectum enabled the excision of the surgical specimen.

The patient was discharged 4 days later and 2 weeks later she was diagnosed with an infection of the vulvar wound which was treated with intravenous antibiotics and a negative pressure therapy.

Twitter Vicente Bebia @lebeche

Contributors AG-M, AP-B, NRG-H performed the surgery. ALA realized the edition of the video article. VB contributed to the edition of the video article. AG-M, AP-B, NRG-H and VB and SC made the final revisions of the video article and manuscript. ALA is the guarantor.

Funding The authors have not declared a specific grant for this research from any funding agency in the public, commercial or not-for-profit sectors.

Competing interests None declared.

Patient consent for publication Consent obtained directly from patient(s)

Ethics approval This study involves human participants and was approved by the Clinical Research Ethics Committee at the Hospital Universitari Vall d'Hebron from Barcelona. The patient gave her consent for the use of the images of the surgery for its publication.

Provenance and peer review Not commissioned; externally peer reviewed.

Data availability statement All data relevant to the study are included in the article.

ORCID iDs

Ana Luzarraga Aznar <http://orcid.org/0000-0001-6007-0308>

Natalia R Gómez-Hidalgo <http://orcid.org/0000-0003-3217-0453>

REFERENCES

- 1 Peterknecht E, Agerbak E, Mohamedahmed A, *et al.* Aggressive angiomyxoma of the ischioanal fossa in a post-menopausal woman. *Ann R Coll Surg Engl* 2021;103:e59–64.
- 2 Kelley SR. Robotic extralevator excision of a retrorectal giant aggressive angiomyxoma. *Obstet Gynecol Sci* 2018;61.