



# Sentinel lymph node detection in early-stage ovarian cancer: a systematic review and meta-analysis

Nuria Agusti <sup>1,2</sup> David Viveros-Carreño <sup>1,3,4</sup> Carlos Grillo-Ardila,<sup>5</sup> Nora Izquierdo,<sup>1</sup> Pilar Paredes,<sup>6,7,8</sup> Sergi Vidal-Sicart <sup>6,7</sup> Aureli Torne <sup>1,7,8</sup> Berta Díaz-Feijoo <sup>1,7,8</sup>

► Additional supplemental material is published online only. To view, please visit the journal online (<http://dx.doi.org/10.1136/ijgc-2023-004572>).

For numbered affiliations see end of article.

## Correspondence to

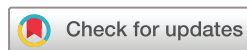Dr Nuria Agusti, Department of Gynecologic Oncology and Reproductive Medicine, The University of Texas MD Anderson Cancer Center, Houston, TX 77030, USA; [NAgusti@mdanderson.org](mailto:NAgusti@mdanderson.org)

Received 18 April 2023

Accepted 10 July 2023

Published Online First

24 July 2023



© IGCS and ESGO 2023. No commercial re-use. See rights and permissions. Published by BMJ.

**To cite:** Agusti N, Viveros-Carreño D, Grillo-Ardila C, *et al.* *Int J Gynecol Cancer* 2023;**33**:1493–1501.

## ABSTRACT

**Background** A systematic pelvic and para-aortic lymphadenectomy remains the surgical standard management of early-stage epithelial ovarian cancer. Sentinel lymph node mapping is being investigated as an alternative procedure; however, data reporting sentinel lymph node performance are heterogeneous and limited.

**Objective** This study aimed to evaluate the detection rate and diagnostic accuracy of sentinel lymph node mapping in patients with early-stage ovarian cancer.

**Methods** A systematic search was conducted in Medline (through PubMed), Embase, Scopus, and the Cochrane Library. We included patients with clinical stage I–II ovarian cancer undergoing a sentinel lymph node biopsy and a pelvic and para-aortic lymphadenectomy as a reference standard. We conducted a meta-analysis for the detection rates and measures of diagnostic accuracy and assessed the risk of bias using the Quality Assessment of Diagnostic Accuracy Studies 2 tool. The study was registered in the International Prospective Register of Systematic Reviews (PROSPERO) with identifying number CRD42022351497.

**Results** After duplicate removal, we identified 540 studies, 18 were assessed for eligibility, and nine studies including 113 patients were analyzed. The pooled detection rates were 93.3% per patient (95% CI 77.8% to 100%;  $I^2=74.3\%$ ,  $p<0.0001$ ), and the sentinel lymph node technique correctly identified 11 of 12 patients with lymph node metastases, with a negative predictive value per patient of 100% (95% CI 97.6% to 100%;  $I^2=0\%$ ). The combination of indocyanine green and  $^{99m}\text{Tc}$ -albumin nanocolloid had the best detection rate (100% (95% CI 94% to 100%;  $I^2=0\%$ )) when injected into the utero-ovarian and infundibulo-pelvic ligaments.

**Conclusion** Sentinel lymph node biopsy in early-stage ovarian cancer showed a high detection rate and negative predictive value. The utero-ovarian and infundibulo-pelvic injection using the indocyanine green and technetium-99 combination could increase sentinel lymph node detection rates. However, given the limited quality of evidence and the small number of reports, results from ongoing trials are awaited before its implementation in routine clinical practice.

## INTRODUCTION

Ovarian cancer is mainly diagnosed at an advanced stage (International Federation of Gynecology and Obstetrics (FIGO) stage III or IV) and only 20% to

## WHAT IS ALREADY KNOWN ON THIS TOPIC

⇒ The sentinel lymph node technique in apparently early-stage ovarian cancer is an experimental procedure in which multiple tracers, injection methods, and technical procedures have been described. No previous literature has been published analyzing the diagnostic accuracy of the procedure.

## WHAT THIS STUDY ADDS

⇒ This review provides data on sentinel lymph node detection and diagnostic accuracy in patients with early-stage ovarian cancer, including information on which tracer, injection site, and type of surgery showed better detection rates. The utero-ovarian and infundibulo-pelvic injection using the indocyanine green and technetium-99 combination could increase sentinel lymph node detection rates.

## HOW THIS STUDY MIGHT AFFECT RESEARCH, PRACTICE, OR POLICY

⇒ The sentinel lymph node technique has shown a high detection rate and negative predictive value in patients with early-stage ovarian cancer. However, the evidence is limited, and information is relatively scarce. This review might be a reference for future studies with well-defined protocols and consideration of oncologic outcomes is required before implementing sentinel lymph node detection in routine clinical practice for ovarian cancer.

30% of patients with ovarian cancer are diagnosed with clinically early-stage (FIGO stage I–II) disease at initial evaluation.<sup>1</sup> A comprehensive staging surgery, including a systematic pelvic and para-aortic lymphadenectomy, remains the standard surgical management of patients with early-stage epithelial ovarian cancer to determine the prognosis and need for adjuvant treatment.<sup>2</sup> However, the incidence of lymph node involvement is about 15–20%.<sup>3</sup> Performing a lymphadenectomy is an invasive and laborious technique, associated with intra-operative and post-operative morbidity, and has a negative impact on the quality of life.<sup>3</sup> Additionally, no evidence suggests a possible therapeutic value of systematic lymphadenectomy.<sup>4</sup>

## Original research

Over the past decade, sentinel lymph node (SLN) mapping has emerged as an alternative technique to identify lymph node metastases while reducing the surgical morbidity associated with systematic lymphadenectomies. The SLN mapping technique has proved accurate in other gynecological cancers.<sup>5–8</sup> Nevertheless, its application in ovarian cancer is challenging since the tracer injection technique and the ovarian lymphatic drainage are more complex than for other gynecological tumors.

Few studies with a limited number of patients have been published and heterogeneously reported the feasibility of ovarian SLN mapping.<sup>9–11</sup> Some aspects remain to be resolved regarding the use of tracers, the injection site, the detection rate according to the technique used, and the diagnostic accuracy. A detailed evaluation of the factors and the consequences of applying different methods of SLN detection and why variation might occur in early-stage ovarian cancer has not been assessed. The objectives of this systematic review and meta-analysis were to assess the detection rate and diagnostic accuracy of SLN mapping in the staging of patients with early-stage ovarian cancer who had undergone full pelvic and para-aortic lymphadenectomy as the reference standard.

## METHODS

The protocol was prospectively registered with the International Prospective Register of Systematic Reviews (PROSPERO) under identifying number CRD42022351497, and the systematic review was conducted according to the Preferred Reporting Items for Systematic Review and Meta-Analysis (PRISMA).<sup>12</sup>

### Eligibility Criteria

Inclusion criteria were studies performing the SLN mapping technique in patients diagnosed with early-stage (FIGO I-II) ovarian cancer and reporting the detection rate and diagnostic accuracy who had undergone full pelvic and para-aortic lymphadenectomy. All ages, histological tumor types, grades, surgical access, and all sentinel node detection techniques were allowed.

We excluded patients with benign ovarian pathology, borderline tumors or absence of ovarian pathology, non-human articles, case series, video articles, review articles, editorial letters, and abstracts. When two or more manuscripts were published using the same data source, only the most complete manuscript was included.

### Information Sources and Search Strategy

A systematic literature search was performed using Medline (through PubMed), Embase, Scopus, and Cochrane Library from inception to September 1, 2022. The search strategy is reported in the supplementary material (Online supplemental appendix table 1). The electronic search was supplemented by evaluating the reference lists of the included studies. We limited articles to the English, Spanish, Italian, and French language, but search strategies were created with English terms only.

### Study Selection and Data Collection Process

Rayyan software (Qatar Computing Research Institute, HBKU, Doha, Qatar) was used for the title and abstract screening for eligibility and, after the removal of duplicates, all citations were reviewed independently by two reviewers (NA and NI) at two stages (titles and abstract, and full-text review). Disagreements were resolved

by discussion between the reviewers. Reasons for exclusion were recorded.

Data collection included: author, publication year, country, sample size, study period, type of surgery, surgical approach, reference standard, SLN technique (injection site, type of tracer, timing, and dose), SLN outcomes (diagnostic accuracy and detection rate), SLN ultrastaging performance, and adverse events. The corresponding author was contacted to obtain missing data, if needed.

We will provide our data for independent analysis by a selected team or for additional data analysis or for the reproducibility of this study in other centers, if such is requested.

## Outcomes

The primary outcomes were the overall detection rate of SLN defined as the proportion of individuals with at least one SLN detected, and the diagnostic accuracy of SLN for the staging of patients with ovarian cancer who had undergone complete pelvic and para-aortic lymphadenectomy as a reference standard. The secondary outcome was to analyze factors related to the SLN mapping detection rate and diagnostic accuracy. The specific detection rate was analyzed depending on (1) tracers used, (2) injection site, and (3) type of surgery.

## Assessment of Risk of Bias

The risk of bias were assessed independently by two reviewers (NA and DV-C) using the Quality Assessment of Diagnostic Accuracy Studies 2 (QUADAS-2) tool.<sup>13</sup> The risk of bias was assessed for the following domains: patient selection, index test, reference standard, and flow and timing. The risk of bias was judged as 'low', 'high', or 'unclear' in each domain.

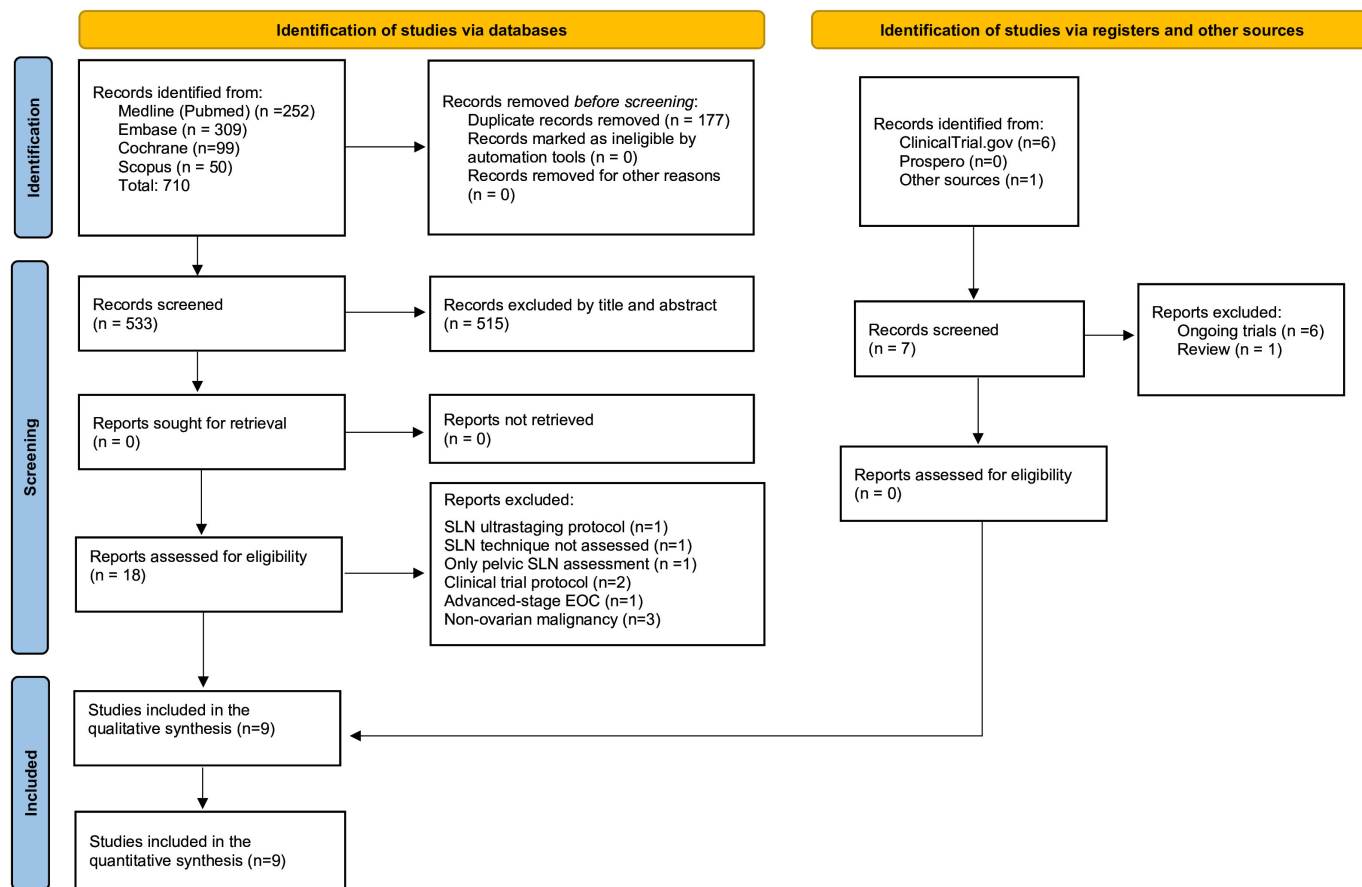
## Analysis and Data Synthesis

Data were presented as means or medians for quantitative variables based on the distribution of the data, which has been tested using the Smirnov–Kolmogorov test. Categorical variables were represented using relative frequencies (percentages). P values were reported using the  $\chi^2$  or Fisher's exact test in categorical variables according to the sample size in each subgroup. We used Stata 14.0 (StataCorp, College Station, Texas, USA) and JBI SUMARI (The University of Adelaide, Australia) to conduct the meta-analysis. Given the expected heterogeneity, a random-effects model was used. We calculated predictive value estimates from the extracted data.

## RESULTS

### Study Selection

The initial search identified 717 manuscripts. Seven manuscripts were identified via registries and manual searching, and citation tracking. After removing duplicate manuscripts 540 studies were evaluated. Following title and abstract screening, 18 articles were selected for full-text screening. Of the 18 full-text articles, nine were excluded<sup>14–22</sup> and finally, nine articles were included.<sup>23–31</sup> Reasons for exclusion are outlined in (Online supplemental appendix table 2). The PRISMA flow diagram shows the complete review process from the original search to the final selection (Figure 1).



**Figure 1** Preferred Reporting Items for Systematic reviews and Meta-Analysis (PRISMA) flow diagram. EOC, epithelial ovarian cancer; SLN, sentinel lymph node.

## Study Characteristics

A total of 113 patients were included. The studies were conducted between 2014 to 2021. The median age was reported in seven studies,<sup>19 20 22 24–27</sup> ranging from 45 to 57. Median body mass index was reported in five studies,<sup>19 20 25–27</sup> ranging from 20.5 to 25.2 kg/m<sup>2</sup>. Six studies<sup>24–28 31</sup> were considered observational, and three<sup>23 29 30</sup> were clinical trials. Five studies included a total of 58 patients without ovarian cancer, and those patients were excluded from the analysis (3 patients with cervical cancer, 1 with a concomitant endometrial cancer, 10 with borderline ovarian tumors, and 44 patients with benign tumors). The most common tracer used in the studies was indocyanine green (ICG) in 61 patients (54%), followed by the <sup>99m</sup>Tc in 51 patients (45.1%) and blue dye in 23 patients (20.4%). The tracers were used either as a single agent or in combination. The main characteristics of the included studies are presented in Table 1.

## Risk of Bias of Included Studies

The quality assessment of the included studies is presented in Online supplemental appendix figure 1. Most studies were at low risk of bias in the patient selection, index test, and reference standard domains. Three studies<sup>26 28 31</sup> were at unclear risk of bias in the patient selection domain because consecutive recruitment was not well specified. One study<sup>29</sup> was also at an unclear risk of bias in the standard reference domain because it was unclear if a complete systematic lymphadenectomy was performed.

## SYNTHESIS OF RESULTS

### Overall SLN Detection Rate

At least one SLN was detected in 94 (83.2%) of 113 patients. The SLN detection rate was 93.3% (95% CI 77.8% to 100%;  $p < 0.0001$ ;  $I^2 = 74.3\%$ ) and ranged from 27% to 100% in individual studies (Figure 2). Seven studies<sup>23–26 28–30</sup> including 76 patients described the location drainage: in 67 patients (88.2%) a SLN was detected in the aortic region (in 32 patients (42.1%) the drainage was only aortic and in 35 (46.1%) the drainage was present in pelvic and aortic regions). In 9 (11.8%) patients, only pelvic SLN were detected.

### Diagnostic Accuracy Analysis

The SLN technique correctly identified 11 (91.7%) of 12 patients with lymph node metastases. Para-aortic lymph node involvement was reported in nine patients,<sup>23 24 26 27</sup> pelvic involvement in two patients,<sup>23 24</sup> and both pelvic and aortic involvement in one patient.<sup>26</sup> The pooled negative predictive value per patient was 100% (95% CI 97.6% to 100%;  $p = 0.97$ ;  $I^2 = 0\%$ ) (Figure 3). An ultrastaging protocol was used in 5 (41.7%) of 12 patients with lymph node metastases, finding two SLNs with isolated tumor cells and four SLNs with macro-metastasis.<sup>18 23</sup>

### Type of Tracers

ICG alone was used in three studies,<sup>19 24 28</sup> including 43 patients (38%), and blue dye alone in one study<sup>27</sup> with 11 patients (9.7%), showing a detection rate of 90.5% (95% CI 61.5% to 100%;

**Table 1** Characteristics of the included studies

Author, year; country	Sample size*	Study period	Type of surgery	Surgical approach	Injection site	Tracer used and dose	Time between injection and detection	SLN ultrastaging
Kleppe et al <sup>25</sup> 2014; Netherlands	5	October 2012 to June 2014	PSS	LPT	UO and IP ligaments	0.2–0.5 mL of Tc-99m albumin nanocolloid and blue dye (each injection)	15 min	Yes
Hassanzadeh et al <sup>26</sup> 2016; Iran	13	January 2010 to October 2014	PSS	LPT	UO and IP ligaments (n=10); Cortex (n=3)	0.2 mL of Tc-99m phytate+blue dye (each injection)	10 min	NS
Angelucci et al <sup>28</sup> 2016; Italy	5	April 2016 to May 2016	PSS	MIS	Hilum of ovary	0.5–1 mL of ICG, (1.25 mg/mL)	2 min	NS
Buda et al <sup>31</sup> 2017; Italy	7	NR	PSS	MIS	UO and IP ligaments	0.5 to 1 mL of ICG (1.25 mg/mL)	Real time	NS
Uccella et al <sup>23</sup> 2019; Italy	31	March 2018 - ongoing	PSS and DSS	MIS	UO and IP ligaments (after adnexectomy)	2 mL of ICG (1.25 mg/mL)	5–20 min	Yes
Lago et al <sup>24</sup> 2018; Spain	10	March 2017 to February 2018	PSS and DSS	MIS+LPT	UO and IP ligaments (after adnexectomy)	0.2 mL of Tc-99m albumin colloid (37 MBq) + 0.5 mL of ICG (1.25 mg/mL)	15 min	Yes
Lago et al <sup>30</sup> 2020; Spain	20	March 2018 to July 2019	PSS and DSS	MIS+LPT	UO and IP ligaments (after adnexectomy)	0.2 mL of Tc-99m albumin colloid (37 MBq) + 0.5 mL of ICG (1.25 mg/mL)	15 min	Yes†
Laven et al <sup>29</sup> 2021; Netherlands	11	NR	PSS and DSS	LPT	UO and IP ligaments (after adnexectomy)	0.15 mL of Tc-99m albumin nanocolloid (20 MBq) + 0.2 mL blue dye	15 min	Yes
Guerra <sup>27</sup> 2021; Venezuela	28	June 2016 to November 2019	DSS	LPT	UO and IP ligaments	0.5 mL of Isosulfan (UO ligament) + 2 mL (IP ligament)	15 min	NS

\*Refers only to patients with malignant ovarian cancer.  
†Ultrastaging protocol was applied a second time.<sup>40</sup>  
DSS, delayed or restaging surgery; ICG, indocyanine green; IP, Infundibulo-pelvic; LPT, laparotomy; MIS, minimal invasive surgery; NR, not reported; NS, not specified; PSS, primary staging surgery; SLN, sentinel lymph node; UO, utero-ovarian.

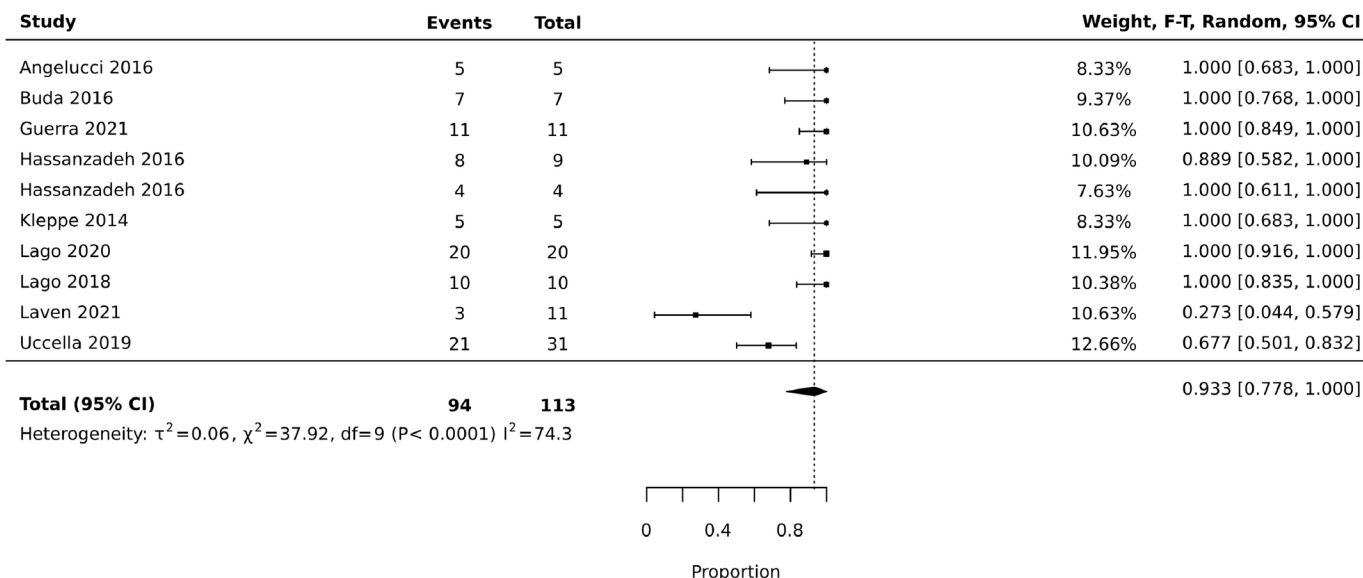
$I^2=65.9\%$ ) and 100% (95% CI 84.9% to 100%;  $I^2=0\%$ ), respectively (Figure 4).

<sup>99m</sup>Tc was used alone in nine patients (8%)<sup>26</sup> with a detection rate of 88.9% (95% CI 58.2% to 100%;  $I^2=0\%$ ) and in combination with patent blue in 20 patients (17.7%)<sup>25 26 29</sup> or in combination with ICG in 30 patients (26.5%),<sup>24 30</sup> with a detection rate of 80.9% (95% CI 22.1% to 100%;  $I^2=82.5\%$ ) and 100% (95% CI 94% to 100%;  $I^2=0\%$ ), respectively. There was no statistically significant difference when the heterogeneity source was explored by tracer type ( $p=0.54$ ). The waiting time between the injection of the marker and the detection of SLN reported by most studies averaged 10–15 min (Table 1), except for those studies that only used ICG alone, which followed the migration of the tracer immediately after injection.

### Injection Site and Surgical Technique

The most used injection site was the infundibulo-pelvic and utero-ovarian ligament (if no previous hysterectomy had been performed) in eight studies, including 105 patients (92.2%), on the ipsilateral side of the tumor, or bilaterally when both ovaries were involved. However, other injection sites were described: one study,<sup>26</sup> including three patients (2.7%), performed the tracer injection on the ovarian cortex; and another study<sup>28</sup> including five patients (4.4%), used the hilum of the ovary, the broad ligament, and the ovarian parenchyma as the site of injection.

The pooled SLN detection rate when the injection site was in the ovarian ligaments was 92.9% (95% CI 73.7% to 100%;  $I^2=80.5\%$ ) in comparison with other injection sites with a pooled detection rate



**Figure 2** Forest plot showing the overall detection rate.

of 88.5% (95% CI 42.6% to 100%;  $I^2=7.4\%$ ). This difference was not statistically significant ( $p=0.61$ ) (Online supplemental appendix figure 2).

In 33 (29.2%) patients the injection was performed in the ovarian ligaments with the mass still in situ<sup>25–27 31</sup> and, in 47 (41.6%) patients in the ovarian ligaments stumps of the removed adnexa, just after the frozen section report of malignancy. Lastly, in 25 (22.1%) patients, the injection was performed<sup>23 29 30</sup> in the ovarian ligament stumps during a re-staging intervention surgery. The pooled detection rate was 98.9% (95% CI 89.8% to 100%;  $I^2=0\%$ ), 89.7% (95% CI 58.3% to 100%;  $I^2=84.7\%$ ), and 78.9% (95% CI 6.7% to 100%;  $I^2=95\%$ ), respectively (Online supplemental appendix figure 3). There was no statistically significant difference when the heterogeneity source was explored ( $p=0.72$ ).

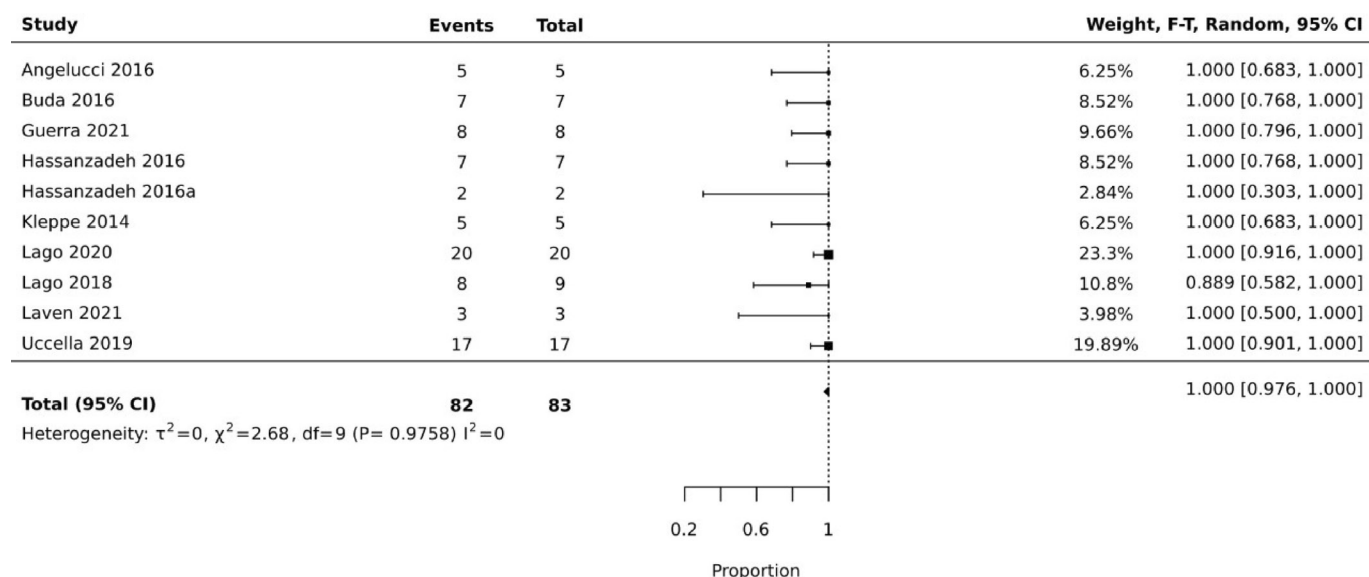
### Complications

No complications were reported for the tracer injection. Three studies<sup>23 24 30</sup> described a vascular injury related to the lymphadenectomy and not the SLN dissection.

### DISCUSSION

#### Summary of Main Results

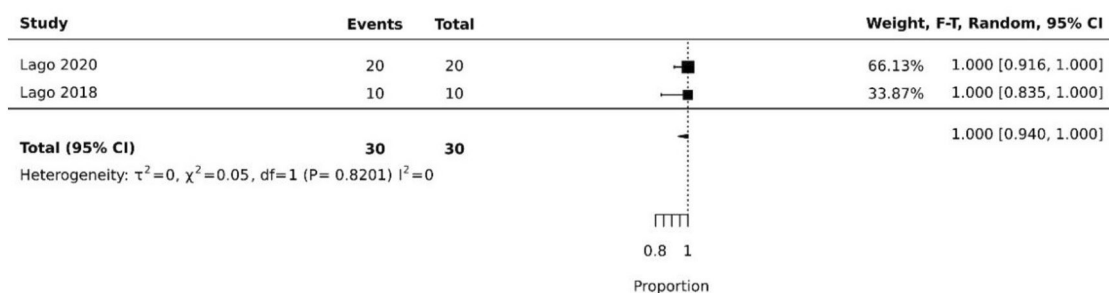
SLN mapping was associated with a high detection rate (93.3%) and negative predictive value (100%) in patients with early-stage ovarian cancer. The individual detection rate from the included studies varied widely, ranging from 27% to 100%. The combination of both tracers ICG and <sup>99m</sup>Tc resulted in the best detection rate when injected into the ovarian ligaments before the adnexectomy, as was blue dye, but with few patients. The 92% pooled detection



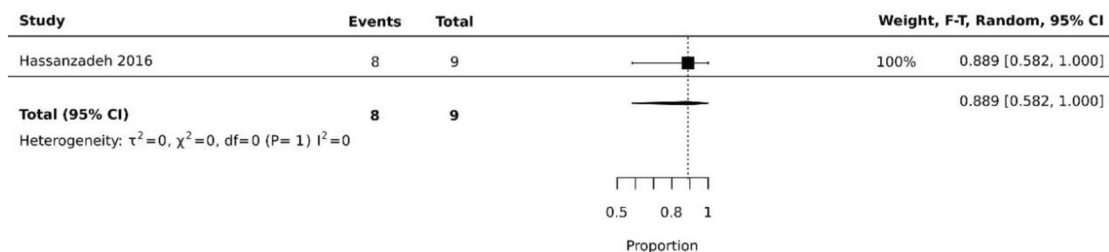
**Figure 3** Forest plot showing the negative predictive value.

Original research

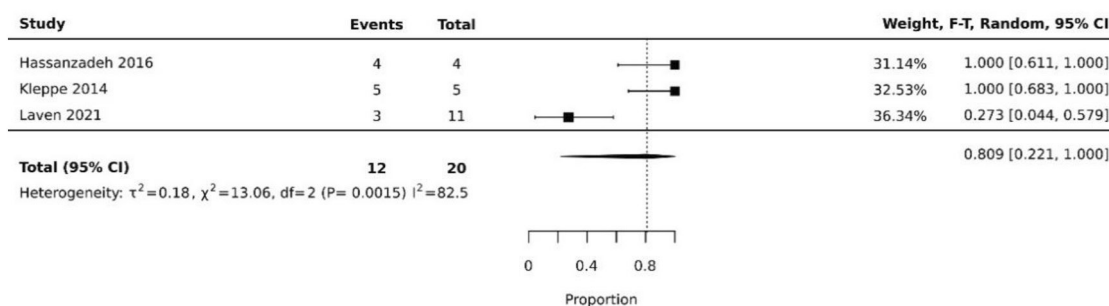
**A Indocyanine green and [<sup>99m</sup>Tc]Tc-albumin nanocolloid**



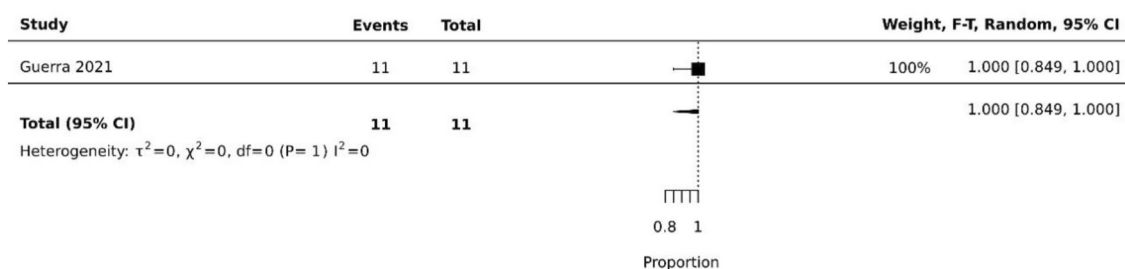
**B [<sup>99m</sup>Tc]Tc-albumin nanocolloid**



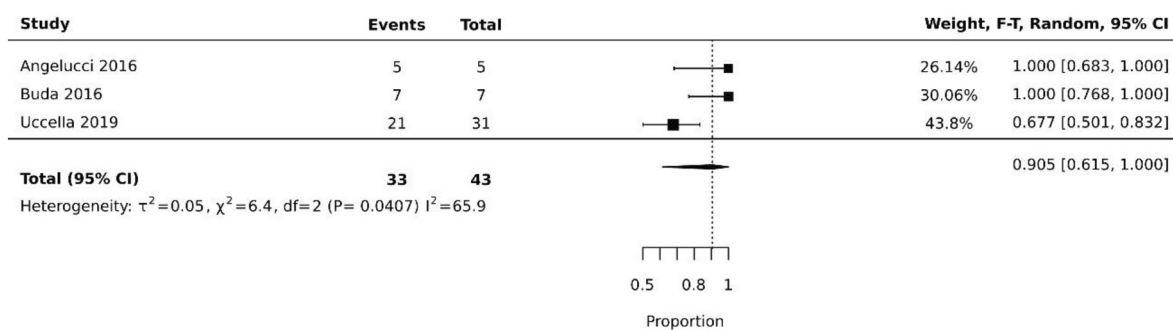
**C [<sup>99m</sup>Tc]Tc-albumin nanocolloid and blue dye**



**D Blue dye**



**E Indocyanine green**



**Figure 4** Forest plot showing the detection rate depending on the type of tracers used.

rate is comparable with that observed in other gynecological neoplasia like cervical or endometrial cancer.<sup>5 7 8</sup>

### Results in the Context of Published Literature

SLN mapping in patients with early-stage ovarian cancer is an experimental procedure in which multiple tracers, injection methods, and technical procedures have been described. No previous meta-analysis on SLN detection in patients with early-stage ovarian cancer has been previously published. Some reviews<sup>9–11</sup> have included a miscellany of benign and malignant pathology. Only one meta-analysis regarding SLN of the ovary by Ataei et al was previously published,<sup>11</sup> but included information based on an abstract data, and analyzed a widely heterogeneous population, such as patients with both malignant and benign ovarian tumors, other concomitant gynecological tumors, or patients operated for other reasons. This broad selection of patients might lead to a biased conclusion.

According to the two main lymphatic pathways, most of the studies performed a tracer injection into the ovarian ligaments showing a high pooled detection rate. Other injection sites have been described, such as the ovarian cortex, but it might be risky due to a possible tumor spillage and dissemination.<sup>26</sup> We found a substantial heterogeneity among used tracers. The interest in use of ICG as a single agent is its easy detection. However, the combination of ICG and <sup>99m</sup>Tc was better in our pooled analyses, although results are just based on one study group.<sup>24 30</sup> Interestingly, the ICG and <sup>99m</sup>Tc combination has been relatively underexplored when considering other neoplasias<sup>32</sup> and may enhance the advantages of both tracers in patients with ovarian cancer.<sup>33</sup>

Another controversial issue is the optimal time to inject the tracer. Up to five studies<sup>25–28 31</sup> achieved a high detection rate of 98.9% injecting the tracer into the ovarian ligaments prior to the tumor removal, hypothetically the ideal injection time since the lymphatic pathways have not yet been disrupted. Alternatively, four studies<sup>23 24 29 30</sup> assessed the feasibility of performing a tracer injection into the ovarian ligaments' stumps, right after the adnexa removal and malignancy confirmation, to avoid an unnecessary injection when the intra-operative pathology shows benign histology. In this setting, the pooled detection rate was lower, showing conflicting results among the studies. This discrepancy could be related to the surgical technique and the different tracers used among the studies. Additionally, the high detection rate presented by Lago et al could be due to the fact that the injection was performed deep and close to the dorsal/lateral parametrium,<sup>34</sup> resulting in tracing uterine lymphatic pathways and obtaining a very high pelvic detection rate.

Performing SLN mapping in patients undergoing a restaging surgery is controversial since the pathways of lymphatic vessels might be altered and the SLN should reflect the distorted manipulated and fibrous tissue. Lago et al<sup>30</sup> argue that lymphatic drainage still persists after the adnexectomy in a unidirectional flow from the ovarian ligament stumps to the para-aortic and pelvic fields, respectively. However, Uccella et al and Laven et al showed more discouraging results.<sup>23 29</sup>

As reported in the literature,<sup>35 36</sup> the para-aortic route was the main lymphatic spread. Conversely, the detection rate in the pelvic region was lower. A possible reason could be the retroperitoneal pelvic extravasation when injecting the tracer, hindering subsequent

SLN detection. In order to increase pelvic detection rate, Uccella et al<sup>19</sup> proposed to assess the concordance between two theoretically different lymphatic pathways by performing a cervical injection with ICG and utero-ovarian ligament injection with blue dye in patients with endometrial cancer. Interestingly, they found the same pelvic SLN in all cases with both tracers, suggesting that the two injection sites might be equivalent.

The pooled negative predictive value was 100%. This is probably the best estimate to consider regarding SLN diagnostic accuracy since the main expected benefit of SLN clinical application in patients with early-stage ovarian cancer is to avoid unnecessary systematic lymphadenectomy in node-negative cases. The missing metastasis was in a patient that had a metastatic lymph node in the aortic region in whom no para-aortic SLN was identified, and a pelvic SLN was found as negative.<sup>24</sup> As already described in other cancer sites,<sup>37</sup> applying a well-defined SLN mapping algorithm going beyond the removal of only the detected SLN could increase the sensitivity and decrease the false-negative rate. Therefore, it seems essential to define the ovarian lymphatic drainage pathways as well as a specific algorithm, such as performing a lymphadenectomy in cases of no drainage in a specific anatomical region.<sup>2 38</sup>

The MELISA trial,<sup>39</sup> SELLY trial,<sup>40</sup> and TRSGO-SLN-005<sup>41</sup> are three ongoing trials that aim to evaluate the detection rate and diagnostic accuracy of the SLN in early-stage ovarian cancer (Online supplemental appendix table 2c).

### Strengths and Weaknesses

The strength of this review is the rigorous methodology applied. It has a registered protocol, and was conducted following the guidelines for reporting systematic reviews. Strict selection criteria focused only on the population with early-stage ovarian cancer, and an adequate reference standard with the pelvic and para-aortic lymph node dissection was used to reduce the risk of biases and heterogeneity. Finally, published tools to assess methodological quality and risk of bias were considered for analyses.

We recognize several limitations, such as the inclusion of different types of studies and the limited sample size from only nine included manuscripts, limiting the conclusions regarding diagnostic accuracy, and the subgroup analysis to draw consistent conclusions. Moreover, we found substantial clinical heterogeneity among the studies regarding the tracers used and the technique for injection.

### Implications for Practice and Further Research

The SLN technique is considered the standard of care for other gynecologic cancers. Our review showed that SLN mapping resulted in a high detection rate and negative predictive value in patients with early-stage ovarian cancer and provides information on which tracer, injection site, and type of surgery performed better. Although evidence is still limited, this study synthesizes the current SLN data in patients with ovarian cancer and might be a reference for the design of future studies before considering the technique in a clinical setting.

### CONCLUSIONS

SLN mapping in patients with early-stage ovarian cancer showed a high detection rate and negative predictive value. SLN mapping is a surgical procedure under investigation in

the management of select patients with early-stage ovarian cancer. However, given the low quality of available evidence, results from future prospective trials are awaited before its implementation in routine clinical practice.

#### Author affiliations

- <sup>1</sup>Gynecology Oncology Unit, Institute Clinic of Gynecology, Obstetrics, and Neonatology, Hospital Clinic of Barcelona, Barcelona, Spain  
<sup>2</sup>Department of Gynecologic Oncology and Reproductive Medicine, The University of Texas MD Anderson Cancer Center, Houston, Texas, USA  
<sup>3</sup>Department of Gynecologic Oncology, Instituto Nacional de Cancerología, Bogotá, Colombia, Bogotá, Colombia  
<sup>4</sup>Department of Gynecologic Oncology, Clínica Universitaria Colombia and Centro de Tratamiento e Investigación sobre Cáncer Luis Carlos Sarmiento Angulo - CTIC, Bogotá, Colombia  
<sup>5</sup>Department of Gynecology and Obstetrics, Universidad Nacional de Colombia - Sede Bogotá, Bogotá, Colombia  
<sup>6</sup>Department of Nuclear Medicine, Hospital Clinic de Barcelona, Barcelona, Spain  
<sup>7</sup>IDIBAPS, Barcelona, Spain  
<sup>8</sup>Faculty of Medicine, University of Barcelona, Barcelona, Spain

**Correction notice** This article has been corrected since it was first published. A duplication error in the Objective section of the Abstract has been fixed.

**Twitter** Nuria Agusti @nagustiga and Berta Díaz-Feijoo @Bertadiazfeijoo#

**Contributors** NA is the principal investigator, designed the study, reviewed the literature, collected and analyzed data, and wrote the paper. DV-C contributed to conceptualizing the project, independently screening and assessing all studies, and edited the manuscript. CG contributed to conceptualizing the project and statistical assistance. NI contributed to independently screening and assessing all studies, and edited the manuscript. PP and SV-S contributed to conceptualizing the project and edited the manuscript. AT and BD-F contributed to conceptualizing the project, consulted for clinical expertise, reviewed the data and analyses, and edited the manuscript. NA is the guarantor and accepts full responsibility for the work and/or the conduct of the study, had access to the data, and controlled the decision to publish.

**Funding** The authors have not declared a specific grant for this research from any funding agency in the public, commercial or not-for-profit sectors.

**Competing interests** None declared.

**Patient consent for publication** Not applicable.

**Ethics approval** Not applicable.

**Provenance and peer review** Not commissioned; externally peer reviewed.

**Data availability statement** Data are available upon reasonable request. All data relevant to the study are included in the article or uploaded as supplementary information.

**Supplemental material** This content has been supplied by the author(s). It has not been vetted by BMJ Publishing Group Limited (BMJ) and may not have been peer-reviewed. Any opinions or recommendations discussed are solely those of the author(s) and are not endorsed by BMJ. BMJ disclaims all liability and responsibility arising from any reliance placed on the content. Where the content includes any translated material, BMJ does not warrant the accuracy and reliability of the translations (including but not limited to local regulations, clinical guidelines, terminology, drug names and drug dosages), and is not responsible for any error and/or omissions arising from translation and adaptation or otherwise.

#### ORCID iDs

Nuria Agusti <http://orcid.org/0000-0002-1165-0661>  
 David Viveros-Carreño <http://orcid.org/0000-0001-9395-0627>  
 Sergi Vidal-Sicart <http://orcid.org/0000-0002-6303-3606>  
 Aureli Torne <http://orcid.org/0000-0003-4700-9507>  
 Berta Díaz-Feijoo <http://orcid.org/0000-0002-6451-1817>

#### REFERENCES

- Torre LA, Trabert B, DeSantis CE, et al. Ovarian cancer statistics. *CA Cancer J Clin* 2018;68:284–96.

- Colombo N, Sessa C, du Bois A, et al. ESMO-ESGO consensus conference recommendations on ovarian cancer: pathology and molecular biology, early and advanced stages, borderline tumours and recurrent disease†. *Ann Oncol* 2019;30:672–705.
- van de Vorst R, Hoogendam JP, van der Aa MA, et al. The attributive value of comprehensive surgical staging in clinically early-stage epithelial ovarian carcinoma: a systematic review and meta-analysis. *Gynecol Oncol* 2021;161:876–83.
- Bizzarri N, du Bois A, Fruscio R, et al. Is there any therapeutic role of pelvic and para-aortic lymphadenectomy in apparent early stage epithelial ovarian cancer? *Gynecol Oncol* 2021;160:56–63.
- Levenback CF, Ali S, Coleman RL, et al. Lymphatic mapping and sentinel lymph node biopsy in women with squamous cell carcinoma of the vulva: a gynecologic oncology group study. *J Clin Oncol* 2012;30:3786–91.
- Mansel RE, Fallowfield L, Kissin M, et al. Randomized multicenter trial of sentinel node biopsy versus standard axillary treatment in operable breast cancer: the ALMANAC trial. *J Natl Cancer Inst* 2006;98:599–609.
- Lécuru F, Mathevet P, Querleu D, et al. Bilateral negative sentinel nodes accurately predict absence of lymph node metastasis in early cervical cancer: results of the SENTICOL study. *J Clin Oncol* 2011;29:1686–91.
- Darai E, Dubernard G, Bats A-S, et al. Sentinel node biopsy for the management of early stage endometrial cancer: long-term results of the SENTI-ENDO study. *Gynecol Oncol* 2015;136:54–9.
- Balescu I, Bacalbasa N, Vilcu M, et al. Sentinel lymph node in early stage ovarian cancer; a literature review. *J Mind Med Sci* 2018;5:184–8.
- Dell'Orto F, Laven P, Delle Marchette M, et al. Feasibility of sentinel lymph node mapping of the ovary: a systematic review. *Int J Gynecol Cancer* 2019;29:1209–15.
- Ataei Nakhaei S, Mostafavi SM, Farazestanian M, et al. Feasibility of sentinel lymph node mapping in ovarian tumors: a systematic review and meta-analysis of the literature. *Front Med (Lausanne)* 2022;9:950717.
- Page MJ, McKenzie JE, Bossuyt PM, et al. The PRISMA 2020 statement: an updated guideline for reporting systematic reviews. *BMJ* 2021;372:n71.
- Whiting PF, Rutjes AWS, Westwood ME, et al. QUADAS-2: a revised tool for the quality assessment of diagnostic accuracy studies. *Ann Intern Med* 2011;155:529–36.
- Kleppe M, Van Gorp T, Slangen BFM, et al. Sentinel node in ovarian cancer: study protocol for a phase 1 study. *Trials* 2013;14:47.
- Pop C-F, Veys I, Gomez Galdon M, et al. Ex vivo indocyanine green fluorescence imaging for the detection of lymph node involvement in advanced-stage ovarian cancer. *J Surg Oncol* 2018;118:1163–9.
- Scambia G, Nero C, Uccella S, et al. Sentinel-node biopsy in early stage ovarian cancer: a prospective multicentre study (SELLY). *Int J Gynecol Cancer* 2019;29:1437–9.
- Matsuo K, Klar M, Barakzai SK, et al. Utilization of sentinel lymph node biopsy in the early ovarian cancer surgery. *Arch Gynecol Obstet* 2023;307:525–32.
- Lago V, Montero B, López S, et al. Ultrastaging protocol in sentinel lymph node for apparent early stage ovarian cancer. *Gynecol Oncol* 2021;161:408–13.
- Uccella S, Garzon S, Bosco M, et al. Cervical versus utero-ovarian ligament injection of the tracer for the pelvic sentinel lymph node mapping in gynecologic oncology: a prospective observational study. *Gynecol Obstet Invest* 2022;87:242–7.
- Negishi H, Takeda M, Fujimoto T, et al. Lymphatic mapping and sentinel node identification as related to the primary sites of lymph node metastasis in early stage ovarian cancer. *Gynecol Oncol* 2004;94:161–6.
- Nyberg RH, Korkola P, Mäenpää J. Ovarian sentinel node: is it feasible? *Int J Gynecol Cancer* 2011;21:568–72.
- Vanneville G, Mestas D, Le Bouedec G, et al. The lymphatic drainage of the human ovary in vivo investigated by isotopic lymphography before and after the menopause. *Surg Radiol Anat* 1991;13:221–6.
- Uccella S, Nero C, Vizza E, et al. Sentinel-node biopsy in early-stage ovarian cancer: preliminary results of a prospective multicentre study (SELLY). *Am J Obstet Gynecol* 2019;221:324.
- Lago V, Bello P, Montero B, et al. Clinical application of the sentinel lymph node technique in early ovarian cancer: a pilot study. *Int J Gynecol Cancer* 2019;29:377–81.
- Kleppe M, Brans B, Van Gorp T, et al. The detection of sentinel nodes in ovarian cancer: a feasibility study. *J Nucl Med* 2014;55:1799–804.
- Hassanzadeh M, Hosseini Farahabadi E, Yousefi Z, et al. Lymphatic mapping and sentinel node biopsy in ovarian tumors: a study using



- intra-operative Tc-99m-phytate and lymphoscintigraphy imaging. *J Ovarian Res* 2016;9:1–8.
- 27 Guerra JC, Di Ruggiero FC. Ovarian tumors: determination sentinel node. *Lymphatic Mapping Gac Med Caracas* 2021;129:343–55.
- 28 Angelucci M, Corrado G, Mancini E, et al. Laparoscopic indocyanine green sentinel lymph node mapping in early ovarian cancer. a pilot study and review of the literature. *Ital J Gynaecol Obstet* 2016;28:23–8.
- 29 Laven P, Kruitwagen R, Zusterzeel P, et al. Sentinel lymph node identification in early stage ovarian cancer: is it still possible after prior tumor resection? *J Ovarian Res* 2021:1–6.
- 30 Lago V, Bello P, Montero B, et al. Sentinel lymph node technique in early-stage ovarian cancer (SENTOV): a phase II clinical trial. *Int J Gynecol Cancer* 2020;30:1390–6.
- 31 Buda A, Passoni P, Corrado G, et al. Near-infrared fluorescence-guided sentinel node mapping of the ovary with Indocyanine green in a minimally invasive setting: a feasible study. *J Minim Invasive Gynecol* 2017;24:165–70.
- 32 Cabrera S, Bebia V, Franco-Camps S, et al. Technetium-99m-indocyanine green versus technetium-99m-methylene blue for sentinel lymph node biopsy in early-stage endometrial cancer. *Int J Gynecol Cancer* 2020;30:311–7.
- 33 Agusti N, Paredes P, Vidal-Sicart S, et al. Sentinel lymph node mapping in early-stage ovarian cancer: surgical technique in 10 steps. *Int J Gynecol Cancer* 2022;32:1082–3.
- 34 Lago V, Bello P, Matute L, et al. Sentinel lymph node technique in apparent early ovarian cancer: laparoscopic technique. *J Minim Invasive Gynecol* 2020;27:1019–20.
- 35 Kleppe M, Wang T, Van Gorp T, et al. Lymph node metastasis in stages I and II ovarian cancer: a review. *Gynecol Oncol* 2011;123:610–4.
- 36 Morice P, Joulie F, Camatte S, et al. Lymph node involvement in epithelial ovarian cancer: analysis of 276 pelvic and paraaortic lymphadenectomies and surgical implications. *J Am Coll Surg* 2003;197:198–205.
- 37 Barlin JN, Khoury-Collado F, Kim CH, et al. The importance of applying a sentinel lymph node mapping algorithm in endometrial cancer staging: beyond removal of blue nodes. *Gynecol Oncol* 2012;125:531–5.
- 38 Armstrong DK, Alvarez RD, Bakkum-Gamez JN, et al. Ovarian cancer, version 2.2020. *JNCCN J Natl Compr Cancer Netw* 2021;19:191–226.
- 39 US National Library of Medicine. Mapping sentinel lymph node in initial stages of ovarian cancer (MELISA). 2023 Available: <https://clinicaltrials.gov/ct2/show/NCT05184140>
- 40 US National Library of Medicine. Sentinel lymph node in early ovarian cancer (SELLY). 2023. Available: <https://clinicaltrials.gov/ct2/show/NCT03563781>
- 41 US National Library of Medicine. Sentinel lymph node assessment in ovarian cancer (TRSGO-SLN-005). 2023. Available: <https://clinicaltrials.gov/ct2/show/NCT04714931>