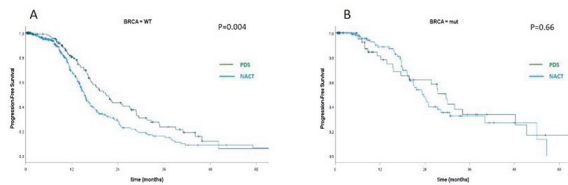


range. Median Progression Free Survival (PFS) in women >65 y for PDS and IDS was respectively 29.7 vs 23.4 months (p=0.66) for BRCAmut, and 21.0 vs 15.4 months (p=0.004) for BRCAwt.

**Abstract 2022-LBA-677-ESGO Table 1** Distribution of BRCA status according to age

Age group	BRCA wt	BRCA mut	Total
<50	243 (50.0%)	243 (50.0%)	486
50-59	356 (58.4%)	254 (41.6%)	610
60-69	387 (67.4%)	187 (32.6%)	574
70-79	277 (78.2%)	77 (21.8%)	354
>=80	51 (78.5%)	14 (21.5%)	65
<b>Totale</b>	<b>1314 (62.9%)</b>	<b>775 (37.1%)</b>	<b>2089</b>



**Abstract 2022-LBA-677-ESGO Figure 1** Kalpan-Meyer plots for progression free survival in (A) BRCAwt and (B) BRCA2mut in the older population (>65 years)

**Conclusions** BRCAmut is often associated to younger age, reaching the 50% in patients <50 y, however the rate of mutation in older age is not trascurable. BRCAmut patients maintain the best prognosis even in the older group. BRCAwt are less likely to respond to chemotherapy and in this group upfront surgery with complete resection makes the difference.

**2022-LBA-714-ESGO FULL-THICKNESS PARTIAL DIAPHRAGM RESECTION USING AN ENDO GIA VASCULAR STAPLER IN PATIENTS WITH ADVANCED-STAGE OVARIAN CANCER: AN INSTITUTIONAL SERIES**

<sup>1,2</sup>Daniela Huber, <sup>3</sup>Ian Fournier, <sup>4</sup>James Nef, <sup>5</sup>Michel Christodoulou, <sup>1</sup>Stéphanie Seidler, <sup>6</sup>Valérie Besse, <sup>2</sup>Yannick Hurni. <sup>1</sup>Obstetrics and Gynecology, Valais Hospital, Sion, Switzerland; <sup>2</sup>Pediatrics, Obstetrics and Gynecology, Geneva University Hospital, Geneva, Switzerland; <sup>3</sup>General Surgery, Valais Hospital, Sion, Switzerland; <sup>4</sup>UNIGE, Geneva, Switzerland; <sup>5</sup>Thoracic Surgery, Valais Hospital, Sion, Switzerland; <sup>6</sup>Radiology, Valais Hospital, Sion, Switzerland

10.1136/ijgc-2022-ESGO.1021

**Introduction** Patients with advanced-stage ovarian cancer frequently present with peritoneal carcinomatosis with a diaphragmatic involvement. During cytoreduction surgeries, deep infiltrating nodules require diaphragmatic full-thickness resections (DFTRs). These procedures involve opening the pleural cavity, often requiring a chest drain, and are associated with a high rate of postoperative complications. We present a novel technique to perform DFTRs using a surgical stapler without opening the pleural cavity, and we report our preliminary results.

**Methods** Analysis of consecutive patients undergoing full thickness diaphragmatic resection using an EndoGIA vascular stapler by a single surgical team since January 2018.

**Results** Fifteen patients underwent cytoreductive surgeries with S-DFTRs. The median operative time was 300 (114 – 547) minutes. Cytoreduction was considered complete in all cases. Concomitant contralateral diaphragmatic peritoneal stripping was performed in 5 cases (33.3%) and was associated with a conventional DFTR in 1 case (6.7%). Pleural effusion was observed in 9 patients (60.0%), and 4 (26.7%) required a postoperative pigtail catheter thoracostomy. Three patients (20.0%) required catheter placement (ipsilaterally to the S-DFTR) and 2 patients (13.3%) required catheters on the contralateral hemithorax. Pulmonary embolism and pneumonia were both observed once (6.7%). The median hospitalization length was 14 (5 – 36) days. During the follow-up, 6 patients (40.0%) had a recurrence, but none involved the pleura or the diaphragm.

**Conclusions** This technique appears as a safe and easy method for performing diaphragmatic resections and could reduce postoperative complications.

**2022-LBA-750-ESGO RECTAL CANCER VERSUS ENDOMETRIOSIS ON ULTRASOUND IN METASTATIC OVARY**

Ahmed Elagwany. Alex uni, Alexandria, Egypt

10.1136/ijgc-2022-ESGO.1022

**Introduction** Ultrasound is now available everywhere with high advancement in technology. There are some findings on ultrasound that can be very similar on appearance. These include the rectal endometriosis and rectal cancer especially if there is adnexal masses associated.

**Methods** we are aiming here to show the difference and illustrate the findings for differentiation through presentation of 2 different cases.

**Results** IOTA scoring system is very important in initial assessment of masses, and it can be memorized easily. And after its application, expert ultrasound can help with pattern recognition of masses. Rectal cancer and rectal endometriosis can be easily mistaken or even can be missed so we aimed here to clarify them through discussion od 2 cases. Furthermore, mucin cancer typical appearance was not reported before on literature regarding the typical intestinal mucinous cystadenocarcinoma of the ovary and metastatic ovary with vessels sign also are shown here in a typical appearance.

**Conclusions** finally we aimed to show some ultrasound findings that was previously can be seen on ultrasound, now with advancement in technology, we can so that even better than the MRI and CT especially in the pelvic region.

**2022-LBA-751-ESGO NODAL VERSUS PERITONEAL METASTASIS ON ULTRASOUND**

Ahmed Elagwany. Alex uni, Alexandria, Egypt

10.1136/ijgc-2022-ESGO.1023

**Introduction** Granulosa cell tumors are rare ovarian neoplasms and they can metastasize and recur. Due to its rarity, limited data are available on nodal metastasis and recurrence. Recurrence after staging surgery can be nodal or peritoneal related to the lateral pelvic wall.