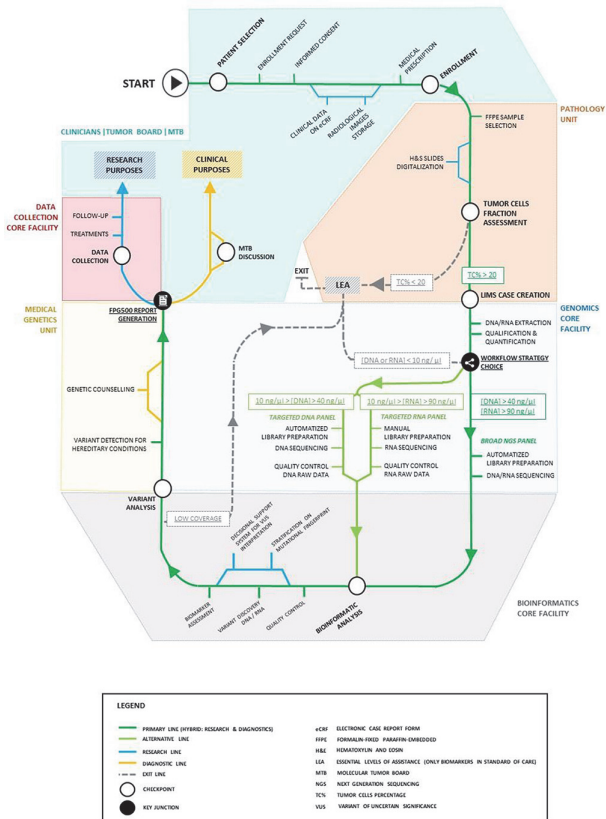


of the mutational landscape, enrollment rate in clinical trials, indications for referral to genetic counseling. Molecular features were further correlated with available clinico-pathological variables for each disease type.

Results Out of 188 women, the feasibility of CGP was 98%, with a mean turnaround time of 39 days. 33.5% of the population was referred to genetic counselling. Most significant findings are reported in Table 1.

Conclusions Regarding ovarian cancer, as expected, endometrioid and clear cell histotypes had different mutational profiles compared to serous ones (KRAS, ERBB2, FGF7, LRP1B, MDC1 and SPEN vs BRCA 1, FGF2, FGF7, FGF7, FGF7, TP53 respectively) with a minimum incidence of mutations. Regarding endometrial cancer, no difference was observed in clinical features for patients with TMB>10. No difference was observed between patients younger or older than 50 years. A TMB>10 was found in 35% of patients with 475 altered genes (mean=28) the most frequent being PTEN (82%), ARID1A (71%), and PIK3CA (65%).



2022-LBA-718-ESGO SENTINEL NODE BIOPSY FOR ENDOMETRIAL CANCER BY RETROPERITONEAL TRANSVAGINAL NATURAL ORIFICE TRANSLUMINAL ENDOSCOPIC SURGERY

^{1,2}Daniela Huber, ²Yannick Humi. ¹Obstetrics and Gynecology, Valais Hospital, Sion, Switzerland; ²Pediatrics, Obstetrics and Gynecology, Geneva University Hospital, Geneva, Switzerland

10.1136/ijgc-2022-ESGO.1013

Introduction Surgical staging with sentinel lymph node biopsy (SLNB) is an important tool to guide the management of early-stage endometrial cancer. This staging is generally performed by minimally invasive techniques such as conventional, single-site, or robotic laparoscopy. To further reduce the morbidity related to transabdominal surgeries, SLNB by total retroperitoneal transvaginal natural orifice transluminal endoscopic surgery (vNOTES) was recently introduced at our institution. Here, we describe how to perform this surgical technique and we report our preliminary results.

Methods Indocyanine green was injected into the cervix to identify sentinel lymph nodes (SLNs). Access to the pelvic retroperitoneal space was achieved through a paracervical incision in the lateral vaginal fornix, providing access to the obturator fossa. A 7 cm GelPoint transvaginal access platform was used as a vNOTES port, and CO₂ was insufflated to expand the retroperitoneal space. SLNs were identified using fluorescence imaging, carefully resected, and removed transvaginally.

Results Eleven patients underwent SLNB by vNOTES at our institution between October 2021 and July 2022. Indications to perform SLNB were endometrial cancer (8 cases) and endometrial complex atypical hyperplasia (3 cases). The median operative time was 113 (81–211) minutes. The median estimated blood loss was 20 (20–400) mL. The overall bilateral detection rate was 100% (10/10). We completed all procedures without significant intraoperative complications, but 1 case required conversion to conventional laparoscopy. The median postoperative stay was 2 (2–4) days. We observed one case of postoperative deep vein thrombosis and an asymptomatic vaginal vault hematoma in one patient and a retroperitoneal hematoma requiring surgical drainage in another. Definitive results are not available at the time of abstract submission and will be updated later.

Abstract 2022-LBA-746-ESGO Figure 1

Abstract 2022-LBA-746-ESGO Table 1 Main findings of FPG500 CGP programme

	MOST FREQUENT ALTERED GENES	TMB (<5; 5-10; >10)	MSI (no; yes)
OVARIAN CANCER			
All patients	TP53 (80%), FGF2 (27%), PIK3CA (22%), BRCA2 (21%), BRCA1 (20%), MYC (20%) and NRG1 (20%)	(58%; 34%; 9%)	99%; 1%
AGE <= 50 years (respect to older patients)	↓ ALK, CCNE1, FGF5, FGF7	(69%; 25%; 6%) vs (54%; 37%; 9%)	
TISSUE FROM UP FRONT DIAGNOSIS (respect to relapses)	↓ CHEK2 ↑ ESR1, FGF5, FGF7, PRKDC, TP53	(59%; 33%; 8%) vs (57%; 33%; 10%)	
STAGE I-II (respect to stage III-IV)	↓ ALK, AR, CCNE1, FGF7, FGF7, FGF7, JAK2, TP53, ZFH3	(68%; 19%; 13%) vs (55%; 38%; 7%)	
OVARIAN SAMPLE (respect to omentum or peritoneum)	↓ ALK, FGF7, SPEN, SPTA1 ↑ FGF14	(68%; 24%; 8%) vs (47%; 39%; 9%)	
NO RESIDUAL TUMOR (respect to residual tumor)	↓ TP53 ↑ FGF7, KRAS, FAT1, CHECK2	(59%; 27%; 14%) vs (53%; 43%; 4%)	
ENDOMETRIAL CANCER			
All patients	PTEN (67%), PIK3CA (51%), ARID1A (43%), CTNBN1 (24%), ZFH3 (22%), TP53 (20%)	(35%; 30%; 35%)	90%; 10%
AGE <= 50 years (respect to older patients)	No difference	(33%; 50%; 17%) vs (35%; 28%; 37%)	
STAGE I-II (respect to stage III-IV)	↓ JAK1, LZTR1 ↑ AKT1	(40%; 30%; 30%) vs (11%; 33%; 56%)	
ENDOMETRIAL SAMPLE (respect to other sites)	↓ MAP3K1, LZTR1, JAK1, CTCF, CHD4, ARID1A ↑ AKT1, ARID5B, CTNBN1, FANCI	(38%; 23%; 38%) vs (18%; 55%; 27%)	

TMB: Tumor Mutational Burden; MSI: Microsatellite Instability; ↓ minor incidence; ↑ major incidence

Conclusions Our preliminary experience suggests that retroperitoneal vNOTES is a safe, feasible, and valuable technique to perform SLNB in gynecological malignancies.

2022-LBA-789-ESGO SENTINEL LYMPH NODE DETECTION WITH MAGTRACE® IN ENDOMETRIAL CANCER

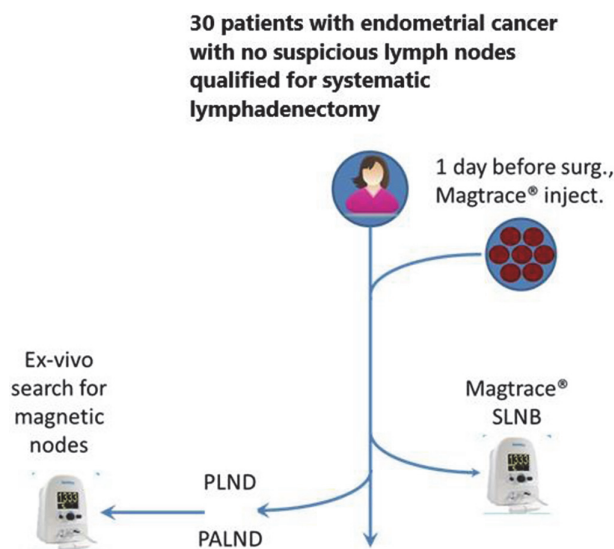
¹Marcin Jedryka, ²Marcin Kryszpin, ¹Andrzej Czekanski, ¹Piotr Lepka, ³Piotr Klimczak. ¹Oncological Gynecology, Wrocław Medical University and Lower Silesian Oncology Center, Wrocław, Poland; ²Oncological Gynecology, Lower Silesian Oncology Center, Wrocław, Poland; ³Prudnik Medical Center, Prudnik, Poland

10.1136/ijgc-2022-ESGO.1014

Introduction This prospective observational study, named SENDOCAN (Sentinel lymph node detection with Magtrace® in Endometrial Cancer) evaluates the efficacy of the Magtrace® system in SLN (Sentinel Lymph Nodes) detection in endometrial cancer patients with unsuspecting lymph nodes in comparison with the standard of care. The nanoparticle paramagnetic detection systems of SLN have been proved so far to be comparable and non-inferior to the standard procedure of systematic lymphadenectomy in breast cancer and vulvar cancer patients.

Methods 30 patients with endometrial cancer presumably stage I, with unsuspecting lymph nodes were included into the study and received a cervical injection of superparamagnetic iron oxide tracer (Magtrace®) which localized and detected SLN with magnetic counts and with visual inspection for their brownish colour. For each SLN the anatomic site, magnetic counts and colour was documented before biopsy. Afterwards, systematic lymphadenectomy – pelvic (PLND) and paraaortic (PALND) was performed as the standard of care.

Results SLN were detected in every patient. Bilateral SLN were found in 70% of cases. The mean SLN count per patient was 1.7. 94% of SLN were assessed as brownish stained. Micrometastases were detected in 4 SLN, confirmed by PLND/PALND. However, in 2 cases micrometastases were detected in paraaortic lymph nodes during PALND but not with SLNB. Statistic results have been presented in the table.



Abstract 2022-LBA-789-ESGO Figure 1

Abstract 2022-LBA-789-ESGO Table 1

Statistic results of the SENDOCAN study		
Statistic	Value	95% CI
Sensitivity	13.33%	3.76% to 30.72%
Specificity	83.33%	65.28% to 94.36%
Positive Likelihood Ratio	0.80	0.24 to 2.69
Negative Likelihood Ratio	1.04	0.84 to 1.29
Positive Predictive Value	8.16%	2.57% to 23.03%
Negative Predictive Value	89.64%	87.49% to 91.46%
Accuracy	76.33%	63.60% to 86.35%

Conclusions The study showed efficient Magtrace® detection of SLN in endometrial cancer patients regarding the pelvic lymph nodes. This cannot be confirmed when paraortic lymph nodes are involved.

2022-LBA-1183-ESGO LYMPHEDEMA APPEARANCE ACCORDING TO NODAL STAGING IN ENDOMETRIAL CANCER

Virginia García-Pineda, María Alonso-Espías, Rocío Arnedo, Myriam Gracia, Ignacio Zapardiel, Jaime Siegrist, María Dolores Diestro, Alicia Hernández. *Gynaecological Oncology, La Paz University Hospital, Madrid, Spain*

10.1136/ijgc-2022-ESGO.1015

Introduction Sentinel lymph node (SLN) mapping has been demonstrated to be an accurate nodal staging method in early stage of endometrial cancer (EC), however, the advantage that it offers in patient's morbidity compared to systematic lymphadenectomy has not been extensively evaluated. The aim of our study is to compare the appearance of lymphedema according to nodal staging.

Methods A single institutional retrospective study was performed including all patients with early-stage endometrial cancer who underwent surgical nodal staging between January 2012 and December 2021. Patients with disseminated disease on imaging or at the time of surgery were excluded. All these patients underwent nodal staging with SLN mapping ± pelvic (PLD) and para-aortic (PALD) lymph node dissection. We evaluated lymphedema appearance separating the patients in two groups: group 1: SLN mapping; group 2: Systematic PLD ± PALD with or without SLN mapping.

Results We evaluated a total of 270 patients, among them, 150 (55,6%) underwent only SLN mapping (group 1) and 120 (44,4%) received nodal staging by full lymphadenectomies (group 2: 107 (89,1%) patients PLD+PALD and 13 patients (10,9%) PLD alone). The main surgical approach was laparoscopy (260 patients (96.3%). A median (range) number of 2,7 (0–9) sentinel nodes, 10,9 (0–36) pelvic nodes and 12,4 (0–39) paraaortic nodes were removed per patient. Comparing both groups, performing systematic lymphadenectomies was associated with greater risk of lymphedema (group 1: 0,7%; group 2: 14,3%, $p < 0,001$) with an odds ratio of 23.8 (95% confidence interval 3.1 to 182.7).

Conclusions SLN mapping is a safe and accurate alternative to complete lymphadenectomy in nodal staging of endometrial