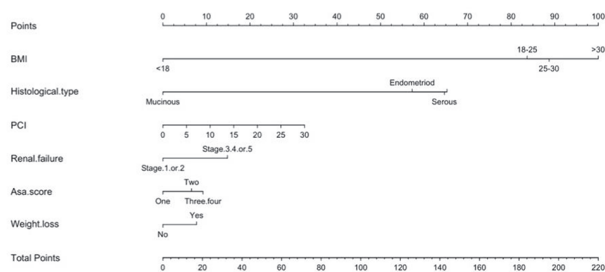


0.03). Peritoneal carcinosis index, body mass index, moderate to severe renal failure, weight loss, ASA score and histological type were associated with the occurrence of VTE at the diagnosis of ovarian cancer. VTE predictive nomogram created in this population had good internal agreement (AUC = 0.81, CI95% 0.73 – 0.89).



Nomogram predicting the likelihood of a thrombo-embolic event in patients with an ovarian cancer at the time of the diagnosis

Abstract 2022-RA-448-ESGO Figure 1 Nomogram predicting the likelihood of a thrombo-embolic event in patients with an ovarian cancer at the time of the diagnosis

Conclusion The incidence of VTE is high during ovarian cancer management, with many asymptomatic events. The impact of VTE is unfavorable on OS. The use of a nomogram could allow an earlier screening and thus improve the management and prognosis of patients. These results raise the question of systematic screening and its modalities in this population.

2022-RA-453-ESGO

IS OMENTAL CAKE ASSOCIATED WITH HIGHER RISKS OF INCOMPLETE DEBULKING SURGERY IN ADVANCED STAGE OVARIAN CANCER?

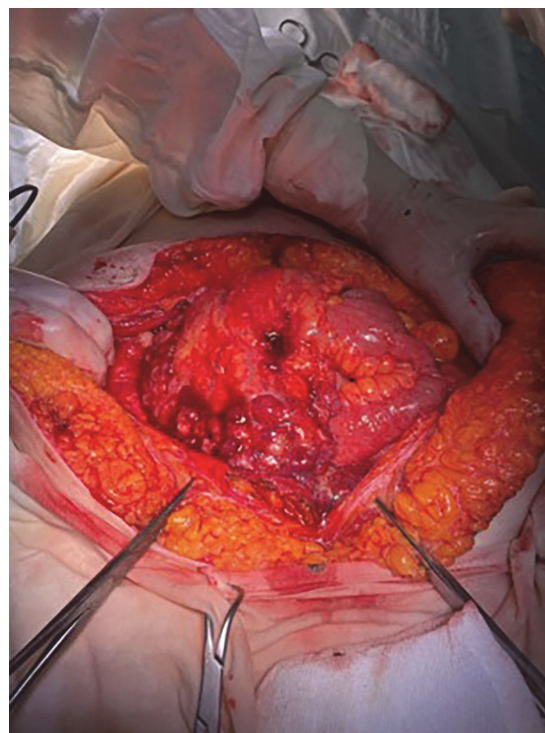
Nicolae Bacalbasa, Irina Balescu. *Carol Davila University, Bucuresti, Romania*

10.1136/ijgc-2022-ESGO.507

Introduction/Background Omental tumoral transformation is frequently encountered in advanced stage ovarian cancer. Depending on the progression of the disease, in certain cases adjacent organs might be invaded and therefore, the chances of decreasing the completeness of cytoreduction are higher

Methodology In the current paper we report the cases of 18 patients diagnosed with omental cake originating from ovarian cancer

Results In two cases total omentectomy was associated with total hysterectomy and bilateral adnexectomy, peritonectomy and lymph node dissection, in other two cases total colectomy was also associated, in one case a large enterectomy was associated while in another case partial cystectomy was imposed (figure 1). In the other 12 cases a massive invasion of the underlying loops was encountered and therefore the intervention was limited to a omental biopsy, the patients being further deferred to the oncology services in order to be submitted to neoadjuvant chemotherapy.



Abstract 2022-RA-453-ESGO Figure 1

Conclusion In conclusion, a significant number of cases presenting omental cake might not be candidates for per primam cytoreduction and might need neoadjuvant chemotherapy.

2022-RA-454-ESGO

OVARIAN METASTASES FROM PULMONARY CANCER – REPORT OF TWO CASES

Nicolae Bacalbasa, Irina Balescu. *Carol Davila University, Bucuresti, Romania*

10.1136/ijgc-2022-ESGO.508

Introduction/Background Krukenberg tumors are frequently encountered in the setting of digestive or breast cancer; however, in certain cases pulmonary origin can be also encountered.

Methodology The aim of the current paper is to report two such cases.

Results The first case was the one of a 73 year old female who has been previously investigated for severe weight loss and dysphagia and who was diagnosed with a tumoral mass at the level of the mediastinum in association with a pulmonary nodule measuring 1,5 cm at the level of the left lung and with an ovarian tumor measuring 4/5 cm. the patient was submitted to a laparoscopic adnexectomy, the final diagnostic being of an ovarian pulmonary metastasis. The patient was further submitted to systemic chemotherapy in association with chest radiotherapy; at two year follow up she presented a significant decrease of the adenopathic mass, the disparition of the pulmonary nodule. The second case was the one of a 39 year old patient with previous history of

neuroendocrine pulmonary tumor with local invasion and poor response to radiochemotherapy; however during therapy she was diagnosed with bilateral ovarian tumors and ascites which significantly impeded the respiratory function. In order to exclude the presence of a synchronous ovarian cancer and to improve the respiratory function, a total hysterectomy with bilateral adnexectomy was performed; meanwhile 5.5 l of ascites were removed. The histopathological studies demonstrated the metastatic origin of the lesion and enabled the oncologist to administrate a second line cytotoxic therapy. However, the patient died of disease after the first cycle of chemotherapy.

Conclusion Although very rare conditions, Krukenberg tumors from ovarian cancer should be suspected whenever an association of confirmed pulmonary malignancy and incidental suspect ovarian tumors are found.

2022-RA-455-ESGO TYPICAL RECURRENCES OF OVARIAN GRANULOSA CELL TUMOR RECURRENCE

Nicolae Bacalbasa, Irina Balescu. Carol Davila University, Bucuresti, Romania

10.1136/ijgc-2022-ESGO.509

Introduction/Background Ovarian granulosa cell tumors represent a particular subset of ovarian tumors characterized through a low rate of multiplication of the tumoral cells and a low risk of developing distant metastases. However, in isolated cases recurrences might develop.

Methodology The current paper presents the cases of two patients diagnosed with mesosigmoidian metastases from ovarian granulosa cell tumors.

Results The first case was investigated for diffuse abdominal pain after an incidental abdominal trauma while the second case was investigated for subocclusive syndrome. In the first case the preoperative suspicion of diagnostic was of a retroperitoneal hematoma while in the other case the preoperative suspicion of diagnostic was of peritoneal carcinomatosis. Intraoperatively in the first case a large ruptured recurrence with perilesional hematoma was found while in the second case a recurrent tumor at the level of the mesosigmoidian area, in close contact with the sigmoidian lumen was found. In both cases a rectosigmoidian resection was performed, the histopathological studies demonstrating the presence of mesosigmoidian recurrences.

Conclusion Although ovarian granulosa cell tumors usually exhibit a good prognostic and a low rate of recurrence, relapsed tumors with atypical locations might be found. In such cases different visceral resections might be needed in order to control the disease

2022-RA-456-ESGO GYNAE-ONCOLOGY SURGEONS' PREPAREDNESS TO UNDERTAKE COLORECTAL PROCEDURES DURING CYTOREDUCTIVE SURGERY FOR OVARIAN CANCER: A CROSS SECTIONAL SURVEY

^{1,2}Daniel Huddart, ¹Savithri Rajkumar, ¹Gautam Mehra, ¹Rahul Nath, ¹Ahmad Sayasneh. ¹Women's Health, Guy's and St Thomas' NHS Foundation Trust, London, UK; ²King's College London, London, UK

10.1136/ijgc-2022-ESGO.510

Introduction/Background Cytoreductive surgery for advanced ovarian cancer commonly involves bowel resection. Although gynaecological oncologists in the UK are trained in bowel surgery, there exists national variations in the degree to which these specialists perform bowel surgery independently. A recent joint policy statement from the British Gynaecological Cancer Society (BGCS) emphasises the need for formalised colorectal support for cytoreductive surgery.

Methodology An anonymous, online survey was emailed to members of the BGCS to assess the current status of multidisciplinary working between gynaecological oncology and colorectal/general surgical teams in the UK. The survey explored access to colorectal surgeons in the pre and peri operative periods and the role of colorectal/general surgical support in common bowel procedures performed during cytoreductive surgery, alongside their input with surgical complications and post-operative management.

Results 46 members responded (8.2% response rate). There was a large variety in the involvement of colorectal and general surgical teams in pre-operative planning. Despite nearly all respondents working in tertiary care centres, 13% of respondents had no formalised agreement for intraoperative support. 72.1% of respondents independently performed rectal peritoneal stripping and 60.5% of respondents independently performed small bowel resection. This reduced to only 27.9% for right hemicolectomy with primary anastomosis and 16.3% for left hemicolectomy with primary anastomosis. Respondents often involved colorectal support for post-operative complications.

Abstract 2022-RA-456-ESGO Table 1 How do you perform bowel procedures with regard to colorectal/general surgical

	Independently with remote emergency colorectal/general surgical support if required	Independently with remote pre planned colorectal/general surgical support if required	Colorectal/general surgical attend theatre for the purpose of direct supervision	Colorectal/general surgical would undertake the procedure
Procedure				
Small bowel resection with ileostomy	80.5%	13.4%	4.7%	20.9%
Small bowel resection with primary anastomosis	80.5%	18.3%	7.0%	16.3%
Right hemicolectomy with no anastomosis (bowel stoma)	32.6%	18.3%	11.8%	39.5%
Right hemicolectomy with primary anastomosis	27.9%	11.8%	11.8%	48.8%
Transverse colectomy with colostomy	37.2%	11.8%	4.7%	46.5%
Transverse colectomy with primary anastomosis	25.8%	11.8%	14.0%	48.9%
Left hemicolectomy with colostomy	39.5%	14.0%	11.8%	34.9%
Left hemicolectomy including recto-sigmoid resection with primary anastomosis	18.3%	9.3%	20.9%	53.5%
Sigmoid colectomy with primary anastomosis and de-functioning ileostomy	23.3%	9.3%	18.8%	48.8%
Hartmann's procedure	46.5%	14.0%	7.0%	32.6%
Peritoneal stripping of the rectum	72.1%	18.3%	4.7%	7.0%
Resection of bowel mesenteric or serosal disease	74.4%	18.8%	4.7%	2.3%

Conclusion Overall, the degree to which gynaecological oncologists independently perform bowel procedures varies within the UK. The majority involve colorectal or general surgical teams in such procedures. Surgical team involvement is more common for large bowel procedures compared to small bowel