

and less expensive. Nevertheless, based on a 25% and 15% rate of false positivity and negativity respectively, consideration should be given to confirm MSI IHC status for all patients by molecular analyses.

2022-VA-979-ESGO

TOTAL EXCISION OF INFRARENAL VENA CAVA IN A PATIENT WITH RECURRENT ENDOMETRIAL CANCER

¹Dogan Vatansever, ¹Emin Erhan Donmez, ¹Burak Giray, ²Atif Akcevin, ¹Macit Arvas, ¹Cagatay Taskiran. ¹Gynecologic Oncology, Koc University Hospital, Istanbul, Turkey; ²Cardiovascular Surgery, Koc University Hospital, Istanbul, Turkey

10.1136/ijgc-2022-ESGO.267

Introduction/Background Endometrial cancer is one of the common malignant tumors of the female reproductive system. The recurrence and 5-year overall survival rates of patients with FIGO I-II are 2–15 and 74–91%, respectively. Secondary cytoreductive surgery is associated with improved overall survival in patients with recurrent disease. This video aims to present metastasectomy along with the infrarenal vena cava in a patient with recurrent ovarian cancer.

Methodology A 68-year-old woman was admitted with a gross abdominal mass. She has been diagnosed with stage 1, grade 1 endometrial cancer, and underwent a primary staging surgery 2 years ago. The magnetic resonance imaging revealed a 43x39x49 mm abdominal mass involving vena cava inferior. Also, positron emission tomography scan showed a 45x47x50 mm metastatic lymph node extending to the aortocaval prevertebral area. Metastasectomy along with the infrarenal vena cava, resection of bulky paraaortic lymph nodes, partial resection of the duodenum, and duodenojejunostomy were performed as part of maximal secondary cytoreduction.

Results She stayed at the intensive care unit for one day and discharged without any grade 3 or 4 adverse event in post-operative period.

Conclusion Secondary cytoreduction for endometrial cancer with no residual disease is a major impact on survival, and maximal cytoreduction is necessary in selected cases. The management of this condition should be performed with expert multidisciplinary teams in gynecological oncology.

2022-RA-987-ESGO

MOLECULAR CHARACTERIZATION OF ENDOMETRIAL CANCER WITH LOW VOLUME METASTASIS IN THE SENTINEL LYMPH NODE: A MULTICENTRIC INTERNATIONAL STUDY

^{1,2}Gabriella Schivardi, ^{1,3}Giuseppe Cucinella, ¹Andrea Mariani, ⁴Maryam Shahi, ¹Carrie Langstraat, ⁵Amy Weaver, ⁵Michaela Mc Gree, ²Francesco Multinu, ²Vanna Zanagnolo, ²Ilaria Betella, ⁶Glauco Baiocchi, ⁶Louise de Brot, ⁷Robert Giuntoli, ⁷Spyridon Mastroyannis, ¹Gretchen Glaser. ¹Department of Obstetrics and Gynecology, Division of Gynecologic Surgery, Mayo clinic, Rochester, MN; ²Department of Gynecology, European Institute of Oncology, IEO, IRCCS, Milan, Italy; ³Department of Gynecologic Oncology, University of Palermo, Palermo, Italy; ⁴Department of Pathology, Mayo clinic, Rochester, MN; ⁵Department of Quantitative Health Sciences, Mayo clinic, Rochester, MN; ⁶Department of Gynecologic Oncology, A.C. Camargo Cancer Center, Sao Paulo, Brazil; ⁷Department of Obstetrics and Gynecology, Division of Gynecologic Oncology, University of Pennsylvania Health System, Philadelphia, PA

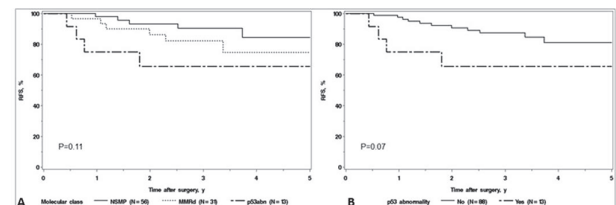
10.1136/ijgc-2022-ESGO.268

Introduction/Background The primary aims of this study were to assess the molecular characterization of endometrial cancer (EC) patients with low volume metastasis (LVM) in the sentinel lymph node (SLN) and to identify the molecular predictors of recurrence among those patients.

Methodology Patients with EC and LVM [isolated tumour cells (<0.2 mm) – micrometastasis (≥ 0.2 < 2 mm)] who underwent surgery from August 2014 to November 2020 and had subsequent molecular characterization were identified among four referral centres worldwide. Patients with adnexal involvement and FIGO stage IV were excluded. The molecular analysis included immunohistochemistry for p53 and MMR proteins and Sanger sequencing for POLE exonuclease domain. ECs were classified into four molecular classes (POLEmut, MMRd, p53abn, and NSMP).

Results Among 101 patients, the molecular classification showed 56 NSMP, 31 MMRd, 13 p53Abn, and 1 POLEmut. Of 12 non-endometrioid cases, 11 were p53abn. Overall, 15 patients experienced a recurrence, and the median follow-up for the remaining patients was 3.1 (IQR, 2.0–3.8) years. The 3-year RFS was 90.4% (95% CI 95%, 81.8–99.9%), 82.1% (95% CI, 69.0–97.8%) and 65.6% (95% CI, 43.2%–99.7%), for the NSMP, MMRd, and p53Abn classes, respectively. No recurrence was observed in the POLEmut case. The overall RFS analysis between the three classes was comparable (p=0.11), and the comparison between p53abn class and the other classes did not reach a significant difference (p=0.07).

On univariate analysis, the presence of micrometastasis (p=0.02), non-endometrioid histology (p=0.02), lymphovascular space invasion (p=0.04), and positive peritoneal cytology (p=0.005) were significant predictors of recurrence.



Abstract 2022-RA-987-ESGO Figure 1 (A) Recurrence-free survival according to molecular classes (NSMP, MMRd, p53abn). (B) Recurrence-free survival according to p53 status (p53abn vs. All other classes)

Conclusion Among EC patients SLN-LVM, there is a low rate of POLEmut tumours. Our results confirmed that traditional pathological features have a strong impact on prognosis among SLN-LVM patients. We did not observe significant impact of the molecular classes on the risk of recurrence, however further studies are needed.

2022-RA-988-ESGO

CLINICAL OVER AND UNDER ESTIMATION IN PATIENTS WHO UNDERWENT HYSTERECTOMY FOR ATYPICAL ENDOMETRIAL HYPERPLASIA

¹Funda Atalay, ²Cemal Resat Atalay. ¹Gynecologic Oncology Surgery, Dr.AY Ankara Oncology Education and Research Hospital, Ankara, Turkey; ²Gynecology and Obstetrics, Ankara City Hospital (Ankara Numune Educational And Research Hospital), ANKARA, Turkey

10.1136/ijgc-2022-ESGO.269

Introduction/Background Studies on atypical endometrial hyperplasia (AEH) consistently reported high risk for the coexistence of endometrial cancer (EC) or progression to EC. On the other hand, the final diagnosis may turn out to be benign pathology (hyperplasia without atypia or normal endometrium) after hysterectomy for AEH. The purpose of this study was to determine the rates of under- and over-estimation compared to the final pathology after hysterectomy for AEH and to evaluate the predictive role of endometrial thickness

Methodology We retrospectively reviewed the medical records of 94 patients with AEH at two referral hospitals in Ankara between 2015 and 2020. 60 of them underwent a hysterectomy within 6 months after the index biopsy. Data were extracted for age, menopausal status, tamoxifen use and endometrial thickness. Of these 60 patients, 57 of whom we could reach the final pathology result were evaluated

Results Among patients who underwent hysterectomy due to a diagnosis of atypical hyperplasia, 23 cases (40,35%) were underestimated (cancer), 11 cases (19,29%) were equivalent and 23 cases (40.35%) were overestimated. There was no difference among these groups in endometrial thickness by transvaginal ultrasonography.

Conclusion Diagnosis of atypical endometrial hyperplasia by endometrial biopsy may often resulted in under- or over-estimation. As there is neither a reliable clinical parameter nor imaging feature to distinguish between these groups, hysterectomy is still the best treatment option for these patients.

2022-RA-992-ESGO

INCIDENCE AND THE CLINICAL CHARACTERISTICS OF ENDOMETRIAL CANCER IN END-BX PERFORMED WITH PIPELLE IN BREAST CANCER PATIENTS

¹Funda Atalay, ²Cemal Resat Atalay. ¹Gynecologic Oncology Surgery, Dr.AY Ankara Oncology Education and Research Hospital, Ankara, Turkey; ²Gynecology and Obstetrics, Ankara City Hospital (Ankara Numune Educational And Research Hospital), ANKARA, Turkey

10.1136/ijgc-2022-ESGO.270

Introduction/Background Endometrial cancer with a history of breast cancer (BC) is a specific condition. As compared to the general population, breast cancer survivors are at an increased risk of developing any secondary cancer with an excess risk of 30%. Endometrial cancer (EC), is the most frequently

observed secondary malignancy among breast cancer patients. We aimed to investigate the incidence and the characteristics of EC in patients with previous breast cancer.

Methodology The records of 49 patients with previous history of BC and who underwent pipelle endometrial biopsy between 2015–2020 were evaluated retrospectively. Data were evaluated for age, menopausal status, tamoxifen use and endometrial thickness, surgery and the pathologic characteristics of endometrial cancer patients.

Results Among 49 endometrial biopsies, endometrial cancer was diagnosed in 10 (20.4%), atypical endometrial hyperplasia was diagnosed in 3 patients (6,12%), nonatypical endometrial hyperplasia in 8 (16,32%), endometrial polyp and normal histology was noted in 28 patients (57,14%). Since 2 out of 10 patients diagnosed with endometrial cancer were operated in another center, we evaluated the data of 8 endometrial cancer cases. (40.1%). The characteristics of the patients who were diagnosed with endometrial cancer and underwent surgical staging are summarized in table 1.

Conclusion Abnormal uterine bleeding, increased endometrial thickness in BC patients treated with tamoxifen, found to be associated with the formation of endometrial cancer. Based on these findings, breast cancer patients receiving tamoxifen therapy, especially postmenopausal patients, should be followed closely and carefully evaluated when they have abnormal bleeding.

2022-RA-994-ESGO

EVALUATION OF ONE STEP NUCLEIC ACID AMPLIFICATION (OSNA) METHOD FOR RAPID DETECTION OF LYMPH NODE METASTASES IN WOMEN WITH ENDOMETRIAL CANCER

¹Eleonora La Fera, ¹Alessandro Petrecca, ¹Giorgia Monterossi, ²Stefano Restaino, ¹Giovanni Scambia, ¹Francesco Fanfani. ¹Department of Woman, Child and Public Health, Fondazione Policlinico Universitario A. Gemelli IRCCS, Rome, Italy; ²Obstetrics, Gynecology and Pediatrics Department, Udine University Hospital, DAME, Udine, Italy

10.1136/ijgc-2022-ESGO.271

Introduction/Background The objective of this study is to establish the clinical performance of the One Step Nucleic Acid Amplification (OSNA) method for the detection of sentinel lymph node (SNL) metastases in women with early-stage endometrial cancer (EC) compared to standard Ultrastaging (US).

Abstract 2022-RA-992-ESGO Table 1 Clinical and surgical characteristics of patients with surgically staged endometrial cancer

Age	Menopausal status	Endometrial thickness mm	Surgical staging	Histology	Grade	MI	LVI	Cervical stromal invasion	Stage	TMX	TMX duration year
59	Postmenopausal	15	Yes	Endometrioid	1	<1/2	none	none	IA	No	
50	Postmenopausal	15	Yes	Endometrioid	2	<1/2	none	none	IA	Yes	7
60	Postmenopausal	6	Unknown							No	
61	Postmenopausal	7	Yes	Endometrioid	2	none	none	none	IA	Yes	5
53	Premenopausal	12	Yes	Endometrioid	3	<1/2	none	none	IA	Yes	2
60	Postmenopausal	11	Unknown							No	
50	Premenopausal	22	yes	Endometrioid	2	none	none	none	IA	Yes	5
73	Postmenopausal	10	Yes	Endometrioid	1	<1/2	none	none	IA	Yes	5
64	Postmenopausal	15	Yes	Endometrioid	2	<1/2	none	none	IA	No	
52	Postmenopausal	22	Yes	Endometrioid	2	none	none	none	IA	No	