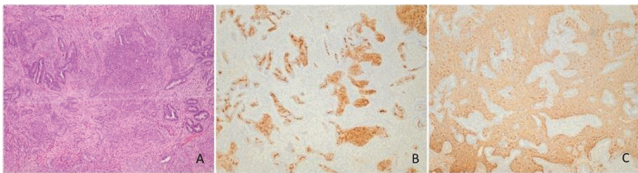


Two months after delivery, TCR provided normal histopathological specimen.

A 38-year-old patient presented with infertility and abnormal uterine bleeding (AUB). After TCR of APA, patient started assisted reproductive treatment with frequent ultrasound monitoring.

For patients aged 48 and 52 year, who presented with intrauterine mass (largest diameter of 18 mm) and AUB, hysterectomy was recommended after confirmation of APA by TCR.

Clinical symptoms of APA included infertility and AUB. Transvaginal ultrasonography confirmed intracavitary lesions in all patients, with largest diameter of 18 mm and glandular polyp as associated pathology.



**Abstract 2022-RA-215-ESGO Figure 1** A typical polypoid adenomyoma contain irregular, often architecturally complex endometrioid gland, with squamous morules (B – CD10), set within myomatous stroma (C – SMA)

**Conclusion** In our institution, two patients are being conservatively treated for APA with one case of successful pregnancy. Due to the rarity of APA, further observation will evaluate the success of conservative treatment.

\$\$\$MISSING OR BAD GRAPHIC SPECIFICATION (775D89EE-4F2F-4854-9973-8506F2BAC2EC) \$\$\$

### 2022-RA-269-ESGO PRIMARY MALIGNANT FOLLICULAR LYMPHOMA OF THE UTERINE CERVIX, TWO CASE REPORTS

Janire Zarragoitia, Sonia Baulies, Francesc Tresserra Casas, Rafael Fabregas, Francesc Fargas. *Hospital Universitari Dexeus, Barcelona, Spain*

10.1136/ijgc-2022-ESGO.787

**Introduction/Background** The incidence of non-Hodgkin lymphomas in Spain is 10.8/100.000 women. The extranodal lymphomas account for the 15%, only 1% being originated in the genital tract. Their management, prognosis and treatment efficacy is controverted.

**Methodology** First case: a 36-year-old asymptomatic patient undergoes annual checkup. The pelvic ultrasound shows a 31x37 mm cervical mass with *score 4* vascularization, confirmed by MRI. Cytology and HPV come up negative. A cervical biopsy with immunohistochemistry analysis is performed, with positive results for BCL2-6, CD20, CD23 and CD5. The PET-CT shows no signs of metastases nor pathologic lymph nodes. Second case: a 45-year-old asymptomatic patient undergoes annual checkup. The pelvic ultrasound shows a 48x36 mm cervical mass with *score 4* vascularization, confirmed by MRI. Cytology and HPV come up negative. A cervical biopsy with immunohistochemistry analysis is performed, with positive results for BCL6 and CD20. The PET-CT shows a suspicious right iliac lymph node, but no signs of distal metastases.

**Results** In case n°1, due to the desire of future pregnancy the patient undergoes chemotherapy after fertility preservation, who is in remission at this moment. In case n°2, the patient undergoes total hysterectomy and periodic checkups, also in remission at this moment.

**Conclusion** Less than 1/175 extra nodal lymphomas are likely to originate in the genital tract, and it is important to make a differential diagnosis with cervical cancer because both entities can present as vaginal bleeding, dyspareunia, or cervical mass. Diagnosis can be challenging due to frequent negative results from cytology, so the biopsy and immunohistochemical analysis is essential. Further investigation is needed in regard of the best treatment for this type of extra nodal lymphomas. Nowadays, it consists of neoadjuvant/adjuvant chemotherapy combined with surgery, reaching the complete response in 75% of cases and survival rates of up to 90% after 5 years, according to the latest studies.

### 2022-RA-442-ESGO FALLOPIAN TUBE CYTOLOGICAL FINDINGS IN WOMEN UNDERGOING SALPINGECTOMY AND CORRELATION WITH THE ADNEXAL PATHOLOGY

<sup>1</sup>Viktoria Psomiadou, <sup>1</sup>Sofia Lekka, <sup>2</sup>Theodoros Panoskaltis, <sup>3</sup>Eleni Tsouma, <sup>3</sup>Natasa Novkovic, <sup>4</sup>Helen Trihia, <sup>4</sup>Olympia Tzaida, <sup>1</sup>Dimitrios Korfiatis, <sup>1</sup>Panagiotis Giannakas, <sup>1</sup>Christos Iavazzo, <sup>5</sup>Christos Papadimitriou, <sup>2</sup>Nikolaos Vlahos, <sup>1</sup>George Vorgias. <sup>1</sup>Gynaecological Oncology, Metaxa Memorial Cancer Hospital, Piraeus, Athens, Greece; <sup>2</sup>Second Department of Obstetrics and Gynecology, Medical School, University of Athens "Aretaieio" Hospital, Athens, Greece; <sup>3</sup>Cytology Laboratory, Metaxa Memorial Cancer Hospital, Piraeus, Athens, Greece; <sup>4</sup>Pathology, Metaxa Memorial Cancer Hospital, Piraeus, Athens, Greece; <sup>5</sup>Oncology Unit, 2nd Department of Surgery Aretaieion Hospital, The National and Kapodistrian University of Athens, Athens, Greece

10.1136/ijgc-2022-ESGO.788

**Introduction/Background** Epithelial Ovarian Cancer (EOC) is still the most lethal gynecological malignancy, with approximately 21,410 new cases and 13,770 deaths in the USA in 2021. Many theories have been proposed in terms of clarifying the etiology and the carcinogenesis -mechanism of EOC. Based on the latest trends, ovarian, fallopian tube, and peritoneal cancer are incorporated into the same group as it is suggested that high-grade extrauterine tumors of serous histology originate from the fallopian tube.

**Methodology** We ex vivo collect salpingeal epithelial cells from the fibria directly from fresh fallopian tube specimens from women undergoing salpingectomy for any indication. The cytomorphological characteristics of the salpingeal cells are subsequently being evaluated and categorised into malignant and non -malignant. Finally, the ipsilateral adnexae are examined with the SEE-FIM (Sectioning and Extensively Examining the FIMbriated End) protocol and the pathology reports are correlated with the cytological findings. Our research protocol is ongoing and is designed to include a total of 300 patients in order to confirm the sensitivity and specificity of salpingeal cytology as a method in the early diagnosis of extrauterine gynecological malignancies.

**Results** So far, we have obtained 343 salpingeal brushings from a total of 214 patients. The sensitivity of cytology regarding distinguishing malignant from non-malignant tumors, was 69.64% (95% CI: 55.90% – 81.22%), while its specificity 75.96% (95% CI: 70.59% – 80.79%). Cytology's positive predictive value (PPV) was 16.33% (95% CI: 12.57% – 20.67%),