

**Introduction/Background** In Algeria, breast cancer has become a major public health problem with a real urgency of intervention and management. The aim of this work was to analyse the epidemiological, clinical, therapeutic and evolutionary particularities of breast cancer in young women under the age of 30.

**Methodology** This is a retrospective cohort of 35 patients under 30 years of age with breast cancer who were treated at the radiotherapy department of the cancer center Tlemcen, Algeria between September 2017 and August 2021.

**Results** The median age was 28 (20–30) years, the left breast was affected in 51.4% of cases (18 patients) and the external site of the tumor predominated in 45.7% of cases (16 patients). 85.7% of patients had invasive ductal carcinoma. The tumors were classified as T1 in 25.7%, T2 in 57.1%, T3 in 8.5% and T4 in 8.5% of cases. 51.4% of the cases had lymph node involvement and the median histological size was 35 mm (0–70). 29 patients (82.8%) underwent radical surgery (patey) and 6 patients (17.1%) underwent conservative surgery. Chemotherapy was used in 11.4% of cases as neoadjuvant and in 88.5% of cases as adjuvant. 25 patients (71.4%) received adjuvant hormonal therapy and 12 patients (34.2%) received targeted therapy. Locoregional radiotherapy was delivered in all patients at a biological dose of 50GY to the chest wall, supra and subclavicular lymph nodes ± tumor bed boost. Dermatitis was found in 100% of cases, dysphagia in 22.8%, pain in 20%, fibrosis in 14.2% and edema in 14.2% of cases. The median follow-up was 24.5 months (1–49) with only one metastatic relapse.

**Conclusion** Although our series showed satisfactory results, breast cancer in young women remains of unfavorable prognosis.

2022-RA-188-ESGO

#### OVARIAN CARCINOMA METASTASIS BREAST MIMICKING THE PRIMARY BREAST CARCINOMA: CASEREPORT AND REVIEW LITERATURE

<sup>1,2</sup>Nghia Trong Doan, <sup>2</sup>Yen Thi Ngoc Nguyen, <sup>2</sup>Tu Anh Thai, <sup>2</sup>Tien van Nguyen. <sup>1</sup>Oncology, University of Medicine and Pharmacy, Ho Chi Minh, Viet Nam; <sup>2</sup>Oncology hospital at Ho Chi Minh city, Ho Chi Minh city, Viet Nam

10.1136/ijgc-2022-ESGO.785

**Introduction/Background** Report one case of ovarian carcinoma metastasis breast mimicking the primary breast carcinoma

**Methodology** Case report and review literature

**Results** Breast is an uncommon metastatic site of ovarian cancer with only 0.03 – 0.6% of all breast malignancies. There are only 110 cases documented until 2015. The rarity of this circumstance can lead to insufficient diagnosis and

overtreatment. The case in our report was the 55-year old female. She had the breast tumor, ovarian tumor and supraclavicular lymph node. The H&E images of all tumor showed adenoma carcinoma. We performed IHC stain eight markers, including WT1, PAX8, P16, p53, ER, PR, Mamma-globulin and Ki67. All tumor had the similar results with this panel markers. Detailly, WT1, PAX8, P16, p53, ER were positive and PR, Mamma-globulin were negative. According to these results, we concluded this was the case of ovarian carcinoma metastasis to breast and supraclavicular lymph node.

**Conclusion** Surgical pathology and Immunohistochemistry play an important role in our case of determining the origin of the metastatic lesion of the breast therefore they give us precise diagnosis and staging. Sufficient assessment of this patient give us the reasonable mangement orientation without any overzealous treatment.

2022-RA-215-ESGO

#### CLINICAL CASES OF ATYPICAL POLYPOID ADENOMYOMA: SINGLE-CENTER REPORT

<sup>1</sup>Ana-Meyra Potkonjak, <sup>2</sup>Tanja Leniček, <sup>1</sup>Ante Vuković, <sup>1</sup>Dražan Butorac, <sup>1</sup>Hrvojka Soljačić Vraneš. <sup>1</sup>Gynecology and Obstetrics, Sestre milosrdnice University Hospital Center, Zagreb, Croatia; <sup>2</sup>Ljudevit Jurak University Department of Pathology, Sestre milosrdnice University Hospital Center, Zagreb, Croatia

10.1136/ijgc-2022-ESGO.786

**Introduction/Background** Atypical polypoid adenomyoma (APA) is a rare intrauterine pathological finding, which can often be misdiagnosed as malignancy. It mostly affects premenopausal women. Therefore, treatment is predominantly conservative including hysteroscopic transcervical resection (TCR), dilatation and curettage (D&C), and hormonal therapy. Due to the high recurrence rate, the most effective treatment for perimenopausal and postmenopausal women is hysterectomy. Mortality rates have not been reported. Following study analyzed four cases of APA, diagnosed after TCR of intrauterine pathology in a single center.

**Methodology** Clinicopathological characteristics of APA were assessed by retrospective analysis of medical records containing patients age, parity, body mass index, menstrual status, symptoms, associated pathology, and treatment.

**Results** Four cases of APA were confirmed within specimens provided by TCR (figure 1). The patients ages varied between 31 and 52 years; two patients were premenopausal and two were perimenopausal. Three patients underwent previous endometrial sampling, which revealed either endometrial polyp or simple endometrial hyperplasia (table 1.). A 31-year-old patient with a 5 mm large intracavitary abnormality on ultrasound, underwent TCR. The abnormality (APA) was completely removed and successful pregnancy was achieved 14 months later.

**Abstract 2022-RA-215-ESGO Table 1** Clinicopathological characteristics of patients diagnosed with APA

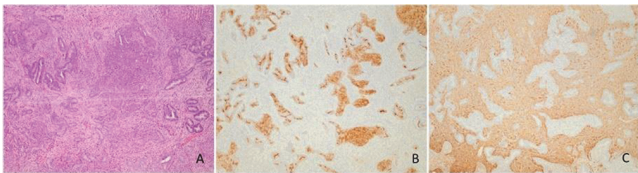
	age	BMI	parity	menstrual status	clinical symptoms	largest diameter (mm)	associated pathohistological findings	type of treatment
case 1	38	31.2	0	premenopaus	infertility, AUB, uterine cavity mass	14	none	conservative
case 2	52	27.1	0	perimenopaus al	AUB, uterine cavity mass	11	glandular polyp	hysterectomy
case 3	31	20	1	premenopaus	uterine cavity mass	5	none	conservative
case 4	48	36	1	perimenopaus al	AUB, uterine cavity mass	18	none	hysterectomy

Two months after delivery, TCR provided normal histopathological specimen.

A 38-year-old patient presented with infertility and abnormal uterine bleeding (AUB). After TCR of APA, patient started assisted reproductive treatment with frequent ultrasound monitoring.

For patients aged 48 and 52 year, who presented with intrauterine mass (largest diameter of 18 mm) and AUB, hysterectomy was recommended after confirmation of APA by TCR.

Clinical symptoms of APA included infertility and AUB. Transvaginal ultrasonography confirmed intracavitary lesions in all patients, with largest diameter of 18 mm and glandular polyp as associated pathology.



**Abstract 2022-RA-215-ESGO Figure 1** A typical polypoid adenomyoma contain irregular, often architecturally complex endometrioid gland, with squamous morules (B – CD10), set within myomatous stroma (C – SMA)

**Conclusion** In our institution, two patients are being conservatively treated for APA with one case of successful pregnancy. Due to the rarity of APA, further observation will evaluate the success of conservative treatment.

\$\$\$MISSING OR BAD GRAPHIC SPECIFICATION (775D89EE-4F2F-4854-9973-8506F2BAC2EC) \$\$\$

### 2022-RA-269-ESGO PRIMARY MALIGNANT FOLLICULAR LYMPHOMA OF THE UTERINE CERVIX, TWO CASE REPORTS

Janire Zarragoitia, Sonia Baulies, Francesc Tresserra Casas, Rafael Fabregas, Francesc Fargas. *Hospital Universitari Dexeus, Barcelona, Spain*

10.1136/ijgc-2022-ESGO.787

**Introduction/Background** The incidence of non-Hodgkin lymphomas in Spain is 10.8/100.000 women. The extranodal lymphomas account for the 15%, only 1% being originated in the genital tract. Their management, prognosis and treatment efficacy is controverted.

**Methodology** First case: a 36-year-old asymptomatic patient undergoes annual checkup. The pelvic ultrasound shows a 31x37 mm cervical mass with *score 4* vascularization, confirmed by MRI. Cytology and HPV come up negative. A cervical biopsy with immunohistochemistry analysis is performed, with positive results for BCL2-6, CD20, CD23 and CD5. The PET-CT shows no signs of metastases nor pathologic lymph nodes. Second case: a 45-year-old asymptomatic patient undergoes annual checkup. The pelvic ultrasound shows a 48x36 mm cervical mass with *score 4* vascularization, confirmed by MRI. Cytology and HPV come up negative. A cervical biopsy with immunohistochemistry analysis is performed, with positive results for BCL6 and CD20. The PET-CT shows a suspicious right iliac lymph node, but no signs of distal metastases.

**Results** In case n°1, due to the desire of future pregnancy the patient undergoes chemotherapy after fertility preservation, who is in remission at this moment. In case n°2, the patient undergoes total hysterectomy and periodic checkups, also in remission at this moment.

**Conclusion** Less than 1/175 extra nodal lymphomas are likely to originate in the genital tract, and it is important to make a differential diagnosis with cervical cancer because both entities can present as vaginal bleeding, dyspareunia, or cervical mass. Diagnosis can be challenging due to frequent negative results from cytology, so the biopsy and immunohistochemical analysis is essential. Further investigation is needed in regard of the best treatment for this type of extra nodal lymphomas. Nowadays, it consists of neoadjuvant/adjuvant chemotherapy combined with surgery, reaching the complete response in 75% of cases and survival rates of up to 90% after 5 years, according to the latest studies.

### 2022-RA-442-ESGO FALLOPIAN TUBE CYTOLOGICAL FINDINGS IN WOMEN UNDERGOING SALPINGECTOMY AND CORRELATION WITH THE ADNEXAL PATHOLOGY

<sup>1</sup>Viktoria Psomiadou, <sup>1</sup>Sofia Lekka, <sup>2</sup>Theodoros Panoskaltis, <sup>3</sup>Eleni Tsouma, <sup>3</sup>Natasa Novkovic, <sup>4</sup>Helen Trihia, <sup>4</sup>Olympia Tzaida, <sup>1</sup>Dimitrios Korfias, <sup>1</sup>Panagiotis Giannakas, <sup>1</sup>Christos Iavazzo, <sup>5</sup>Christos Papadimitriou, <sup>2</sup>Nikolaos Vlahos, <sup>1</sup>George Vorgias. <sup>1</sup>Gynaecological Oncology, Metaxa Memorial Cancer Hospital, Piraeus, Athens, Greece; <sup>2</sup>Second Department of Obstetrics and Gynecology, Medical School, University of Athens "Aretaieio" Hospital, Athens, Greece; <sup>3</sup>Cytology Laboratory, Metaxa Memorial Cancer Hospital, Piraeus, Athens, Greece; <sup>4</sup>Pathology, Metaxa Memorial Cancer Hospital, Piraeus, Athens, Greece; <sup>5</sup>Oncology Unit, 2nd Department of Surgery Aretaieion Hospital, The National and Kapodistrian University of Athens, Athens, Greece

10.1136/ijgc-2022-ESGO.788

**Introduction/Background** Epithelial Ovarian Cancer (EOC) is still the most lethal gynecological malignancy, with approximately 21,410 new cases and 13,770 deaths in the USA in 2021. Many theories have been proposed in terms of clarifying the etiology and the carcinogenesis -mechanism of EOC. Based on the latest trends, ovarian, fallopian tube, and peritoneal cancer are incorporated into the same group as it is suggested that high-grade extrauterine tumors of serous histology originate from the fallopian tube.

**Methodology** We ex vivo collect salpingeal epithelial cells from the fibria directly from fresh fallopian tube specimens from women undergoing salpingectomy for any indication. The cytomorphological characteristics of the salpingeal cells are subsequently being evaluated and categorised into malignant and non -malignant. Finally, the ipsilateral adnexae are examined with the SEE-FIM (Sectioning and Extensively Examining the FIMbriated End) protocol and the pathology reports are correlated with the cytological findings. Our research protocol is ongoing and is designed to include a total of 300 patients in order to confirm the sensitivity and specificity of salpingeal cytology as a method in the early diagnosis of extrauterine gynecological malignancies.

**Results** So far, we have obtained 343 salpingeal brushings from a total of 214 patients. The sensitivity of cytology regarding distinguishing malignant from non-malignant tumors, was 69.64% (95% CI: 55.90% – 81.22%), while its specificity 75.96% (95% CI: 70.59% – 80.79%). Cytology's positive predictive value (PPV) was 16.33% (95% CI: 12.57% – 20.67%),