

2022-RA-1451-ESGO

CRITICAL CARE MANAGEMENT FOLLOWING CYTOREDUCTIVE SURGERY WITH HYPERTHERMIC INTRAPERITONEAL CHEMOTHERAPY: NOT ROUTINELY INDICATED

¹SL Aronson, ²RM van Stein, ³FJ Hendriks, ⁴K Sikorska, ⁵API Houwink, ⁶PFE Schutte, ³CD de Kroon, ⁶GS Sonke, ²WJ van Driel. ¹Gynaecological Oncology, Medical Oncology, Netherlands Cancer Institute – Antoni van Leeuwenhoek, Amsterdam, Netherlands; ²Gynaecological Oncology, Netherlands Cancer Institute – Antoni van Leeuwenhoek, Amsterdam, Netherlands; ³Gynecology, Leiden University Medical Center, Leiden, Netherlands; ⁴Biometrics, Netherlands Cancer Institute – Antoni van Leeuwenhoek, Amsterdam, Netherlands; ⁵Anesthesiology and Intensive Care, Netherlands Cancer Institute – Antoni van Leeuwenhoek, Amsterdam, Netherlands; ⁶Medical Oncology, Netherlands Cancer Institute – Antoni van Leeuwenhoek, Amsterdam, Netherlands

10.1136/ijgc-2022-ESGO.718

Introduction/Background Hyperthermic intraperitoneal chemotherapy (HIPEC) is increasingly used for patients with stage III ovarian cancer undergoing interval cytoreductive surgery (CRS). It is uncertain whether routine postoperative admission to an intensive care setting following CRS-HIPEC for ovarian cancer is necessary. We estimated the incidence of patients requiring critical care support and tried to identify patients in whom admission to an intensive care setting can be safely omitted.

Methodology We analyzed 154 patients with primary ovarian cancer, who underwent CRS-HIPEC between 2007–2021 in two Dutch HIPEC-centers. Patients were routinely transferred to an Intensive Care Unit (ICU) or Post Anesthesia Care Unit (PACU). Patients requiring critical care support were identified by predefined criteria based on respiratory, circulatory, and metabolic parameters. Logistic regression analyses with backward selection were used to predict the need for critical care support in individual patients and the are-under-the-ROC-curve (AUC) of the model was estimated.

Results Median ICU/PACU length of stay was 21 hours (IQR 19–29) and 38% of patients received postoperative critical care support, mainly consisting of hemodynamic interventions (37%). Independent predictors for critical care support are age, blood loss, norepinephrine dose during surgery, and peritonectomy extent (table 1). AUC of the model is 0.81 (95% CI 0.73–0.88). Using a 20% cut-off to define low-risk of critical care support, 37% of patients would be eligible to forego ICU/PACU admission.

Abstract 2022-RA-1451-ESGO Table 1 Multivariable logistic regression analysis for probability of critical care support (N=154, events=58)

Independent predictors	OR	95% CI	P-value	B
Age > 70 years	4.79	1.93-11.91	0.00	1.57
Blood loss (liter)	2.16	1.08-4.32	0.03	0.77
Norepinephrine dose during surgery (µg/kg/hour)	1.49	1.22-1.82	0.00	0.40
Extensive peritonectomy (in ≥ 2 regions)	3.74	1.25-11.20	0.02	1.32

OR: Odds ratio, CI: confidence interval

Conclusion Postoperative admission to an intensive care setting is not routinely required for ovarian cancer patients undergoing CRS-HIPEC. Following prospective validation, a decision tool based on pre- and intra-operative parameters can help to identify low-risk patients.

2022-RA-1453-ESGO

CHEMOTHERAPY RESPONSE SCORE AS A PREDICTOR OF SURVIVAL AMONG PATIENTS UNDERGOING INTERVAL DEBULKING SURGERY FOR OVARIAN CANCER

¹Ioannis Rodolakis, ²Michalis Lontos, ¹Konstantina Papadatou, ¹Anastasia Prodromidou, ¹Dimitrios Haidopoulos, ¹Alexandros Rodolakis, ²Aristotelis Bamias, ¹Nikolaos Thomakos. ¹First department of obstetrics and gynaecology, National and Kapodistrian University of Athens, ATHENS, Greece; ²National and Kapodistrian University of Athens, ATHENS, Greece

10.1136/ijgc-2022-ESGO.719

Introduction/Background Neo-adjuvant chemotherapy has been adopted as an alternative mode of therapy for surgically irresectable ovarian cancer in cases of diffuse dissemination, where primary debulking surgery is not feasible or when patient status does not allow extensive procedures. The response to chemotherapy can be evaluated objectively with the use of standard pathology. In the present study we evaluated the prognostic significance of chemotherapy response score in predicting survival rates of patients undergoing interval debulking surgery.

Methodology The study is based in a retrospective cohort of patients. We collected data from 48 ovarian cancer patients that received at least 3 cycles of neo-adjuvant chemotherapy. The evaluation of chemotherapy response score was based on pathology sections of the omentum and ovaries. Following interval debulking surgery chemotherapy was continued until the completion of 6 cycles of perioperative treatment. Twenty two patients received maintenance therapy with bevacizumab following completion of chemotherapy.

Results Median follow-up was 52.5 months ranging between 38.5 and 70.1 months. Agreement rates of chemotherapy rates among omental and ovarian biopsies were moderate (CRS 1 22.9% vs 37.5% respectively, CRS 2 37.5% vs 35.4% and CRS 3 33.3% vs 16.7%). Progression free survival rates gradually declined among patients with omental CRS 3 and those with CRS 1 (18.7 vs 14 vs 10.3 months respectively, $p=.003$). Similar results were observed for overall survival rates, however, the results were not statistically significant (42.3 vs 32 vs 29.3 months respectively, $p=.182$).

Conclusion Evaluation of the chemotherapy response score from omental biopsies is an accurate predictor of survival rates of ovarian cancer patients undergoing interval debulking surgery, irrespective of the use of maintenance therapy. Further studies are needed to support our findings.

2022-RA-1456-ESGO

OVARIAN CANCER METASTASES IN THE LIVER AREA: A RETROSPECTIVE ANALYSIS OF SURGICAL, INTRAOPERATIVE AND POSTOPERATIVE OUTCOMES ACCORDING TO A STANDARDIZE ANATOMO-SURGICAL CLASSIFICATION

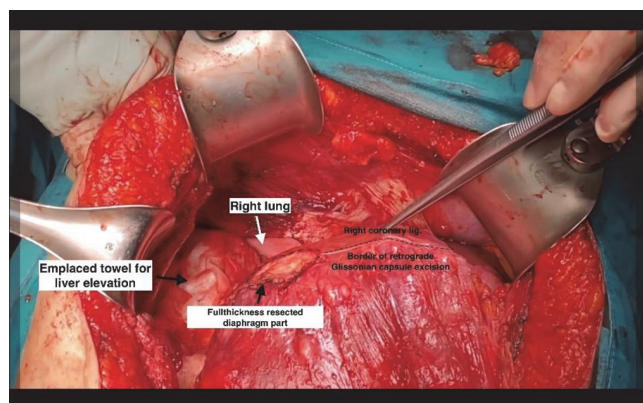
¹Andrea Rosati, ²Matteo Pavone, ²Antonella de Palma, ¹Carmine Conte, ¹Valentina Ghirardi, ³Agostino Maria de Rose, ^{3,2}Felice Giulante, ^{1,2}Giovanni Scambia, ^{1,2}Anna Fagotti. ¹Department Woman and Child Health and Public Health, Fondazione Policlinico Universitario A. Gemelli IRCCS, Rome, Italy; ²Università Cattolica del Sacro Cuore, Rome, Italy; ³Hepatobiliary Surgery Unit, Fondazione Policlinico Universitario A. Gemelli IRCCS, Rome, Italy

10.1136/ijgc-2022-ESGO.720

Introduction/Background We recently developed an anatomico-surgical classification for ovarian cancer (OC) metastases in the liver area consisting in 5 different types (Type-1:Glisson's, Type-2:Ligamentous, Type-3:Gallbladder, Type-4:Hepatic hilum, Type-5:Liver parenchymal). This study aims to evaluate whether this classification is able to identify patients at greater risk of intra and postoperative complications and with increased surgical complexity.

Methodology All epithelial advanced-OC patients who underwent primary or secondary surgery with perihepatic liver involvement were retrospectively retrieved. Patients were classified according to our published anatomico-surgical classification and further clustered into four major Classes: Class-I or 'Peritoneal' (including Type 1,2,3), Class-II or 'Hepatoceliac lymph-nodes' (Type-4), Class-III or 'Parenchymal' (Type-5) and Class IV or Mixed (≥ 2 classes).

Results 615 patients were identified, and Class I resulted as the most commonly represented (337 cases, 54.8%). The distribution of surgical complexity score (SCS) was superimposable among classes ($p=0.239$) while operative time and estimated blood loss were significantly longer/higher in Class IV (Mixed) ($p<0.001$). Intraoperative transfusions were more frequent in Class IV (30.4%) and less reported in Class-III (11.9%) ($p=0.004$); vascular injuries were significantly grouped in Class II (8%) ($p=0.009$). Class II and IV were more frequently associated to severe postoperative complications ($p=0.008$). Moreover, specific complications were found in each Class: perihepatic collection and intrahepatic hematoma/abscess in Class-III (respectively: $p=0.003$, $p>0.001$); pleuric effusion, sepsis, anemia and 'other complications' in Class IV (respectively: $p=0.002$, $p=0.004$, $p=0.03$, $p=0.03$). At Multivariate analysis SCS 3 and macroscopic residual tumor were identified as risk factors for severe postoperative complications (respectively: OR: 3.922, $p=0.003$ and OR: 1.748, $p=0.048$). Conversely, Class-I and III resulted to be at decreased risk for severe postoperative complications compared to Class IV.



Abstract 2022-RA-1456-ESGO Figure 1

Conclusion Our classification represents a useful and reliable tool, able to stratify patients with OC metastases in the liver area in Classes with different surgical outcomes and different postoperative complication profile.

2022-RA-1459-ESGO

MALIGNANT STRUMA OVARIII IN AN ASYMPTOMATIC NULLIPAROUS 20-YEAR-OLD PATIENT: A CASE REPORT

Eleftherios G Klonos, CH Zimperdikas, G Pados, G Grimbizis, T Theodoridis, S Tsaipakidou, A Tolkos, T Karalis. *st. Department of Ob/Gyn Papageorgiou General Hospital, Aristotle University of Thessaloniki, Thessaloniki, Greece*

10.1136/ijgc-2022-ESGO.721

Introduction/Background Adnexal pathology and adnexal tumors are common accidental findings in a regular gynecological screening visit. Ovarian teratomas are germ cell tumors that derive from the three germ layers and commonly contain teeth, hair, bone, or thyroid tissue. They consist of 20% of all ovarian tumors. Ovarian teratomas which contain at least 50% thyroid tissue are known as struma ovarii. Malignant struma ovarii are found in less than 2% of mature benign teratomas.

Methodology A 22-year-old nulliparous woman, with a history of an adnexal tumor in 2020 in her annual gynecological screening. Ultrasound (US) examination showed the presence of a cystic lesion on the left ovary with a maximal diameter of 6.5 cm and mild free fluid in the pouch of Douglas. To further assess the findings, a magnetic resonance imaging (MRI) was performed during a 12-month follow-up and confirmed a moderate adnexal cystic lesion measuring 67 mm x 82 mm x 56 mm, lying in the anatomical position of the left ovary. Tumor markers and thyroid function blood tests were within normal limits. The patient underwent a laparoscopic cystoscopy after two years of observation. The intraoperative finding was an anteverted mobile uterus with a cystic lesion in the left ovary about 8 mm x 5.5 mm x 6 mm. It was removed with an endobag. The cyst was opened, and there were serous and solid elements inside. The pathology report showed a malignant struma ovarii.

Results The patient underwent a full thyroid screening with normal findings. After detailed counseling, she decided on a twice-a-year follow-up by us and the endocrinologists. She remains asymptomatic and euthyroid.

Conclusion Malignant struma ovarii is a rare ovarian tumor, which is only diagnosed by pathology reports after surgery. There is controversy regarding its management, and it should be individualized.

2022-RA-1464-ESGO

CLINICAL BEHAVIOR OF HIGH-GRADE OVARIAN CANCER (HGOC) PATIENTS WITH NON CONTRIBUTIVE GIS RESULTS (NA) BY MYRIAD

¹Felix Blanc-Durand, ²Sophie Cotteret, ²Catherine Genestie, ²Etienne Rouleau, ²Judith Michels, ²Emeline Colomba-Blameble, ²Maria Kfoury, ²Patricia Pautier, ²Alexandra Leary. ¹Medical Oncology, Institut Gustave Roussy, Villejuif, France; ²Institut Gustave Roussy, Villejuif, France

10.1136/ijgc-2022-ESGO.722

Introduction/Background Platinum sensitivity and homologous recombination deficiency (HRD) are predictive biomarkers for PARP inhibitors (PARPi) benefit in HGOC patients. The only