

CD68 and CD163 were highly significantly expressed in cancers compared with BOT ( $p < 0.001$  and  $0.004$  respectively). Similarly, stromal CD163 mean count and percentage were more abundant in malignant tumours ( $p = 0.03$  and  $0.02$ ). Mean stromal CD68 count and percentage correlated positively with mean CD163 stromal count and percentage ( $p = 0.02$ ). Risk of malignancy index was a significant predictor of ovarian cancer diagnosis ( $p = 0.04$ ). 15 cancer patients died of the disease. There was no significant association between TAM expression and patient survival.

**Conclusion** TAM subtypes analysis in ovarian neoplasia of young women confirms higher expression in malignant compared with borderline ovarian tumours. This might have implications on their pathogenesis and management.

### 2022-VA-1320-ESGO A NOVEL LAPAROSCOPIC APPROACH TO LARGE MALIGNANT OVARIAN MASSES

<sup>1</sup>Pearl SY Tong, <sup>2</sup>Yang Yang Lee, <sup>1</sup>Khalil Razvi. <sup>1</sup>Obstetrics and Gynaecology, National University Hospital, Singapore, Singapore; <sup>2</sup>Paediatric Surgery, National University Hospital, Singapore, Singapore

10.1136/ijgc-2022-ESGO.690

**Introduction/Background** The uptake of a minimally invasive approach in the management of gynaecological malignancies has increased over the years, because of advancement in skills, equipment, and the advantages of a swifter recovery, lower blood loss and reduction in the length of hospitalisation. However, this has been viewed with much hesitance in the realm of ovarian malignancies due to fear of spill and incomplete clearance of tumour, especially when the tumours are large.

**Methodology** We describe two cases in which the large pelvic masses (both about 12 cm in size) were handled in an oncologically sound manner, allowing for accurate intra abdominal assessment of disease, and removal of the ovarian mass without surgical spill. The first is that of an ovarian immature teratoma with gliomatosis peritonei in a 6 year old girl, the second is that of a 35 year old lady with a mucinous ovarian carcinoma.

**Results** In the case of the 6 year old, a computed tomography scan showed a 12 cm heterogenous suspicious looking ovarian mass with significantly elevated alpha-feto-protein levels, with no evidence of distal or nodal metastases. A laparoscopic approach was undertaken to remove this mass with the steps outlined below. 1. Supraumbilical camera port placement and intra abdominal survey 2. Peritoneal washings 3. Tilting patient to expose the gonadal vessels; isolating the ureter before performing a unilateral salpingo oophorectomy (USO) 4. Putting the entire USO specimen into a 6 litre retrieval bag and removal via the suprapubic port with manual morcellation 5. Omental biopsy, examination of bowel and mesentery, digital palpation of the retroperitoneal lymph nodes performed 6. Excision of pouch of Douglas (POD) lesions performed. The second case was approached in a similar manner, excluding the final step.

**Conclusion** In carefully selected cases of ovarian malignancy, a minimally invasive approach can be undertaken safely.

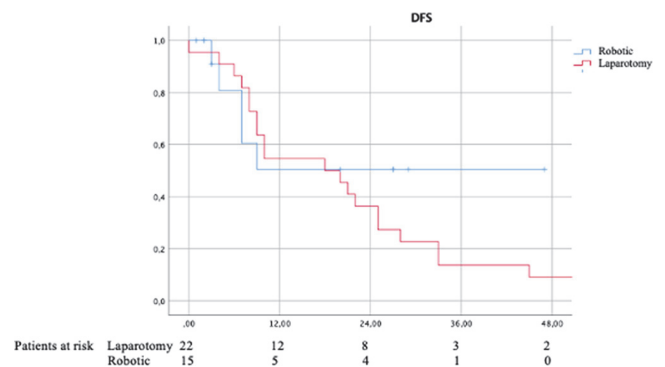
### 2022-RA-1326-ESGO INTERVAL DISEASE SURGERY BY ROBOTIC APPROACH IN OVARIAN CANCER

Carlos Ortega, Jordi Ponce, Marc Barahona, Sergi Fernández, Lola Martí. *Servicio de Ginecología, Hospital de Bellvitge, Hospitalet de Llobregat, Spain*

10.1136/ijgc-2022-ESGO.691

**Introduction/Background** Ovarian cancer is one of the most lethal gynecological malignancies. This is because early diagnosis is difficult, and it usually presents in advanced stages. In these cases, randomized controlled trials have indicated that neoadjuvant chemotherapy (NACT) followed by interval disease surgery (IDS) offers similar of oncological and survival outcomes than primary surgery, and tumor burden remains is the principal poor prognostic factor. Historically, the surgical approach for these patients was by an explorative laparotomy. The role of the minimal invasive surgery (MIS) remains unclear. Thus, the purpose of our study is to evaluate the application of robotic surgery.

**Methodology** A cohort retrospective study with prospectively collected data was performed including patients with advanced ovarian cancer who underwent to NACT and presented a radiological and serological favourable response and was possible to perform an optimal cytoreduction (R0) by robotic surgery. Clinicopathological and survival outcomes, including overall survival (OS) and disease-free survival (DFS), were collected and analyzed. We have compared this selected group of patients with a historical cohort that includes patients with similar response rates who underwent to laparotomic surgery also obtaining an optimal cytoreduction.



**Abstract 2022-RA-1326-ESGO Figure 1** Disease free survival kaplan-meier graphic

**Results** The study includes a total of 15 patients who performed a robotic surgery and 22 a laparotomic surgery. In the robotic surgery cohort, the DFS at 3 years was 60.0% (CI 95% 32.8–87.2%) and 9.1% (CI 95% 0–21.1%) in the laparotomic, although no statistically significant differences were found between them (Log-Rank test  $p = 0.343$ ). The OS at 3 years in the robotic surgery cohort was 92.0% (CI 95% 77.0–100%) and in the laparotomy group 52.7% (CI 95% 31.1–74.2%), also without significant differences (Log-Rank test  $p = 0.225$ ).