

prognostic variables. Univariate and multivariate analysis showed that none of the parameters were associated with OS. **Conclusion** Among the parameters of FDG PET/CT, TLG 3.0 was the independent prognostic factor for DFS and maybe associated with overall survival.

2022-RA-827-ESGO

SENTINEL NODE BIOPSY DIMINISHES DE USE OF ADJUVANT THERAPY IN WOMEN WITH EARLY CERVICAL CANCER IN THE SUCCOR COHORT

¹Arantxa Berasaluce Gómez, ²Luis Chiva de Agustín, ²Félix Boria Alegre, ²Teresa Castellanos, ²Daniel Vázquez Vicente, ³Lidia Sancho Rodríguez, ⁴Juan Luis Alcázar Zambrano, ²Monica Gutiérrez Martínez, ⁴Nabil Manzour Sifontes, ⁴José Ángel Mínguez Milió, ⁴Enrique María Chacón Cruz, ¹Nerea Martín Calvo. ¹Medicina Preventiva y Salud Pública, Universidad de Navarra, Pamplona, Spain; ²Obstetrics and Gynecology, Clínica Universidad de Navarra, Madrid, Spain; ³Nuclear Medicine, Clínica Universidad de Navarra, Madrid, Spain; ⁴Obstetrics and Gynecology, Clínica Universidad de Navarra, Pamplona, Spain

10.1136/ijgc-2022-ESGO.63

Introduction/Background The aim of the study was to compare the use of adjuvant therapy in women with stage IB1 cervical cancer depending on the method used to diagnose lymphatic node invasion.

Methodology We used data from the SUCCOR study, that collected information from 1049 women operated on stage IB1 cervical cancer between January 2013 and December 2014. Inverse probability weighting was used to adjust for surgical approach, use of uterine manipulator, lymphovascular space invasion, parametrial space invasion and conization, such that there were no significant differences between both groups. We calculated the adjusted proportion of women who received adjuvant therapy depending on the lymph node diagnosis method and compared disease free and overall survival using Cox regression.

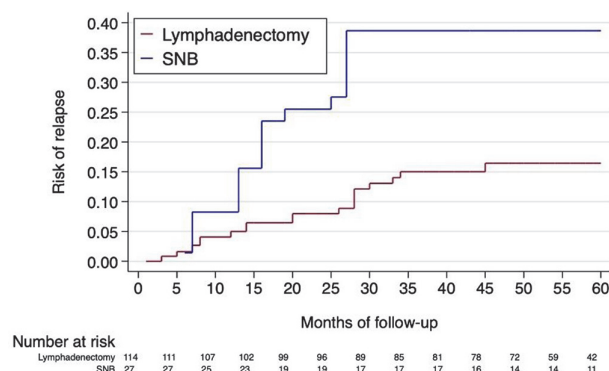
Results The adjusted proportion of women who received adjuvant therapy was 33.8% in the sentinel node biopsy (SNB) group and 44.7% in the lymphadenectomy group ($p=0.02$), although the proportion of positive nodal status in both groups was similar (14% and 10.7% respectively. $p=0.30$). That difference was even greater in women with negative nodal status (adjusted difference 13.7%; $p=0.002$) and in the analysis restricted to women with negative nodal status and positive SEDLIS criteria (adjusted difference 31.2%; $p=0.01$). In this last group, women who underwent a SNB had an increased risk of relapse (HR: 2.50; 95%CI 0.98–6.33) and risk of death (HR: 3.5; 95% CI 1.04–11.7) compared to those who underwent lymphadenectomy.

Abstract 2022-RA-827-ESGO Table 1 Proportion of women in the SUCCOR cohort that underwent adjuvant therapy by method of lymph node diagnosis

Overall sample				
	SNB	Lymphadenectomy	Adjusted difference*	p
Percentage of women that received adjuvant treatment.	33.8%	44.1%	10.9%	0.015
Analysis restricted to women with negative nodal status				
	SNB	Lymphadenectomy	Adjusted difference*	p
Percentage of women that received adjuvant treatment.	25.1%	38.1%	13.7%	0.002
Women with positive Sedlis criteria	43.3%	74.5%	31.2%	0.011
Women with negative Sedlis criteria	22.8%	29.3%	6.57%	0.212

*Adjusted for surgical approach, use of uterine manipulator, lymphovascular space invasion, parametrial space invasion and conization

Nelson-Aalen curve for Disease-free Survival
(SNB vs. Lymphadenectomy in N0 SEDLIS+)



Abstract 2022-RA-827-ESGO Figure 1

Conclusion Women with the same clinical characteristics were less likely to receive adjuvant therapy if their nodal invasion was determined using SNB compared to lymphadenectomy. This difference was at the expense of women with negative nodal status but positive SEDLIS criteria. These results suggest a lack of therapeutic measures when a negative result is obtained by SNB, which may have an impact on the risk of recurrence and survival.

2022-RA-862-ESGO

SIMULTANEOUS 18F-FDG PET/MRI AS SINGLE IMAGING METHOD IN THE ASSESSMENT OF CERVICAL CANCER- A PILOT STUDY

¹Elisabeth Hedlund, ²Björg Jonsdóttir, ¹Håkan Ahlström, ²Karin Ståhlberg. ¹Uppsala University, Department of Surgical Sciences, Section of Radiology, Uppsala, Sweden; ²Uppsala University, Department of Women's and Children's Health, Uppsala, Sweden

10.1136/ijgc-2022-ESGO.64

Introduction/Background Simultaneous PET/MRI is a relatively new imaging method, and its role in diagnostics of gynaecologic cancer is unclear. The aim of the present study is to investigate the use of PET/MRI in the assessment of cervical cancer and its potential to be used as a single imaging method.

Methodology In 2015–2016, 15 patients with primary cervical cancer FIGO stage IB or higher, at Akademiska Sjukhuset, Uppsala, Sweden, were prospectively enrolled for a simultaneous whole-body 18F-FDG (Fluorodeoxyglucose) PET/MRI. The PET/MRI images were evaluated in consensus by a fourth-year resident in radiology and a senior consultant for the following parameters; maximal tumor size, SUV-max, direct tumor extension to adjacent structures as the parametrium and pelvic wall, corpus, vagina, ovaries, presence of lymph nodes metastases and distant metastasis. The results of staging from PET/MRI were compared with standard radiology (Diffusion weighted-MRI and CT or PET/CT) and clinical staging. Furthermore, the separate contribution of the PET component in PET/MRI was analysed.

Results Five of the patients were treated with primary surgery and ten with radio-chemotherapy. In nine patients, staging with PET/MRI differed from clinical staging, whereof eight were upstaged (table 1). PET/MRI and standard imaging

Abstracts

methods were comparable in detecting tumor extension and equally good at detecting lymph node metastases and distant metastases. The radiologists experienced more certainty in analysing malignant lesions with the additional information of PET, however, the lesions were more easily defined on MRI.

Abstract 2022-RA-862-ESGO Table 1 Staging in cervical cancer. Comparison of integrated PETMRI, standard imaging methods and clinical examination

Number	Tumor size Pathology report craniocaudal x invasion (mm)	Tumor size MRI (mm)	ST/7- max	Clinical Estimation of stage	Staging results standard imaging techniques	Staging results PET/MRI
1	-	47	13.7	IIB	IVA ²	IVA
2	23 x 13	35	30.7	IB2	IIB ^{2*}	IIA1
3	-	37	19.7	IB3	IIB ²	IIB ^{***}
4	-	56	15.3	IIB	IIIC ²	IIIC1
5	29 x 12	42	16.7	IIA1	IIA2 ¹	IIA2
6	-	56	54.3	IIB	IIB ⁴	IIB
7	-	29	14.2	IB2	IIIC1 ¹	IIIC1
8	-	107	20.6	IVB	IVB ¹	IVB
9	13 x 4	23	6.6	IB2	IB2 ²	IB2
10	-	37	11.1	IIB	IIB ⁴	IIB
11	-	63	26.2	IIIB	Not done ³	IIIC1
12	20 x 15	31	14.5	IB2	IB2 ²	IB2
13	25 x 35	13	5.7	IB2	IB1 ¹	IB1
14	-	47	14.2	IIB	IVA ¹	IVA
15	-	23	21.9	IVA	IVA ¹	IVA

*Suspicion of parametrial invasion on MRI but not on PET/MRI

** Suspicion of parametrial invasion on PET/MRI but not on MRI

¹ MRI+ CT

² MRI+PET/CT

³ No contrast-enhanced CT performed

Conclusion The present study indicates that PET/MRI gives similar staging results as routine imaging methods in staging of cervical cancer. Presumably, PET/MRI as a single imaging method, could replace the common standard of MRI and PET/CT in advanced cervical cancer and thus shorten time to start of treatment and save resources.

2022-VA-864-ESGO

RECTOVAGINAL FISTULA REPAIR BY MARTIUS FLAP AFTER EXCLUSIVE CHEMO-RADIATION IN ADVANCED CERVICAL CANCER PATIENT. A CASE REPORT

Vito Andrea Capozzi, Isabella Rotondella, Alessandra de Finis, Giulia Armano, Diana Butera, Michela Gaiano, Luciano Monfardini, Elisa Scarpelli, Giuseppe Barresi, Davide Scebbia, Carla Merisio, Tullio Ghi, Roberto Berretta. *University of Parma, PARMA, Italy*

10.1136/ijgc-2022-ESGO.65

Introduction/Background Rectovaginal fistula (RVF) is an abnormal communication between rectum and vagina.

Common causes are: pelvic irradiation, obstetric trauma, Crohn's disease and postsurgical complications. Conservative treatments are usually performed in patients unfit for surgery and are characterized by high recurrence rate. Common surgical approach includes fistula debridement and repair or flap interposition. Simple anatomic fistula repair is associated with lower success rates compared to vascularized flap interposition. The Martius flap (MF) is a vascularized muscle- adipose flap obtained from the bulbocavernosus muscle. Blood supply is provided by pudendal artery branches. MF is a safely procedure which offers good cosmetic and functional results improving wound healing through neovascularization. Before surgery, a protective ileostomy is usually required.

Methodology Case presentation: a 72-year-old woman with squamous cervical cancer, IIB FIGO stage, was treated by exclusive chemo-radiation at our department. After three years of negative follow-up, the patient was hospitalized for fecal vaginal discharge. Gynecological examination showed an RVF between the lower one-third of the posterior vaginal wall and rectum. Colonoscopy confirmed the presence of an RVF of 2–3 mm diameter. Previous conservative treatments were ineffective. Therefore, after ileostomy, surgical treatment through a Martius flap was attempted. Surgical steps: 1) Laterolabial skin incision. 2) Labial dissection to identify the muscle- adipose flap 3) Mobilization of the flap. 4) Opening of the lateral vaginal tunnel. 5) Clamping of the superior pedicle. 6) Transfer of MF to the vagina. 7) Suture of MF over the vaginal surgical site. 8) Suture of the subcutaneous layer and skin. Amoxicillin, clavulanic acid, and metronidazole were administered 30 min before and continued seven days after surgery.

Results Postoperative course was uncomplicated: After 6 months follow-up, no recurrence of RVF was observed. The patient reported a great improved quality of life.

Conclusion The MF is an effective and safe procedure for RVF repair.

2022-RA-878-ESGO

ROBOTIC-ASSISTED VERSUS VAGINAL RADICAL TRACHELECTOMY IN PATIENTS WITH CERVICAL CANCER RADICALITY, RECURRENCE-FREE SURVIVAL AND CANCER-SPECIFIC MORTALITY

Sinor Soltanizadeh, Signe Frahm Bjørn, Ligita Paskeviciute Frøding, Berit Jul Mosgaard, Claus Høgdall. *Gynaecological Department, Rigshospitalet, Copenhagen, Denmark*

10.1136/ijgc-2022-ESGO.66

Introduction/Background Radical vaginal trachelectomy (RVT) is an alternative curative-intended fertility preserving procedure for women with a fertility desire and cervical cancer FIGO 2009 stage IA2 and IB1 with a tumor size ≤ 2 cm. In Denmark RVT was introduced and centralised to Rigshospitalet in 2003, and data from all patients undergoing trachelectomy has been prospectively reported to The Danish Gynaecological Cancer Database (DGCD). In 2014, the procedure advanced to a robotic-assisted approach (RRT). In this study, we present the largest single-center cohort to date of patients undergoing RRT versus RVT, evaluating surgical radicality, length of recurrence-free survival and cancer-specific mortality.