

2022-RA-681-ESGO

POU2F3 DRIVEN SUBSET OF SMALL CELL CARCINOMA EXISTS IN THE UTERINE CERVIX

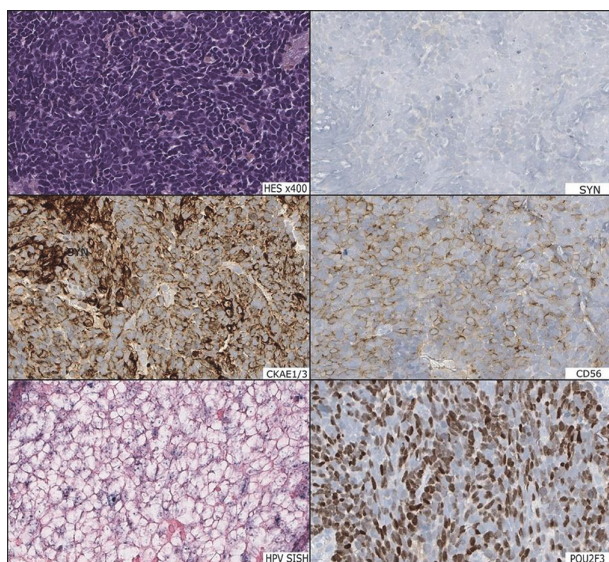
¹Vincent Cockenpot, ²Melodie Carbonnaux, ¹Daniel Pissaloux, ¹Sylvie Lantuejoul. ¹Pathology, Centre Léon Bérard, LYON, France; ²Oncology, Centre Léon Bérard, LYON, France

10.1136/ijgc-2022-ESGO.46

Introduction/Background So-called tuft cell variant of small cell carcinoma is now a well-established subset of small cell carcinomas of the lung, driven by POU2F3 transcriptomic factor, and characterized by low or no expression of neuroendocrine markers.

Methodology We report here the case of a POU2F3 driven subset of small cell carcinoma of the uterine cervix, in a woman in her early 40s. This HPV-dependent carcinoma was clinically considered as primary. Immunohistochemistry and RNA-sequencing with expression and clustering analyses were performed.

Results The biopsy showed typical morphological features of small cell carcinoma. Immunohistochemistry showed no neuroendocrine markers (chromogranin A, synaptophysin) expression, but a clear POU2F3 nuclear expression, similar to that of the tuft cell variant of lung small cell carcinoma. Clustering analysis of expression data obtained by RNA-sequencing revealed an expression profile similar to that of POU2F3 driven small cell lung carcinomas.



Abstract 2022-RA-681-ESGO Figure 1

Conclusion This variant has never been reported in uterine cervix and is worth recognizing since these tumours are usually negative for neuro-endocrine markers, and thus present a diagnostic challenge. If small cell carcinoma is first and foremost a morphological diagnosis, the use of POU2F3 immunohistochemistry as a novel diagnostic marker for these tumours with negative or low expression of neuro-endocrine markers could be helpful in clinical practice, especially on small cervix samples.

2022-RA-692-ESGO

EARLY STAGE CERVICAL CANCER: IS RADIAL MARGIN AN IMPORTANT RISK FACTOR FOR RECURRENCE?

¹Inês Azevedo Mendes, ²Andreia Relva, ²Margarida Bernardino, ²Ana Francisca Jorge. ¹Hospital Cascais, Alcabideche, Portugal; ²Instituto Português de Oncologia, Lisboa, Portugal

10.1136/ijgc-2022-ESGO.47

Introduction/Background The radial margin is the circumferential resection margin of a surgical specimen. The use of the margin is unclear in cervical cancer. The objective of this study is to assess whether the radial margin is a risk factor for recurrence.

Methodology Retrospective analysis of women with cervical cancer IB1, IB2 and IIA1 stages submitted to laparotomic radical hysterectomy with bilateral pelvic lymphadenectomy between 2005 -2015, in one single tertiary center (n= 417). The inclusion criterion was surgical specimen with invasive carcinoma and free surgical margins. For data analysis, SPSS[®] was used. The recurrence was evaluated. The radial margin as a continuous variable was evaluated by T-test and as a categorical variable by Fisher's exact test (two tailed) using 2 sub-groups (< 5 mm; ≥ 5 mm).

Results As continuous analysis the size of radial margin was smaller in women who had another criteria for adjuvant therapy (mean 2.83 mm vs 7.83 mm p< 0.05). In the group without adjuvant therapy (n=127), the dimension of radial margin between women with recurrence (n=12 mean 9.92 mm) and without recurrence (n=115, mean 7.81) was similar (p= 0.55). In the group with adjuvant therapy (n=155), the dimension of radial margin between women with recurrence (n=21, mean 2.43 mm) and without recurrence (n=134, mean 2.93) was similar (p= 0.59). As a categorical variable (n= 287), incidence of recurrence was also similar between women with radial margin < 5 mm (n = 167, 19 with recurrence vs 148 without recurrence) and radial margin ≥ 5 mm (n =120, 16 with recurrence vs 104 without recurrence) (p= 0.62).

Conclusion In our group of patients, women with short radial margin didn't have a different prognosis. Radial margin doesn't seem to be an indication for adjuvant therapy.

2022-RA-693-ESGO

CERVICAL CANCER: THE EFFECT OF CONE BIOPSY IN SURGICAL SPECIMEN AFTER RADICAL HYSTERECTOMY

¹Inês Azevedo Mendes, ²Andreia Relva, ²Margarida Bernardino, ²Ana Francisca Jorge. ¹Hospital Cascais, Alcabideche, Portugal; ²Instituto Português de Oncologia, Lisboa, Portugal

10.1136/ijgc-2022-ESGO.48

Introduction/Background Cone biopsy is sometimes performed before surgical treatment for early stage cervical cancer disease. The purpose of this work is to evaluate if cone biopsy modifies the characteristics of the tumor in the final surgical specimen and influences the decision for adjuvant radiotherapy. The final outcome evaluated will be the tumors' recurrence.

Methodology Retrospective Analysis of 417 cases of early stage cervical cancer disease, treated in one tertiary center between 2005–2015. Data was assorted in 2 subgroups: Group 1 – women with diagnosis made by cone biopsy (n=179); Group 2 – women with diagnosis made by biopsy (n = 232) . SPSS was used for data analysis. The differences between tumor size and proportion of cervical invasion were evaluated by student's T test. Fisher's exact test (two tailed) was used for evaluating the other tumors parameters and the proportion of women who underwent adjuvant therapy and disease recurrence.

Results After cone biopsy, tumor size present at surgical specimen is smaller, (mean 26 vs 19 mm, $p < 0.001$), but the proportion of cervical stromal invasion was similar between groups (mean 0.66 vs 0.56 $p=0.58$). Less women underwent adjuvant therapy in group with diagnosis made by cone biopsy (23% vs 52% $p < 0.001$). Disease recurrence was similar between the two groups evaluated separately for women who underwent adjuvant therapy (n=41, women with cone biopsy 7.3% vs women without cone biopsy 17%, $p=0.2$) or just vigilance (n= 137, women with cone biopsy 4.4% vs women without cone biopsy 8.5%, $p=0.19$).

Conclusion Women that performed cone biopsy underwent adjuvant therapy less frequently, without increasing the recurrence rate – Cone biopsy seems to be protective.

2022-VA-699-ESGO

DIAGNOSIS OF LYMPH NODE MICROMETASTASIS EVEN THOUGH METHYLENE BLUE

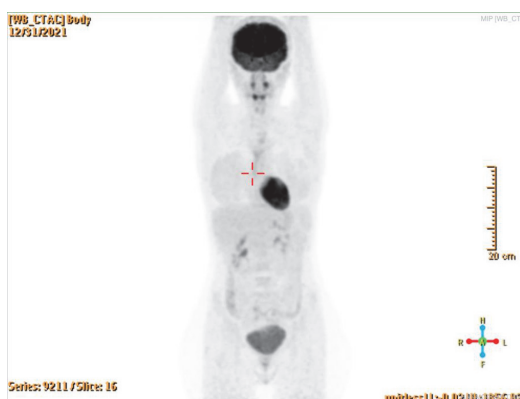Nazli Aylin Vural, Merve Aldikactioglu Talmac, Nilufer Cetinkaya Kocadal. *Gynecological Oncology, Basaksehir Cam and Sakura State Hospital, Istanbul, Turkey*

10.1136/ijgc-2022-ESGO.49

Introduction/Background The subsequent complications of pelvic-lymphadenectomy in patients with early-stage cervical-cancer, the sentinel-lymph-node (SLN) technique is increasingly used. Studies show that SLN-technique with methylene-blue alone is viable and adequate alternative to systematic-lymphadenectomy for early stage cervical cancer in selected patients.

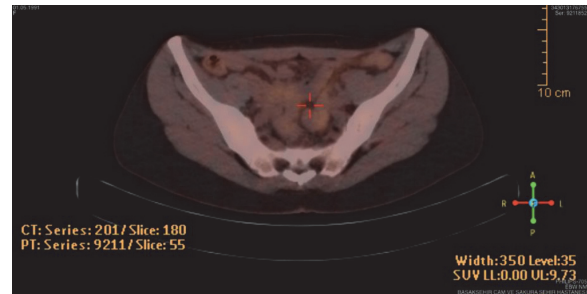
Methodology

Case Presentation A 30-years old patient who was diagnosed with cervical squamous cell carcinoma with a size of 2,1 cm, had no suspicious lymph node in the preoperative PET/CT and MRI scans. Thereupon, a fertility-sparing-trachelectomy operation was planned.



Abstract 2022-VA-699-ESGO Figure 1

Results Sentinel-lymph-node evaluation and frozen-section were performed. Afterward micrometastases were detected during the frozen examination, the operation was terminated. *Patient had no abnormal symptoms throughout early postoperative period. On the 3rd day after primary surgery patient was discharge without any further complication. After all pathology examination, the patient was accepted as FIGO2018 Stage 3C1 and referred to chemoradiotherapy.*



Abstract 2022-VA-699-ESGO Figure 2

Conclusion Many published studies show the feasibility of SLNB for cervical-cancer. The latest edition of the National-Comprehensive-Cancer-Network (NCCN) Practice Guide says sentinel lymph node dissection can only be used in stage I patients and patients with tumor size < 4 cm, but is best for tumor < 2 cm. There is ample evidence that SLN without systematic lymph node resection has the same oncology outcomes and fewer complications. According to Yahta et al. investigated surgical complications and prognostic outcomes in patients with early stage cervical-cancer who underwent SLN for trachelectomy or hysterectomy found that operative-time, lymphedema, lymphangitis, and blood-loss were significantly lower in patients with SLN compared to patients who underwent systemic pelvic lymphadenectomy, and the prognostic outcomes were not different between the two groups. In developing-countries, all necessary dyes for sentinel-lymph-nodes are not available in all centers. Our case is very significant in terms of showing that sentinel-lymph-node can be detected and metastasis can be detected with methylene-blue alone, with right technique and surgical management.

2022-RA-711-ESGO

ASSOCIATION OF PET-CT TUMOR METABOLIC METRICS AND INTRAEPITHELIAL AND STROMAL TUMOR- INFILTRATING LYMPHOCYTES IN LOCALLY ADVANCED CERVICAL CANCER PRIOR TO CONCURRENT CHEMO-RADIOTHERAPY

¹Alejandra Martinez, ¹Mathilde Del, ²Claire Ilac, ¹Martina Aida Angeles, ³Anne Ducassou, ⁴Sarah Bétrian, ²Guillaume Bataillon, ¹Gwénaél Ferron, ¹Stéphanie Motton, ⁵Amélie Lusque, ⁶Erwan Gabiache. ¹Department of Surgical Oncology, Institut Universitaire du Cancer de Toulouse – Oncopole, Toulouse, France; ²Department of Anatomopathology, Institut Universitaire du Cancer de Toulouse – Oncopole, Toulouse, France; ³Department of Radiotherapy, Institut Universitaire du Cancer de Toulouse – Oncopole, Toulouse, France; ⁴Department of Oncology, Institut Universitaire du Cancer de Toulouse – Oncopole, Toulouse, France; ⁵Biostatistics Unit, Institut Universitaire du Cancer de Toulouse – Oncopole, Toulouse, France; ⁶Department of Nuclear Medicine, Institut Universitaire du Cancer de Toulouse – Oncopole, Toulouse, France

10.1136/ijgc-2022-ESGO.50