

2022-RA-638-ESGO

PEMBROLIZUMAB WITH MULTIMODAL IMMUNOMODULATION IN CHEMOTHERAPY-PRETREATED CERVICAL, ENDOMETRIAL, AND UTERINE CANCER: THE PRIMMO PHASE II TRIAL

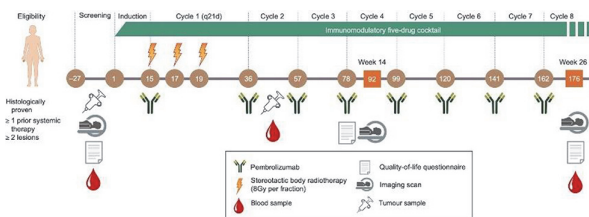
¹Emiel A De Jaeghere, ²Sandra Tuyaeys, ³An MT van Nuffel, ⁴Ann Belmans, ⁴Kris Bogaerts, ⁵Regina Baiden-Amissah, ⁶Peter Vuylsteke, ⁶Stéphanie Henry, ⁷Xuan Bich Trinh, ⁷Peter A van Dam, ²Sandrine Aspeslagh, ⁸Alex de Caluwé, ¹Eline Naert, ⁹Diether Lambrechts, ¹⁰An Hendrix, ¹⁰Olivier de Wever, ¹¹Koen K van de Vijver, ¹²Frédéric Amant, ¹³Katrien Vandecasteele, ¹Hannelore G Denys. ¹Medical Oncology, Ghent University Hospital, Ghent, Belgium; ²Medical Oncology, University Hospital Brussels, Brussels, Belgium; ³Anticancer Fund, Strombeek-Bever, Belgium; ⁴Biostatistics and Statistical Bioinformatics Centre (L-BioStat), KU Leuven, Leuven, Belgium; ⁵Leuven Cancer Institute, Leuven, Belgium; ⁶Department of Hemato-Oncology, Centre Hospitalier Universitaire Université Catholique de Louvain Namur (Sainte-Elisabeth), Namur, Belgium; ⁷Department of Gynecologic Oncology and Senology, University Hospital Antwerp, Edegem, Belgium; ⁸Department of Radiation Oncology, Jules Bordet Institute, Brussels, Belgium; ⁹VIB-KU Leuven Center for Cancer Biology, Leuven, Belgium; ¹⁰Laboratory for Experimental Cancer Research, Ghent University, Ghent, Belgium; ¹¹Department of Pathology, Ghent University Hospital, Ghent, Belgium; ¹²Center for Gynecologic Oncology Amsterdam (CGOA), Netherlands Cancer Institute and Amsterdam Medical Center, Amsterdam, Netherlands; ¹³Department of Radiation Oncology, Ghent University Hospital, Ghent, Belgium

10.1136/ijgc-2022-ESGO.401

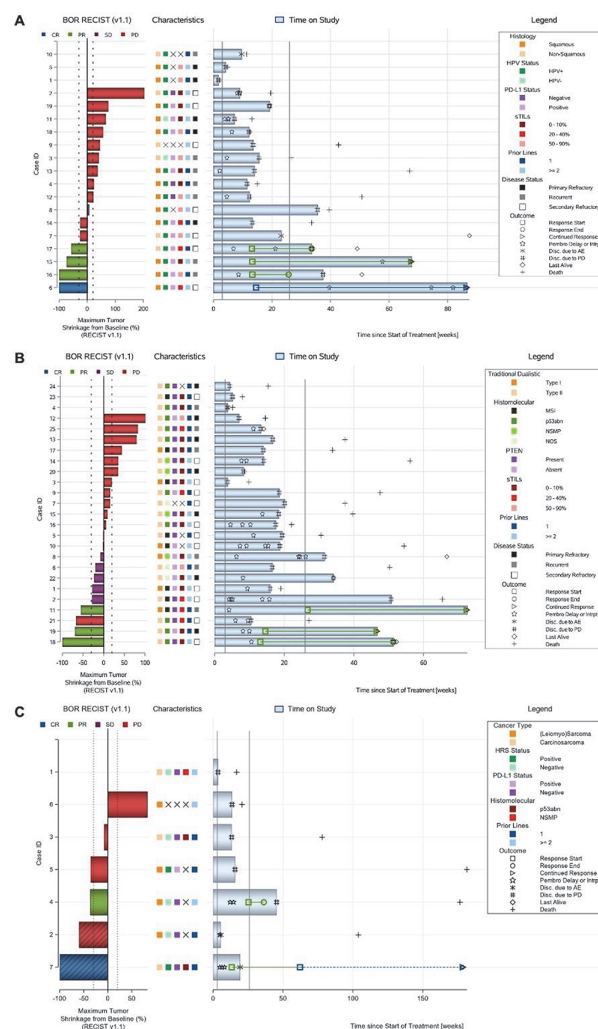
Introduction/Background To decrease immunosuppression and enhance T-cell activation in the tumour microenvironment, we conducted an open-label, investigator-initiated, multicohort, phase II trial (NCT03192059) of pembrolizumab with multimodal immunomodulation.

Methodology Chemotherapy-pretreated patients were recruited into two experimental cohorts (cervical carcinoma or endometrial carcinoma) and one exploratory cohort (uterine sarcoma). Patients received an immunomodulatory five-drug cocktail consisting of low-dose cyclophosphamide, aspirin, lansoprazole, vitamin D, and curcumin starting two weeks before radioimmunotherapy (figure 1). Pembrolizumab, 200 mg/dose, was administered on day 1 of each 21-day cycle from day 15 onwards; one of the tumour lesions was irradiated (8Gyx3) on days 15, 17, and 19. The primary endpoint was objective response rate (irORR) per immune-related response criteria (irRC) at week 26; a lower bound of its 90% confidence interval (CI) of >10% in either experimental cohort was considered successful.

Results Fifty patients were enrolled and treated across the cohorts (cervical, n=18; endometrial, n=25; sarcoma=7). Pathology review revealed that 3/7 sarcoma patients had carcinosarcoma. At week 26, the irORR was 11.1% (90%CI, 2.0 to 31.0) in cervical cancer, 12.0% (90%CI, 3.4 to 28.2) in endometrial cancer, and 14.3% (90% CI, 0.7 to 52.1) in uterine (carcino)sarcoma. The best overall response rate per RECIST v1.1 was 22.2% (90%CI, 8.0 to 43.9), 12.0% (90% CI, 3.4 to 28.2), and 28.6 (90%CI, 5.3 to 65.9). Median PFS was 13.4 weeks (11.3 to 26.1), 13.1 weeks (13.1 to 19.4), and 34.3 weeks (95%CI, 5.6 to 77.9) (figure 2A-C). Grade ≥3 treatment-related adverse events were reported in 10 (55.6%), 9 (36.0%), and 4 (57.1%) patients. Overall, there was one (2.0%) possible treatment-related death. Health-related quality of life was generally stable over time. Multi-parameter immune monitoring characterised the patients and revealed changes throughout study treatment.



Abstract 2022-RA-638-ESGO Figure 1



Combined waterfall and swimmer plot of the (A) cervical cohort, (B) endometrial cohort, and (C) (carcino) sarcoma cohort. Each row (i.e., response bar + characteristics + swimmer lane) corresponds to one patient. Waterfall plot showing best percentage change from baseline in the sum of diameters of the target lesions; best overall response is indicated by color coding of bars and includes assessment of target, nontarget, and new lesions. The dotted lines at -30% and +20% indicate thresholds for partial response and progressive disease (PD), respectively, per Response Evaluation Criteria in Solid Tumors, version 1.1 (RECIST v1.1). Swimmer plot (event chart) for tumor response (response category indicated by color coding), progressive disease per RECIST v1.1, safety, time on study, and death. The solid lines at week 3 and week 26 indicate the first pembrolizumab dose and the timing of the primary endpoint, respectively.

Abstract 2022-RA-638-ESGO Figure 2 Combined waterfall and swimmer plot of the (A) cervical cohort, (B) endometrial cohort, and (C) (carcino) sarcoma cohort. Each row (i.e., response bar + characteristics + swimmer lane) corresponds to one patient. Waterfall plot showing best percentage change from baseline in the sum of diameters of the target lesions best overall response is indicated by color coding of bars and includes assessment of target, nontarget, and new lesions. The dotted lines at -30% and +20% indicate thresholds for partial Response Evaluation Criteria in Solid Tumors, version 1.1 (RECIST v1.1). Swimmer plot (event chart) for tumor response (response category indicated by color coding), progressive disease per RECIST v1.1, safety, time on study, and death. The solid lines at week 3 and week 26 indicate the first pembrolizumab dose and timing of the primary endpoint, respectively.

Conclusion PRIMMO did not show sufficient evidence of a positive risk-to-benefit ratio to recommend a confirmatory phase III trial.

2022-RA-663-ESGO

THE IMPACT OF COVID-19 ON GYNAECOLOGICAL ONCOLOGY SURGERY

Febia Erliandi, Ali Budi Harsono, Siti Salima. *Obstetrics and Gynecology, Faculty of Medicine Universitas Padjadjaran – Dr. Hasan Sadikin Hospital, Bandung, Indonesia*

10.1136/ijgc-2022-ESGO.402

Introduction/Background COVID-19 pandemic affects all fields, including gynaecology surgery, as 19% of deaths correlate with surgeries. This study aims to examine the effect of COVID-19 pandemic on gynaecological oncology surgery at Dr. Hasan Sadikin Hospital, Bandung, Indonesia.

Methodology This study was a retrospective analysis on elective gynaecological oncology surgeries at Dr. Hasan Sadikin Hospital from January 2020 – December 2021. Surgery delays due to COVID-19 was analysed based on parameters such as age, comorbidities, COVID-19 status, Cycle of Threshold (CT)-value, outcome, and interval from initial schedule to actual surgery execution.

Results The highest number of surgery cancellations occurred in May to August 2021. Out of the 42 gynaecology surgeries cancelled due to COVID-19, 21 of them (50%) were gynaecological oncology patients with mean age of 44.7 ± 15.1 years. Two patients (9.5%) had suspected case of COVID-19, while 19 patients (90.5%) had confirmed case of COVID-19. Fifteen out of 21 patients (71.4%) had comorbidities. Confirmed COVID-19 patients with comorbidities had lower mean CT value compared to those without comorbidities (32.19 ± 7.38 Vs 37.02 ± 1.26). There were 14 (66.7%) gynaecological oncology patients who underwent surgery after recovering from COVID-19, five (23.8%) who did not come back for follow-up, and two (9.5%) who died. Patients who died both had comorbidities with CT values of 28 and 16, respectively. Patients with comorbidities had longer duration of surgery rescheduling compared to those without comorbidities (118.5 ± 96.60 Vs 9.5 ± 6.36).

Conclusion In 2021, there were more elective gynaecological oncology surgeries scheduled and cancelled due to COVID-19 compared to 2020. COVID-19 patients with comorbidities tended to have lower CT values and longer surgery rescheduling. Mortality occurs only in comorbid patients. Education and counselling regarding risk of surgery delays compared to risk of increasing peri-operative mortality and morbidity due to COVID-19 need to be delivered.

2022-RA-705-ESGO

OVARIAN LEYDIG CELL TUMOR: CAUSE OF VIRILIZATION IN A POSTMENOPAUSAL WOMAN

¹Mariam Garci, ²Siham Bouzidi, ²Sawssem Armi, ²Cyrine Belghith, ²Olfa Slimani, ²Nabil Mathlouthi. ¹Charels nicolle Hospital, Tunis, Tunisia; ²Charles nicolle Hospital, Tunis, Tunisia

10.1136/ijgc-2022-ESGO.403

Introduction/Background Sertoli-Leydig tumors are hormone-secreting tumors, which belong to the group of stromal tumors and sex cords; they are very rare, it accounts for less

than 0.2% of all ovarian tumors; they are most often responsible for virilization syndrome.

Methodology we report the case of a 57-year-old woman who presented with postmenopausal virilism for 2 years revealing a well-differentiated Sertoli-Leydig cell tumor of the ovary.

Results A 57-year-old patient, with a history of type 2 diabetes, arterial hypertension, hypothyroidism. The history of the disease was marked by the progressive installation of signs of virilization (hirsutism, hoarseness, hypertrichosis, hair loss). a high level of testosterone was found. The scanner showed a hypodense formation at the level of the right ovary of 24 mm. The patient was discharged under cyproterone acetate, with clinical and biological monitoring. Four years later, she was rehospitalized in the face of the persistence of signs of virilism. She presented an abnormal hair distribution (severe hirsutism with Ferriman and Gallway SCORE over 25). Gynecological examination showed an enlarged clitoris, atrophy of the vaginal mucosa, the cervix was healthy. The intravaginal ultrasound was without abnormality. The patient underwent laparoscopic surgery. Intraoperatively, the ovaries were small, without mass, the uterus and fallopian tubes were without abnormality, there was no peritoneal carcinomatosis. A bilateral adnexectomy was performed. Clinical improvement of the signs of virilization was noticed 3 weeks later. The histological examination of the specimen revealed a hilar Leydig cell tumor that measured 8 mm in its largest axis

Conclusion stromal tumor and sex cords are very rare, sertoli-leydig cell tumors are the most. The differentiated forms have a low potential for malignancy, the treatment is surgical, the prognosis after surgery is good.

2022-RA-720-ESGO

ENDOMETRIAL STROMAL NODULE: A RARE ENTITY. REPORT OT 2 CASES

¹Amina Lubrano Rosales, ¹Elena Perez Morales, ²Francisco Granados Pacheco, ²Laureano Leon Arencibia, ²Arancha Ruiz del Pozo Lodo, ¹Elena Cortes Cros. ¹Gynecology, Complejo Hospitalario Universitario MaternoInfantil de Canarias, Las Palmas de G.C., Spain; ²Pathology, Complejo Hospitalario Universitario MaternoInfantil de Canarias, Las Palmas de G.C., Spain

10.1136/ijgc-2022-ESGO.404

Introduction/Background Endometrial stromal tumors are classified according to their histological characteristics as Endometrial Stromal Nodule (ESN), Low-grade Endometrial Stromal Sarcoma (LGESS), High-grade Endometrial Stromal Sarcoma (HGESS) and Undifferentiated Uterine Sarcoma (UUS). ESN is a rare neoplasm cytologically similar to low-grade endometrial stromal sarcoma, but it is distinguished by its non-invasive capacity and is considered a benign lesion.

Methodology We describe two cases of women with endometrial stromal nodules who underwent total abdominal hysterectomy. The patients were 49 and 54 years old, respectively, and presented with abnormal menstrual bleeding.

Results Histopathologically, several rounded tumors with a myomatous appearance were identified, the largest being 7 x 5 cm, and a 2 cm vascularized lesion with cellular tabs reminiscent of the endometrial stroma without lymphovascular invasion or mitosis. The morphological and immunohistochemical findings are compatible with an endometrial stromal nodule. Low cell proliferation (4 mitoses/10 high power fields