

and less expensive. Nevertheless, based on a 25% and 15% rate of false positivity and negativity respectively, consideration should be given to confirm MSI IHC status for all patients by molecular analyses.

### 2022-VA-979-ESGO TOTAL EXCISION OF INFRARENAL VENA CAVA IN A PATIENT WITH RECURRENT ENDOMETRIAL CANCER

<sup>1</sup>Dogan Vatansver, <sup>1</sup>Emin Erhan Donmez, <sup>1</sup>Burak Giray, <sup>2</sup>Atif Akçevin, <sup>1</sup>Macit Arvas, <sup>1</sup>Cagatay Taskiran. <sup>1</sup>Gynecologic Oncology, Koc University Hospital, Istanbul, Turkey; <sup>2</sup>Cardiovascular Surgery, Koc University Hospital, Istanbul, Turkey

10.1136/ijgc-2022-ESGO.267

**Introduction/Background** Endometrial cancer is one of the common malignant tumors of the female reproductive system. The recurrence and 5-year overall survival rates of patients with FIGO I-II are 2–15 and 74–91%, respectively. Secondary cytoreductive surgery is associated with improved overall survival in patients with recurrent disease. This video aims to present metastasectomy along with the infrarenal vena cava in a patient with recurrent ovarian cancer.

**Methodology** A 68-year-old woman was admitted with a gross abdominal mass. She has been diagnosed with stage 1, grade 1 endometrial cancer, and underwent a primary staging surgery 2 years ago. The magnetic resonance imaging revealed a 43x39x49 mm abdominal mass involving vena cava inferior. Also, positron emission tomography scan showed a 45x47x50 mm metastatic lymph node extending to the aortocaval prevertebral area. Metastasectomy along with the infrarenal vena cava, resection of bulky paraaortic lymph nodes, partial resection of the duodenum, and duodenojejunostomy were performed as part of maximal secondary cytoreduction.

**Results** She stayed at the intensive care unit for one day and discharged without any grade 3 or 4 adverse event in post-operative period.

**Conclusion** Secondary cytoreduction for endometrial cancer with no residual disease is a major impact on survival, and maximal cytoreduction is necessary in selected cases. The management of this condition should be performed with expert multidisciplinary teams in gynecological oncology.

### 2022-RA-987-ESGO MOLECULAR CHARACTERIZATION OF ENDOMETRIAL CANCER WITH LOW VOLUME METASTASIS IN THE SENTINEL LYMPH NODE: A MULTICENTRIC INTERNATIONAL STUDY

<sup>1,2</sup>Gabriella Schivardi, <sup>1,3</sup>Giuseppe Cucinella, <sup>1</sup>Andrea Mariani, <sup>4</sup>Maryam Shahi, <sup>1</sup>Carrie Langstraat, <sup>5</sup>Amy Weaver, <sup>5</sup>Michaela Mc Gree, <sup>2</sup>Francesco Multinu, <sup>2</sup>Vanna Zanagnolo, <sup>2</sup>Ilaria Betella, <sup>6</sup>Glauco Baiocchi, <sup>6</sup>Louise de Brot, <sup>7</sup>Robert Giuntoli, <sup>7</sup>Spyridon Mastroyannis, <sup>1</sup>Gretchen Glaser. <sup>1</sup>Department of Obstetrics and Gynecology, Division of Gynecologic Surgery, Mayo clinic, Rochester, MN; <sup>2</sup>Department of Gynecology, European Institute of Oncology, IEO, IRCCS, Milan, Italy; <sup>3</sup>Department of Gynecologic Oncology, University of Palermo, Palermo, Italy; <sup>4</sup>Department of Pathology, Mayo clinic, Rochester, MN; <sup>5</sup>Department of Quantitative Health Sciences, Mayo clinic, Rochester, MN; <sup>6</sup>Department of Gynecologic Oncology, A.C. Camargo Cancer Center, Sao Paulo, Brazil; <sup>7</sup>Department of Obstetrics and Gynecology, Division of Gynecologic Oncology, University of Pennsylvania Health System, Philadelphia, PA

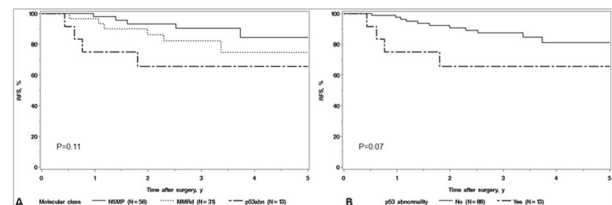
10.1136/ijgc-2022-ESGO.268

**Introduction/Background** The primary aims of this study were to assess the molecular characterization of endometrial cancer (EC) patients with low volume metastasis (LVM) in the sentinel lymph node (SLN) and to identify the molecular predictors of recurrence among those patients.

**Methodology** Patients with EC and LVM [isolated tumour cells (<0.2 mm) – micrometastasis ( $\geq 0.2 < 2$  mm)] who underwent surgery from August 2014 to November 2020 and had subsequent molecular characterization were identified among four referral centres worldwide. Patients with adnexal involvement and FIGO stage IV were excluded. The molecular analysis included immunohistochemistry for p53 and MMR proteins and Sanger sequencing for POLE exonuclease domain. ECs were classified into four molecular classes (POLEmut, MMRd, p53abn, and NSMP).

**Results** Among 101 patients, the molecular classification showed 56 NSMP, 31 MMRd, 13 p53Abn, and 1 POLEmut. Of 12 non-endometrioid cases, 11 were p53abn. Overall, 15 patients experienced a recurrence, and the median follow-up for the remaining patients was 3.1 (IQR, 2.0–3.8) years. The 3-year RFS was 90.4% (95% CI 95%, 81.8–99.9%), 82.1% (95% CI, 69.0–97.8%) and 65.6% (95% CI, 43.2%–99.7%), for the NSMP, MMRd, and p53Abn classes, respectively. No recurrence was observed in the POLEmut case. The overall RFS analysis between the three classes was comparable ( $p=0.11$ ), and the comparison between p53abn class and the other classes did not reach a significant difference ( $p=0.07$ ).

On univariate analysis, the presence of micrometastasis ( $p=0.02$ ), non-endometrioid histology ( $p=0.02$ ), lymphovascular space invasion ( $p=0.04$ ), and positive peritoneal cytology ( $p=0.005$ ) were significant predictors of recurrence.



**Abstract 2022-RA-987-ESGO Figure 1** (A) Recurrence-free survival according to molecular classes (NSMP, MMRd, p53abn). (B) Recurrence-free survival according to p53 status (p53abn vs. All other classes)

**Conclusion** Among EC patients SLN-LVM, there is a low rate of POLEmut tumours. Our results confirmed that traditional pathological features have a strong impact on prognosis among SLN-LVM patients. We did not observe significant impact of the molecular classes on the risk of recurrence, however further studies are needed.

### 2022-RA-988-ESGO CLINICAL OVER AND UNDER ESTIMATION IN PATIENTS WHO UNDERWENT HYSTERECTOMY FOR ATYPICAL ENDOMETRIAL HYPERPLASIA

<sup>1</sup>Funda Atalay, <sup>2</sup>Cemal Resat Atalay. <sup>1</sup>Gynecologic Oncology Surgery, Dr.AY Ankara Oncology Education and Research Hospital, Ankara, Turkey; <sup>2</sup>Gynecology and Obstetrics, Ankara City Hospital (Ankara Numune Educational And Research Hospital), ANKARA, Turkey

10.1136/ijgc-2022-ESGO.269